



Melanocytic & Non-melanocytic Mimics of Melanoma

Ibrahim Khalifeh, M.D.

Associate Professor

Department of Pathology

American University of Beirut Medical Center

Beirut, Lebanon

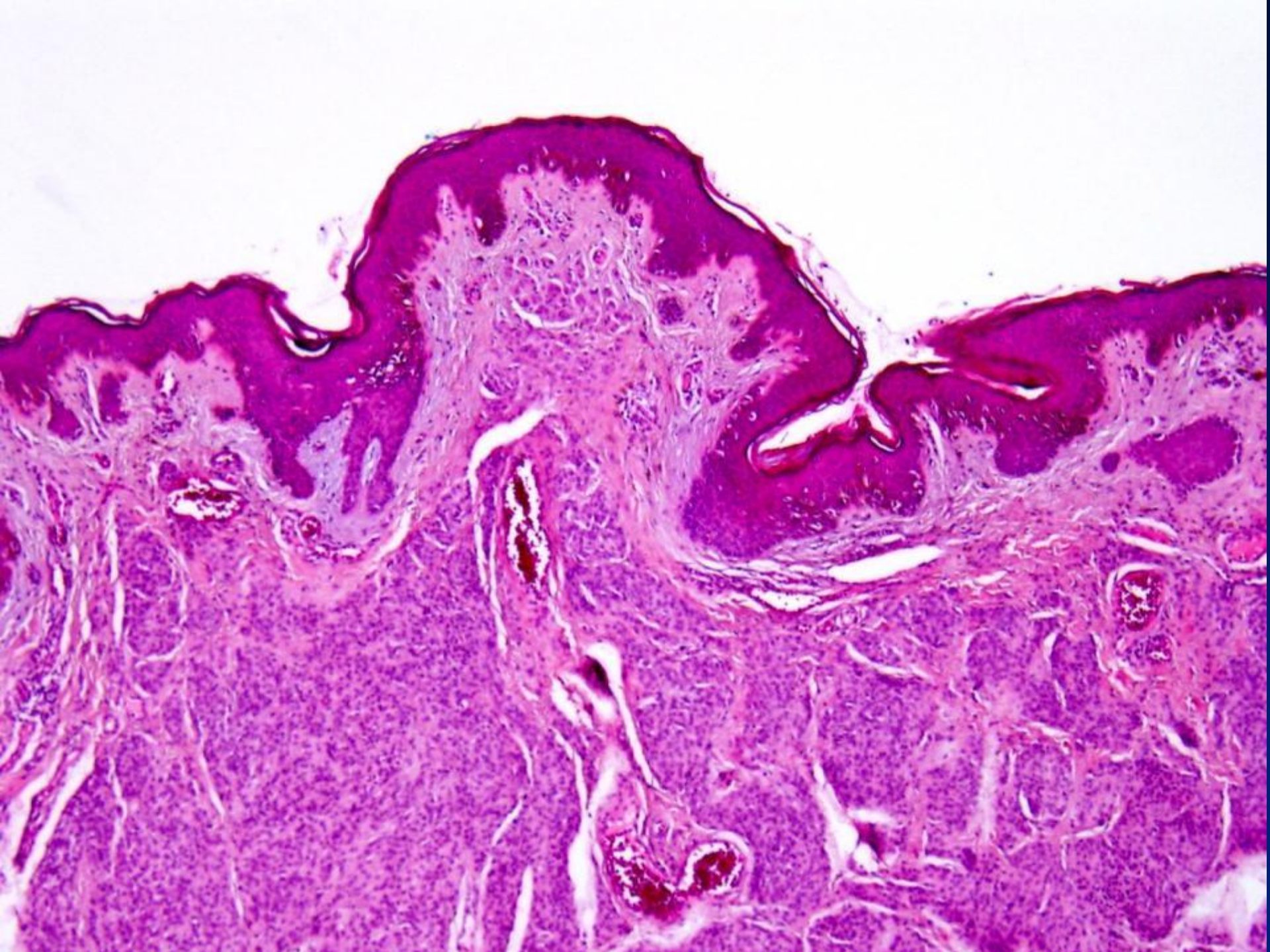
Case 1

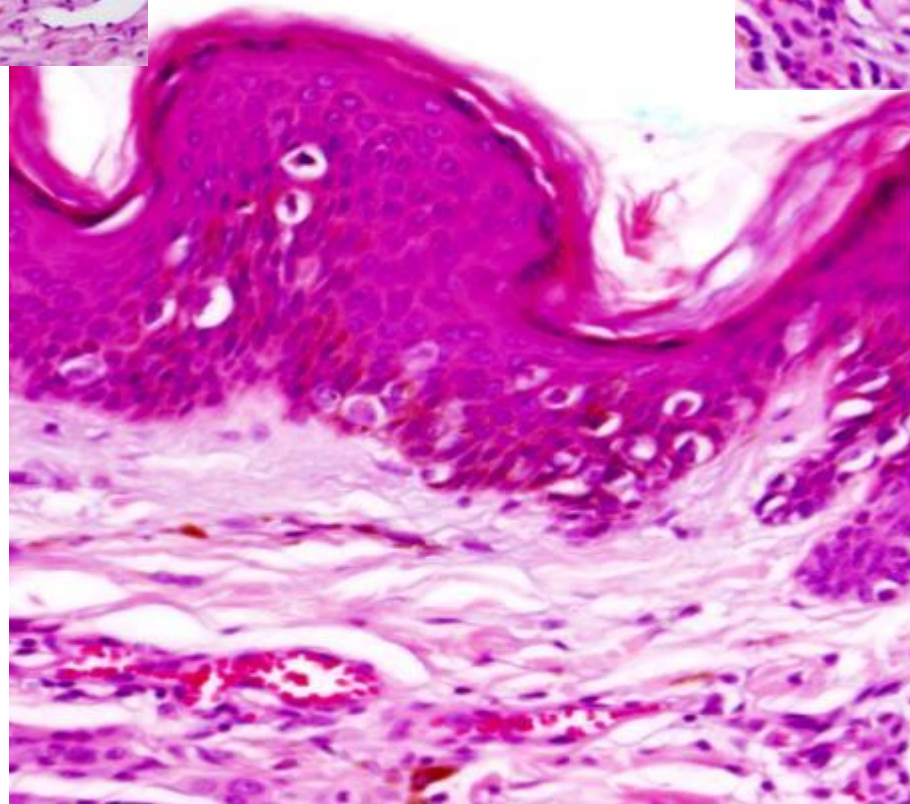
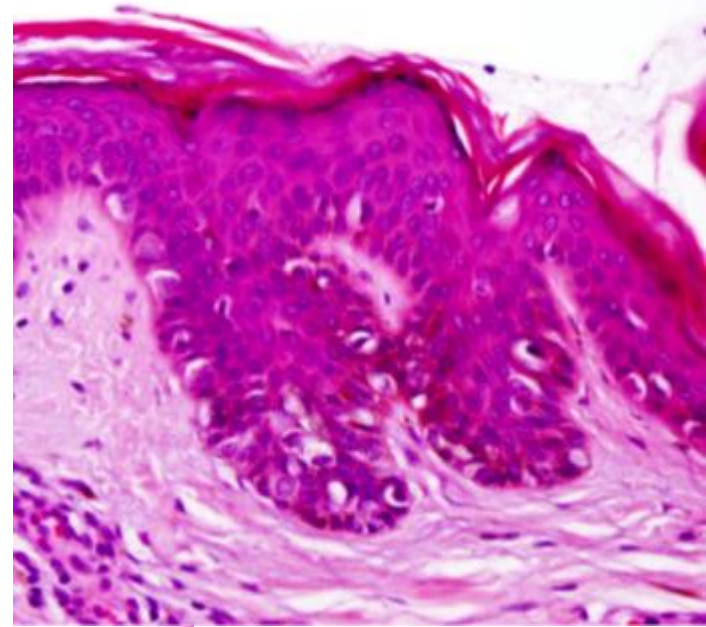
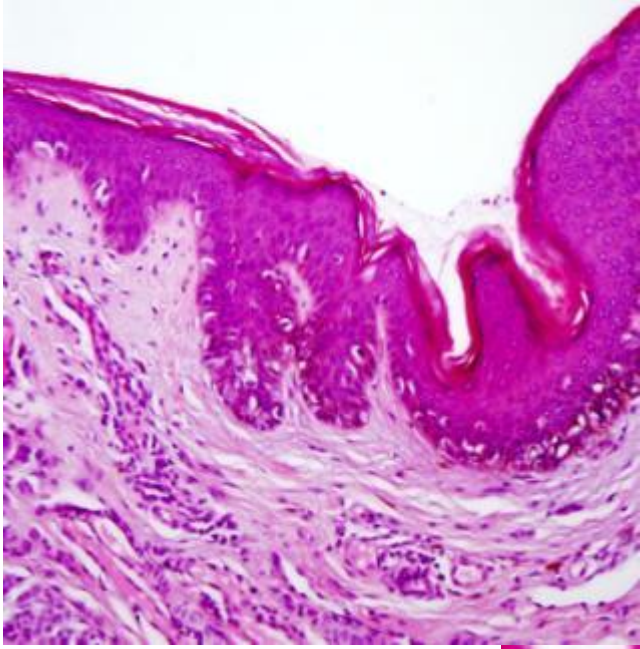
History

- **33-year-old with fleshy axillary nodule**

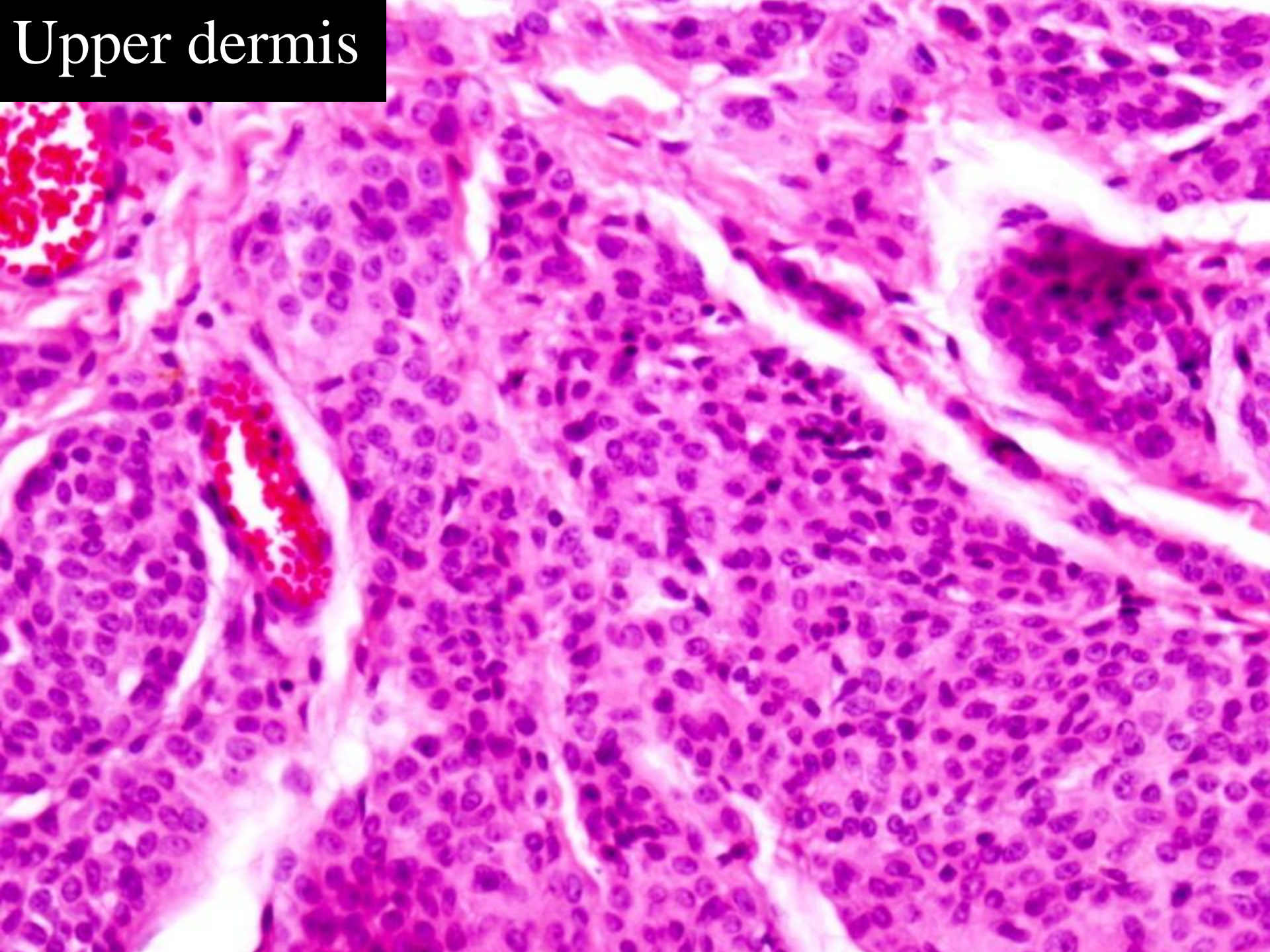
Gross Description

- **Ellipse of skin measuring 1.5 x 1.3 x 0.9 cm**
- **The surface of the specimen is raised and polypoid**

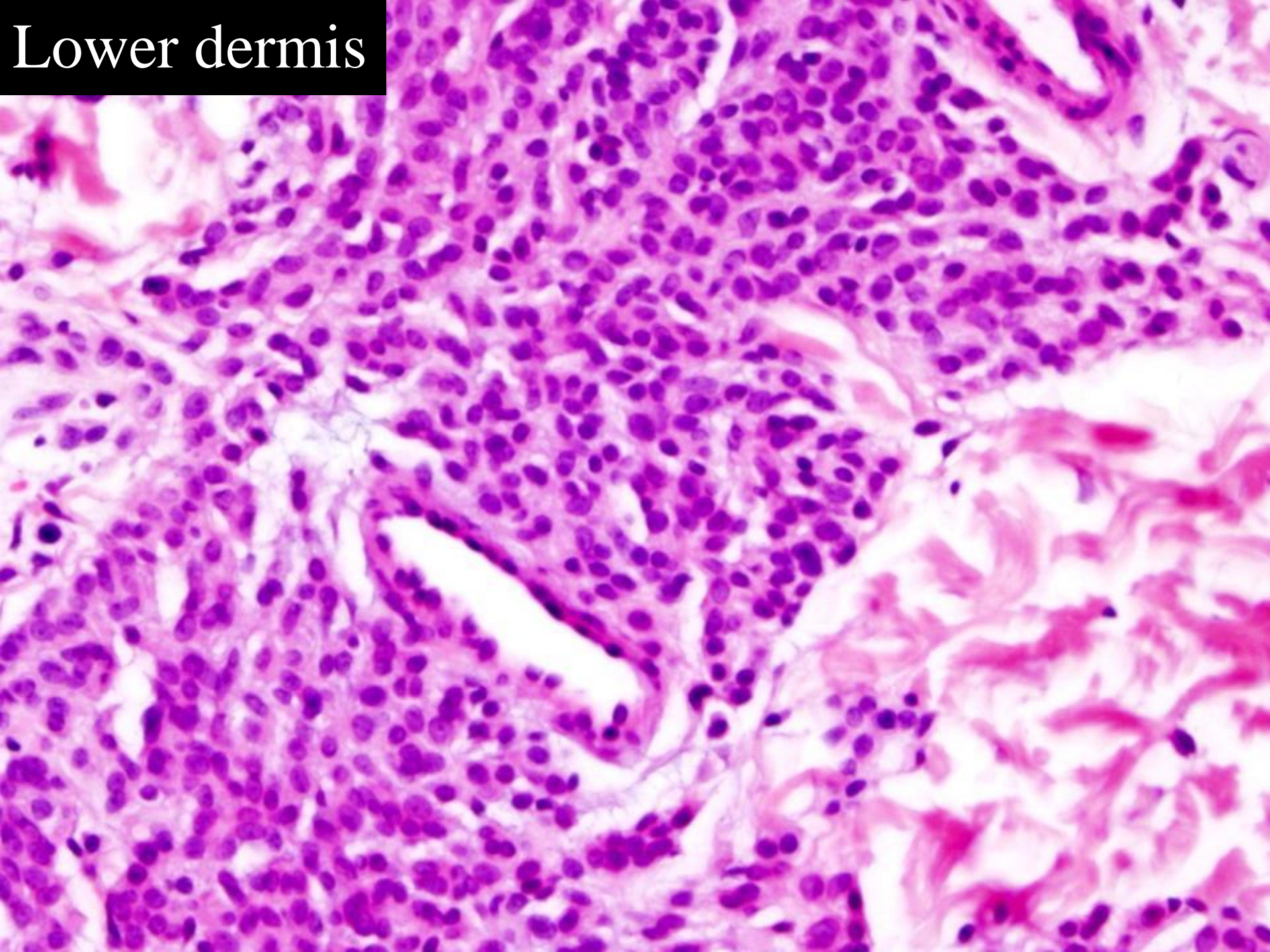




Upper dermis



Lower dermis



Microscopic Description

- Epidermis with increased melanocytes, some of which percolate upward in the epidermis
- Dermis with increased melanocytes, many of which are peri-adnexal

Your Diagnosis?

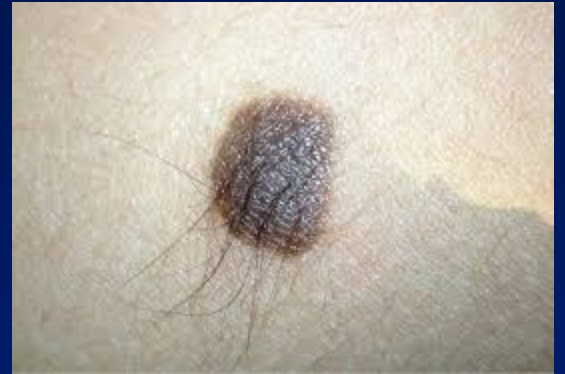- A. Congenital Melanocytic Nevus**
- B. Severely Dysplastic Nevus**
- C. Spitz Nevus**
- D. Epidermotropic Metastatic Melanoma**
- E. Nevus with Overlying Increased Epidermal Langerhans Cells**

Your Diagnosis?

- A. *Congenital Melanocytic Nevus*
- B. **Severely Dysplastic Nevus**
- C. **Spitz Nevus**
- D. **Epidermotropic Metastatic Melanoma**
- E. **Nevus with Overlying Increased Epidermal Langerhans Cells**

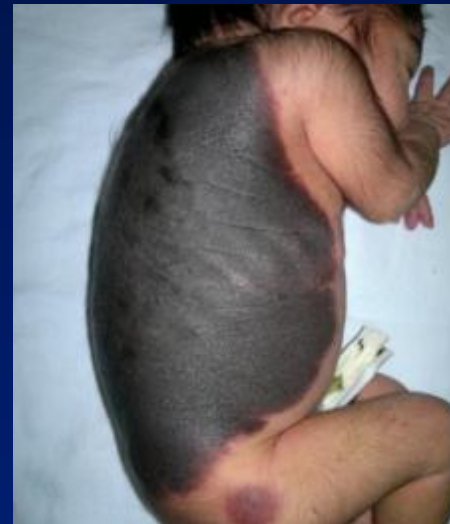Diagnosis

- **Congenital Melanocytic
Nevus**



Congenital Nevi

- 1% of newborn
- Trunk
- Most are 1-3 cm
- Giant CN > 20 cm
“bathing trunk”
distribution



Congenital Nevi

- Can enlarge/ulcerate in infants
- In adults don't change/enlarge/ulcerate (unless there's trauma, infection, folliculitis, malignancy)
- Associated with Carney's complex

Congenital Nevi

- **Risk of melanoma – in giant congenital nevi, 6%, predominantly axial**
- **In other congenital nevi, questionable risk**
- **Very rare incidence of congenital melanoma/prenatal metastases**

Congenital Nevi

- Deep extension
- Around collagen bundles, arrector pili muscle, adnexae
- Occasionally, a cellular nodule in CN: lack of circumscription, necrosis, atypical mitoses token malignancy.

Differential Diagnosis

- **Congenital nevus**
- **Dysplastic nevi**
- **Malignant melanoma**

Melanoma in CN

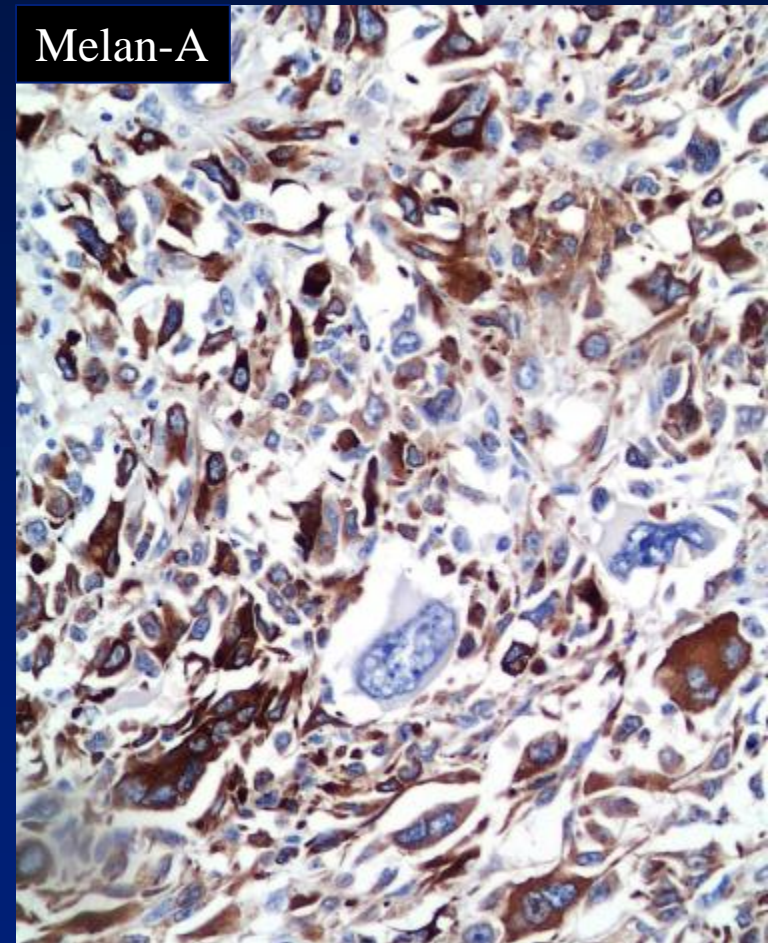
- How much atypia is **TOO MUCH?**
- Is there any **ANCILLARY TESTS** that can help?

IPOX in Dermatopathology: Special Situations

- 1. Diagnosis (melanocytic differentiation)**
- 2. Depth of invasion**
- 3. Distinction between benign/malignant:**
 - Nevus and nevoid melanoma**
 - Desmoplastic nevus vs. melanoma**
 - Blue nevus vs. spindle cell melanoma**
 - Scar vs. desmoplastic melanoma**
 - Melanoma vs. MPNST**
 - Sentinel lymph nodes**

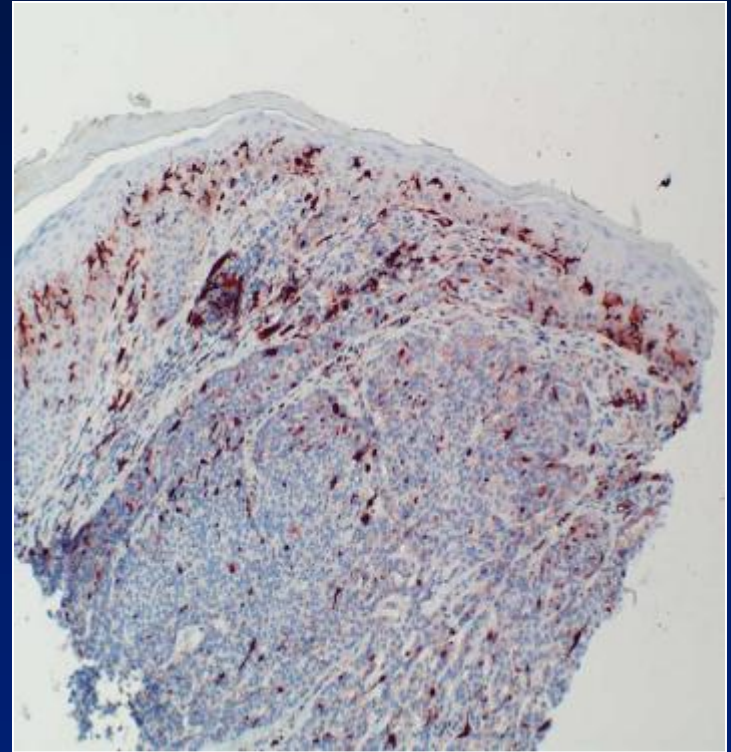
1. Detection of Melanocytic Differentiation

- Poorly differentiated lesions
- Pan-melanocytic cocktail (HMB45, anti-MART1, MelanA, anti-tyrosinase)
- Keratin
- SMA
- S100



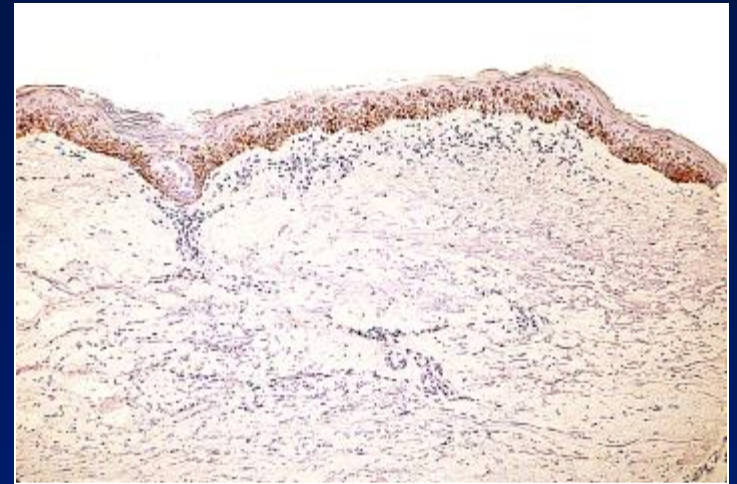
S100 PROTEIN

- Protein expressed in nuclei and cytoplasm
- Highest sensitivity (~100%)
- Little specificity (neural, epithelial, other lesions)
- Detection of melanocytic differentiation



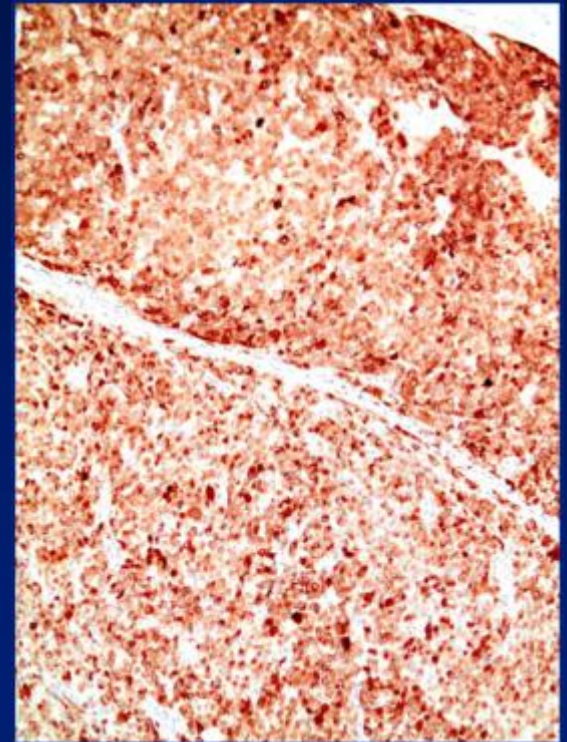
gp100 (HMB45)

- Premelanosomes
- Very specific (angioleiomyomas, sugar cell tumors)
- Less sensitive (70-90%).
- Detection of melanocytic differentiation
- Separation benign vs. malignant



MART1

- **Melanoma antigen recognized by T cells**
- **Very specific (95-100%)**
- **Very sensitive (75-95%)**
- **Detection of melanocytic differentiation**
- **Much less frequently in desmoplastic**



TYROSINASE

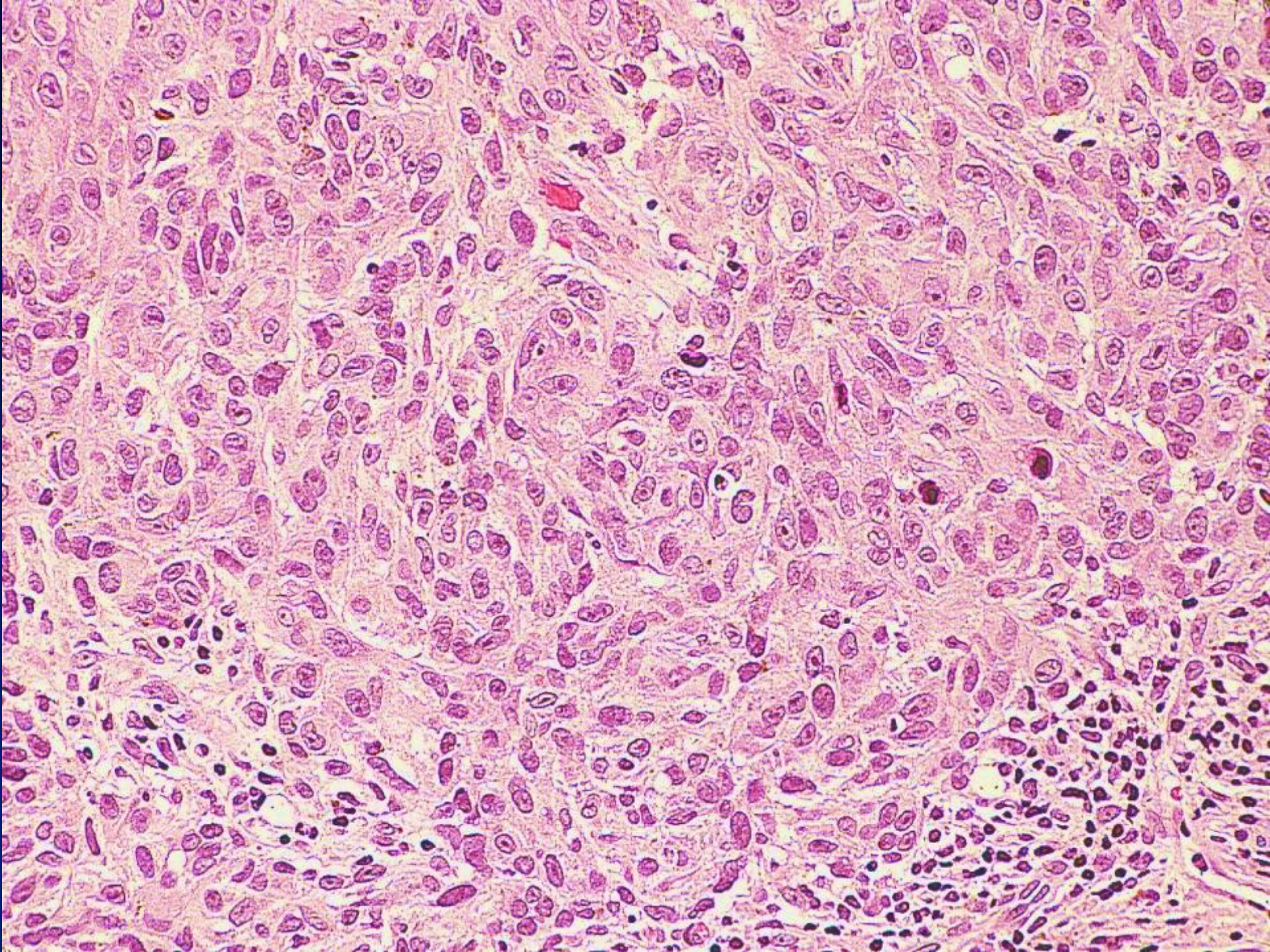
- **Biosynthesis of melanin**
- **T311**
- **Very sensitive (95%).**
- **Very specific (95%).**
- **TRP-1**

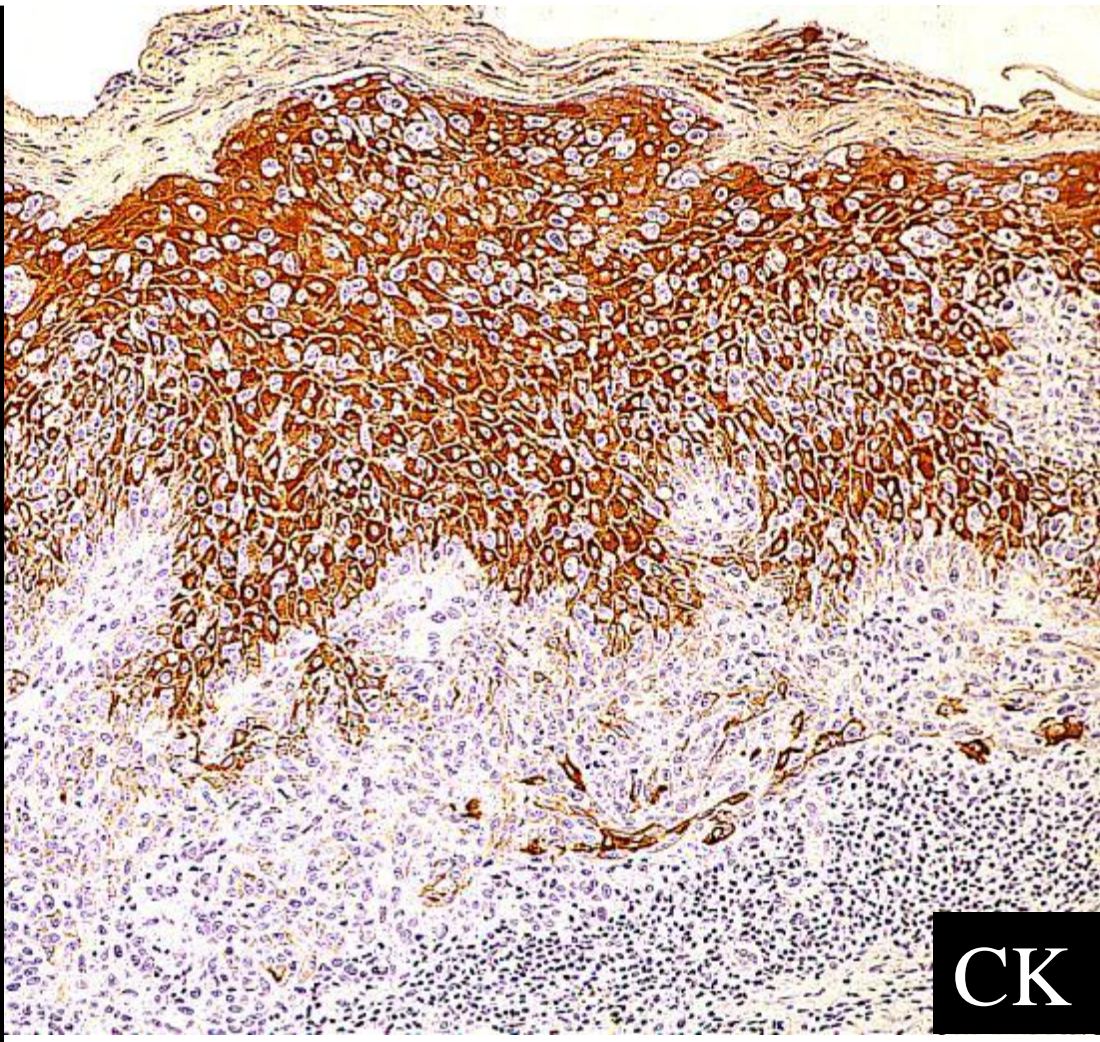
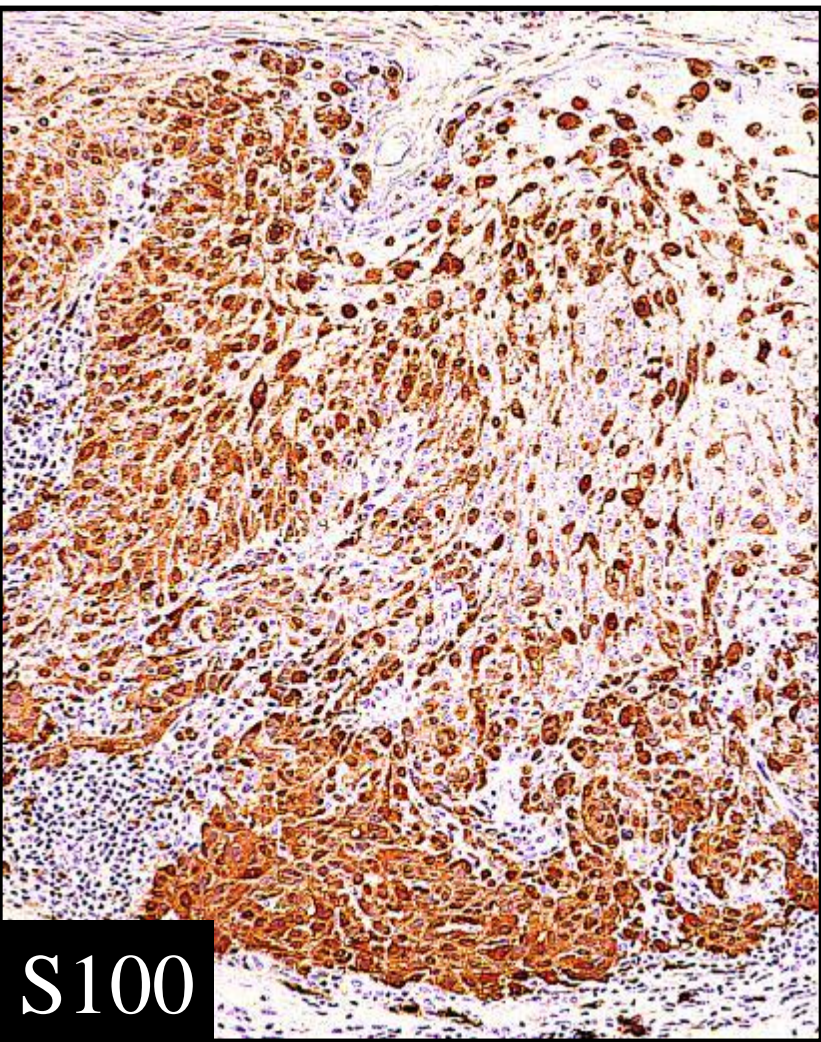
Pan-Melanoma

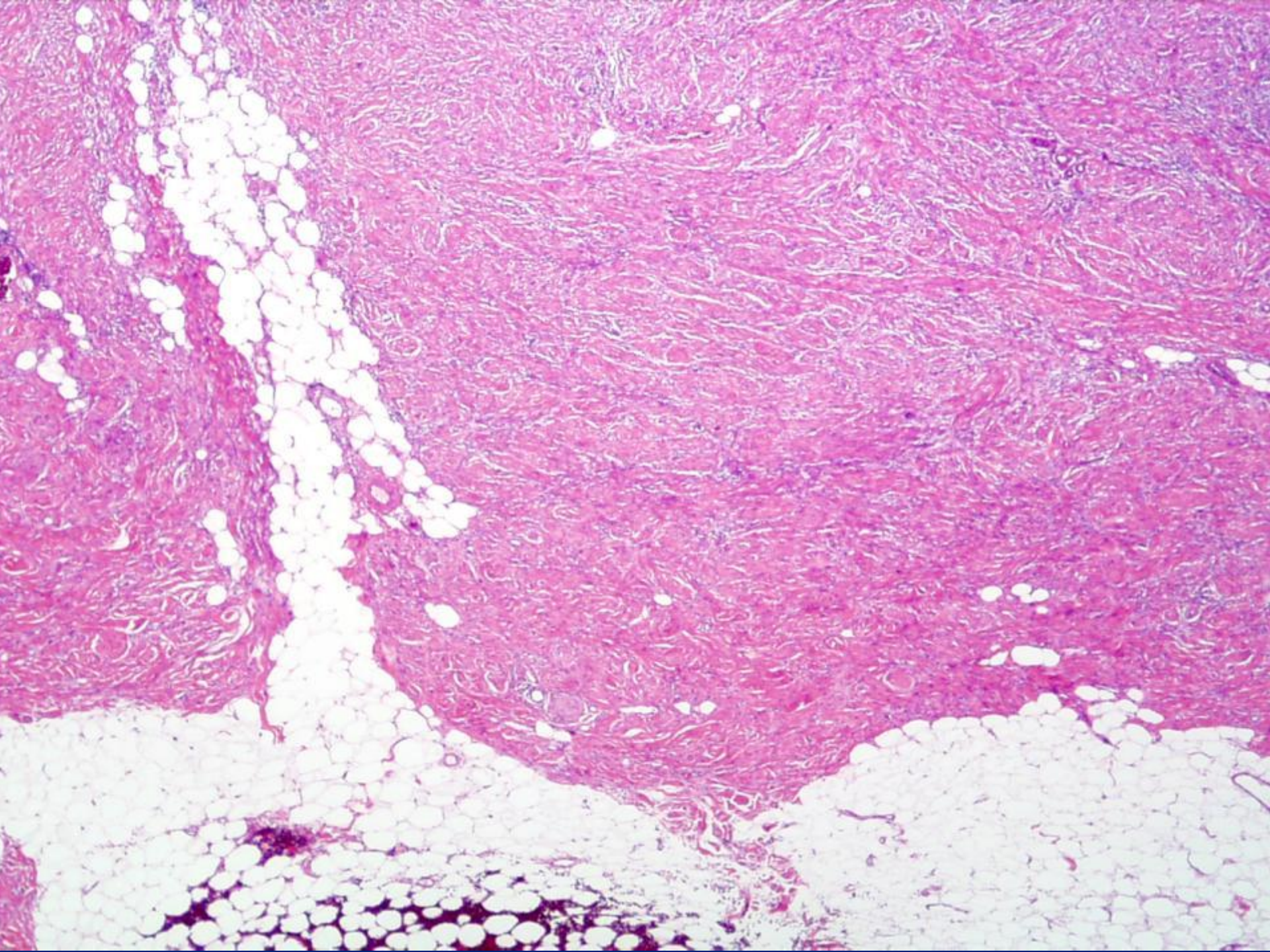
- **Cocktail antibody (HMB-45, MART-1, tyrosinase)**

2. Detection of Level of Invasion

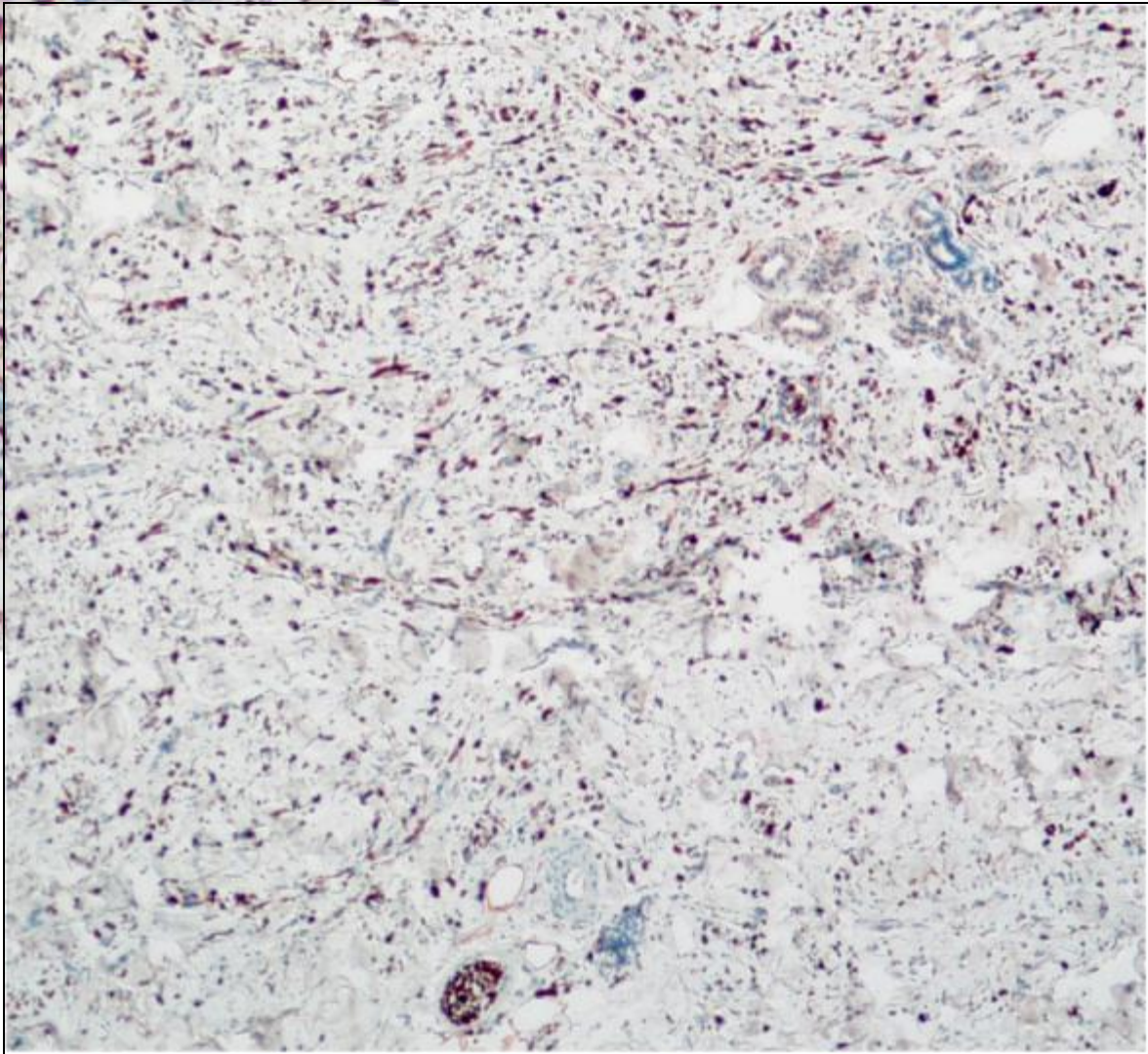
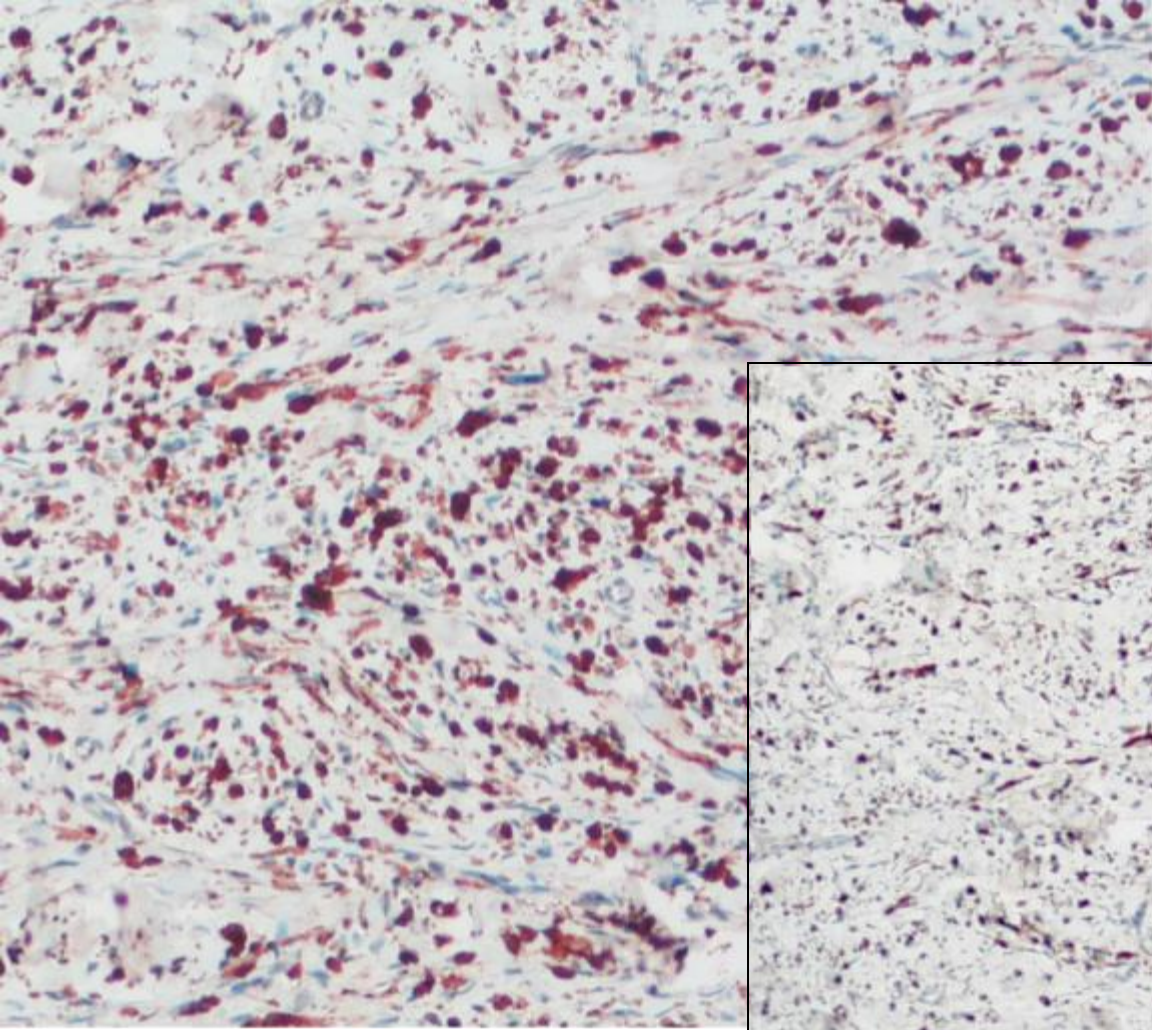
- **Questionable dermal invasion**
- **Desmoplastic melanoma**







S100



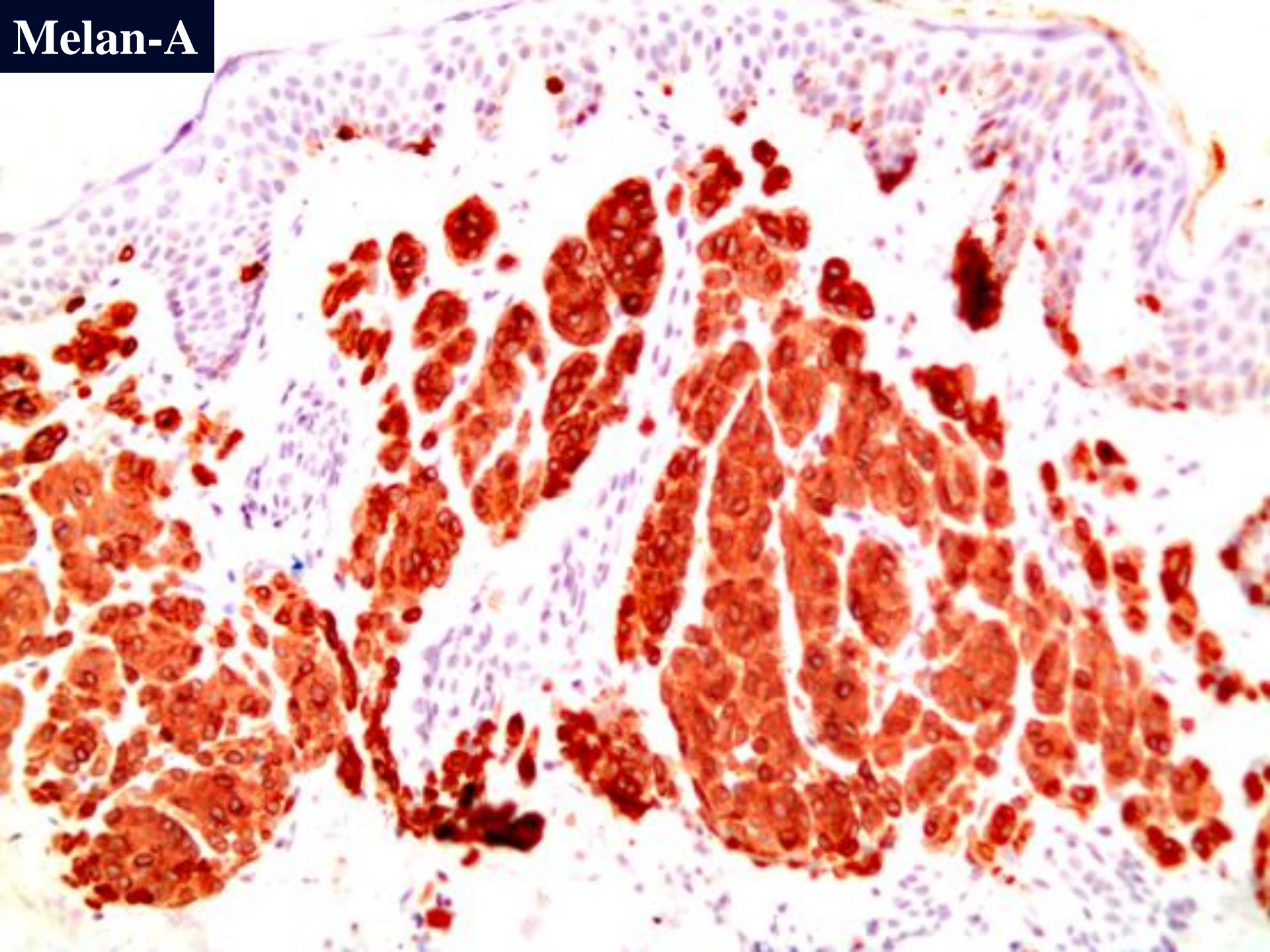
3. Differentiation Between Benign & Malignant Lesions

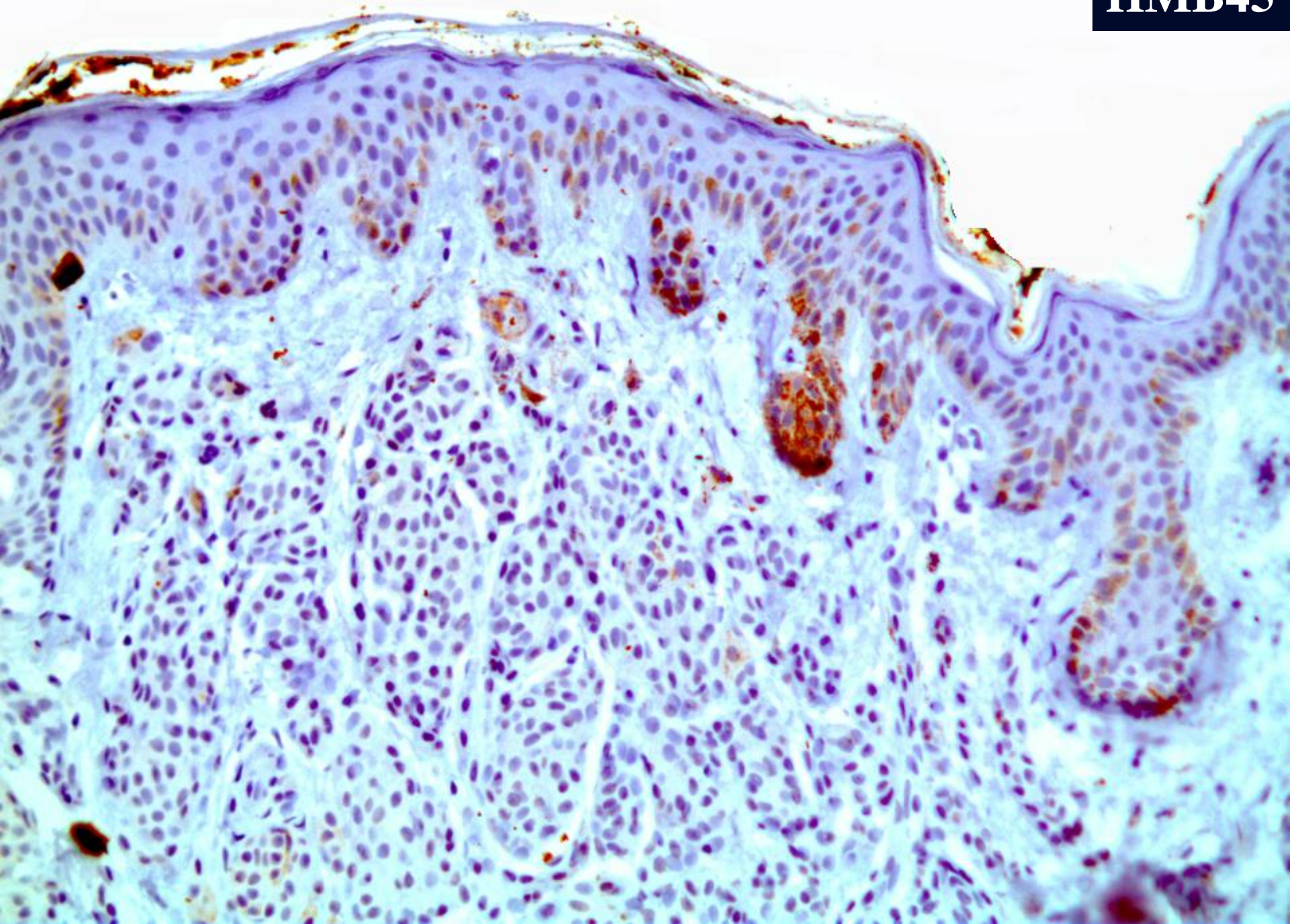
- **HMB-45, Melan-A & Ki67**

Ki-67

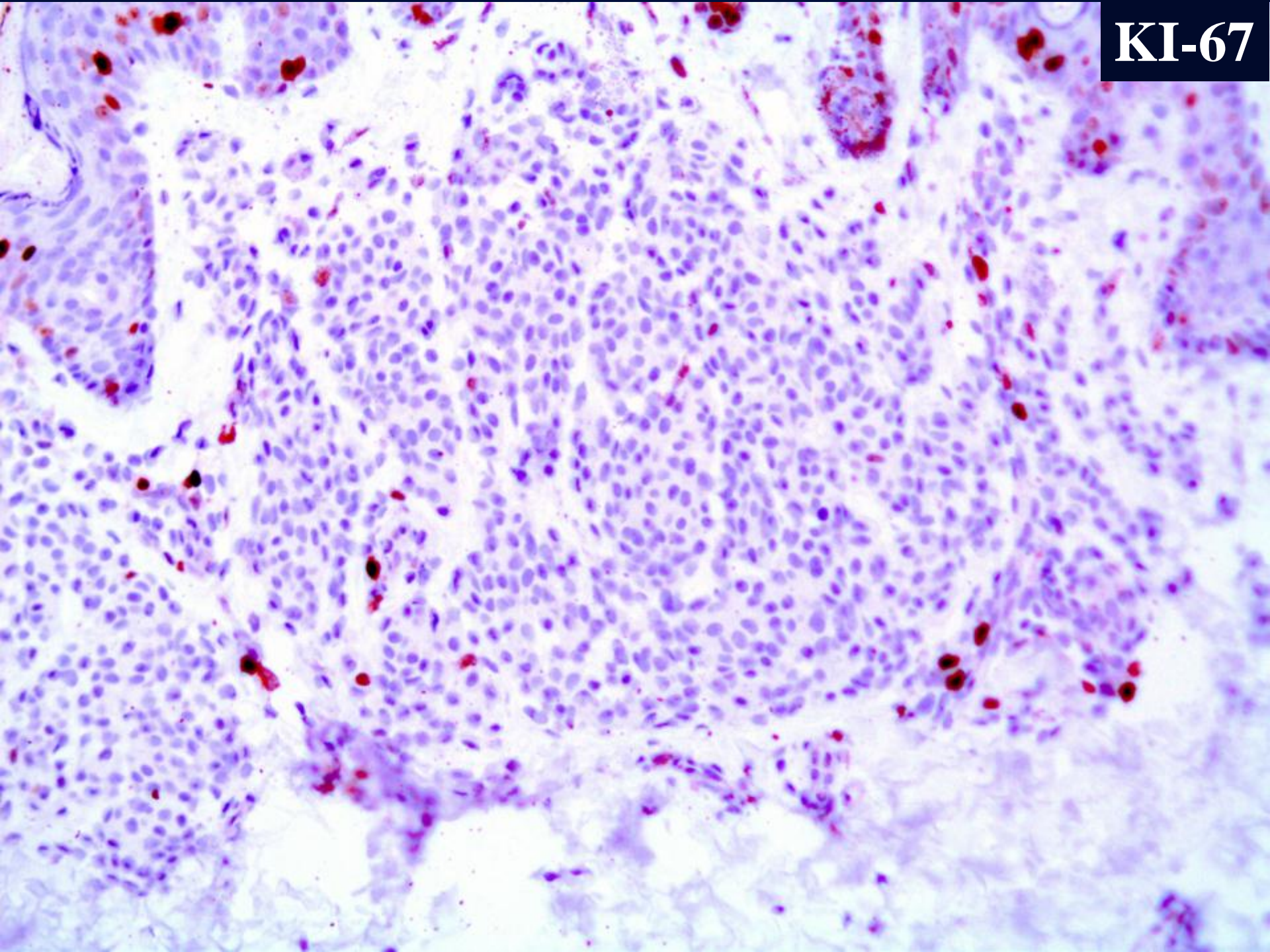
- **Marker of proliferation (cells not in G0)**
- **Expression basal layer of the epidermis**
- **Benign vs. malignant:**
 - **Nevi: Expression in the upper dermis (<5%)**
 - **Melanomas: Expression throughout the lesion (>10%).**

Melan-A



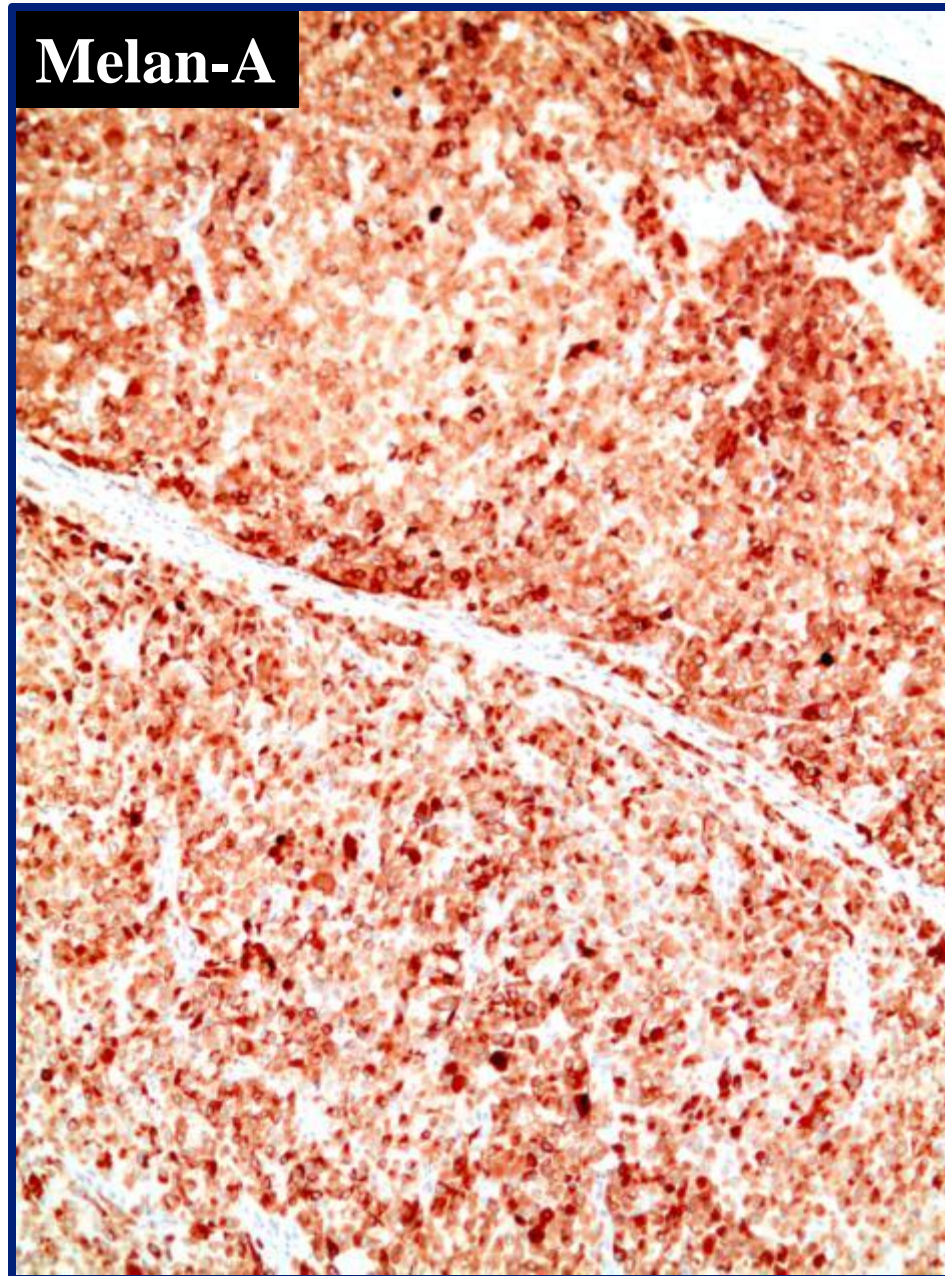


KI-67

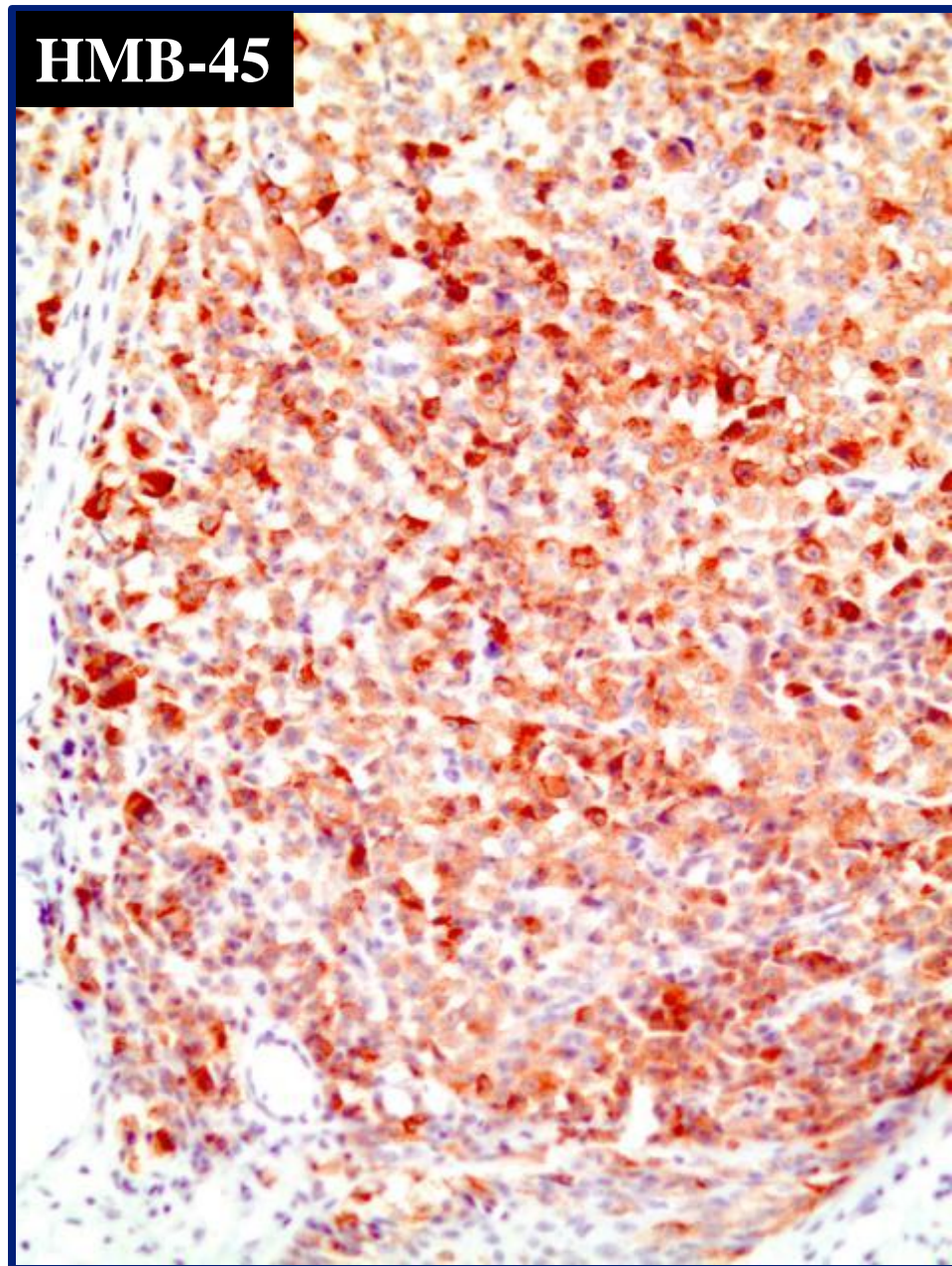


Melanoma

Melan-A



HMB-45



Key Points

- A certain degree of “atypia” of epidermal melanocytes may be seen in congenital nevi
- To qualify for melanoma, the degree of cyto-architectural atypia needs to be very prominent.
- Dermal mitoses and/or atypical mitoses are also features of melanoma
- Maturation” (also IPOX)
- Thickness.

Immunohistochemistry of spindle cell/desmoplastic melanoma (sensitivity)

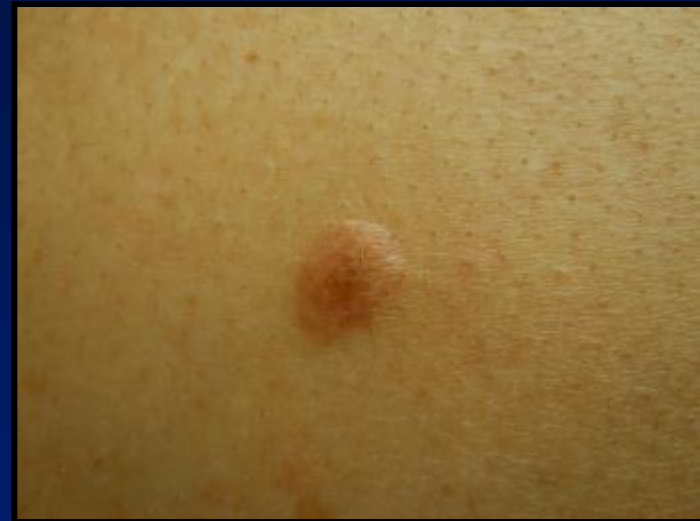- *S100*: 98.7%
- HMB45: 17.6%
- Melan-A: 21.6%
- Tyrosinase: 26.4%
- MITF: 15.5%

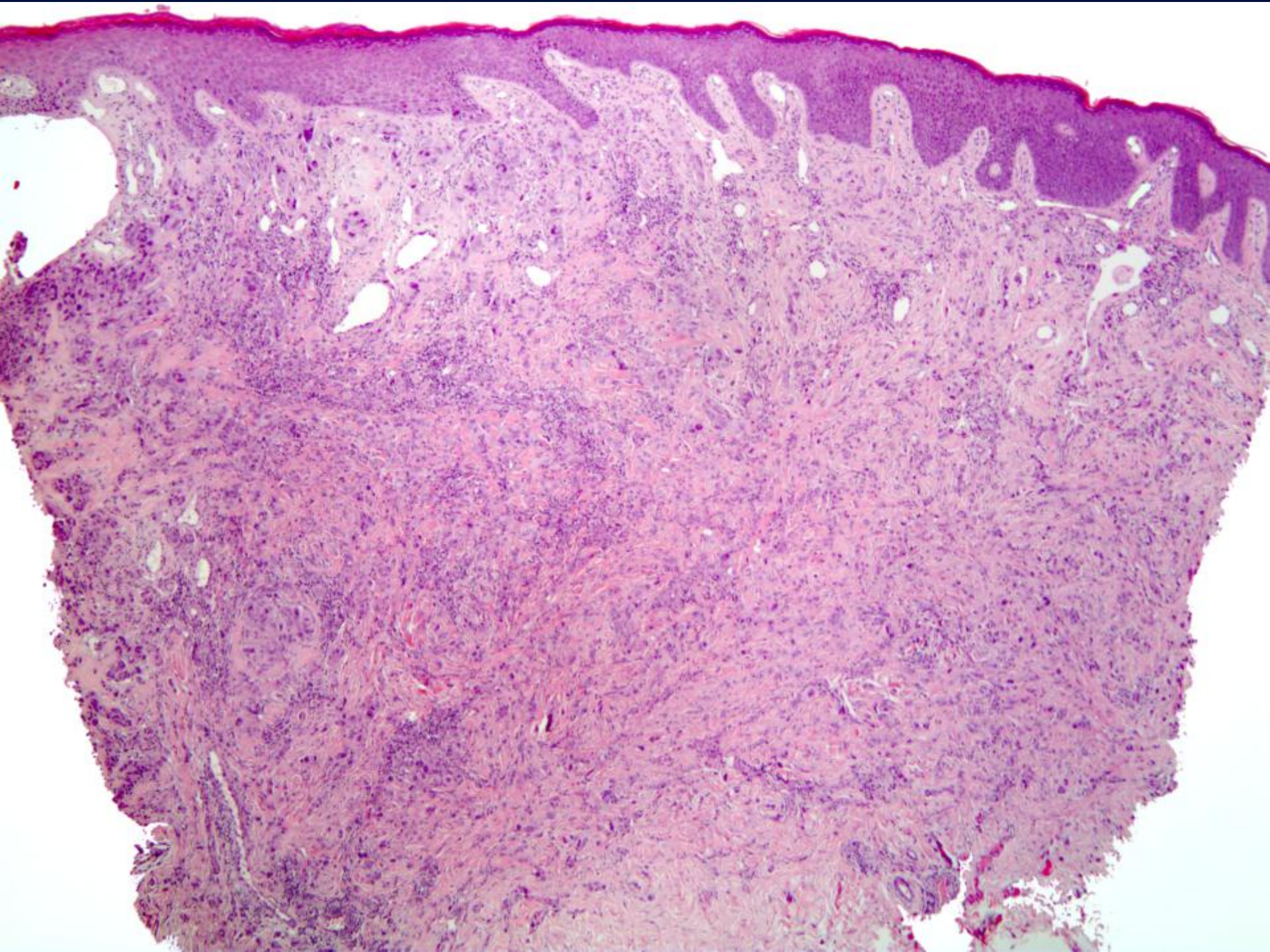
Cutan. Pathol. 2008;85: 35: 433-444

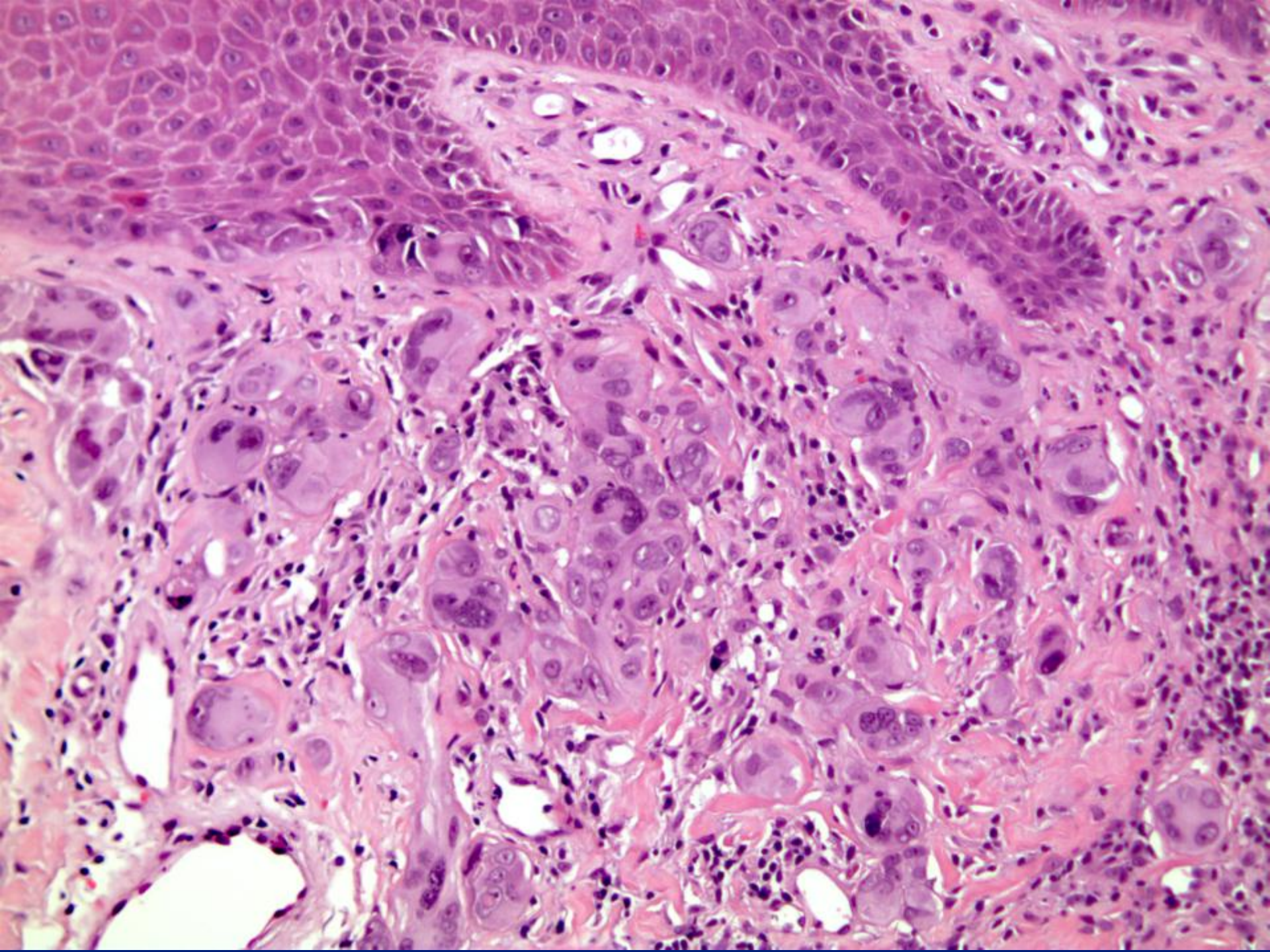
Case 2

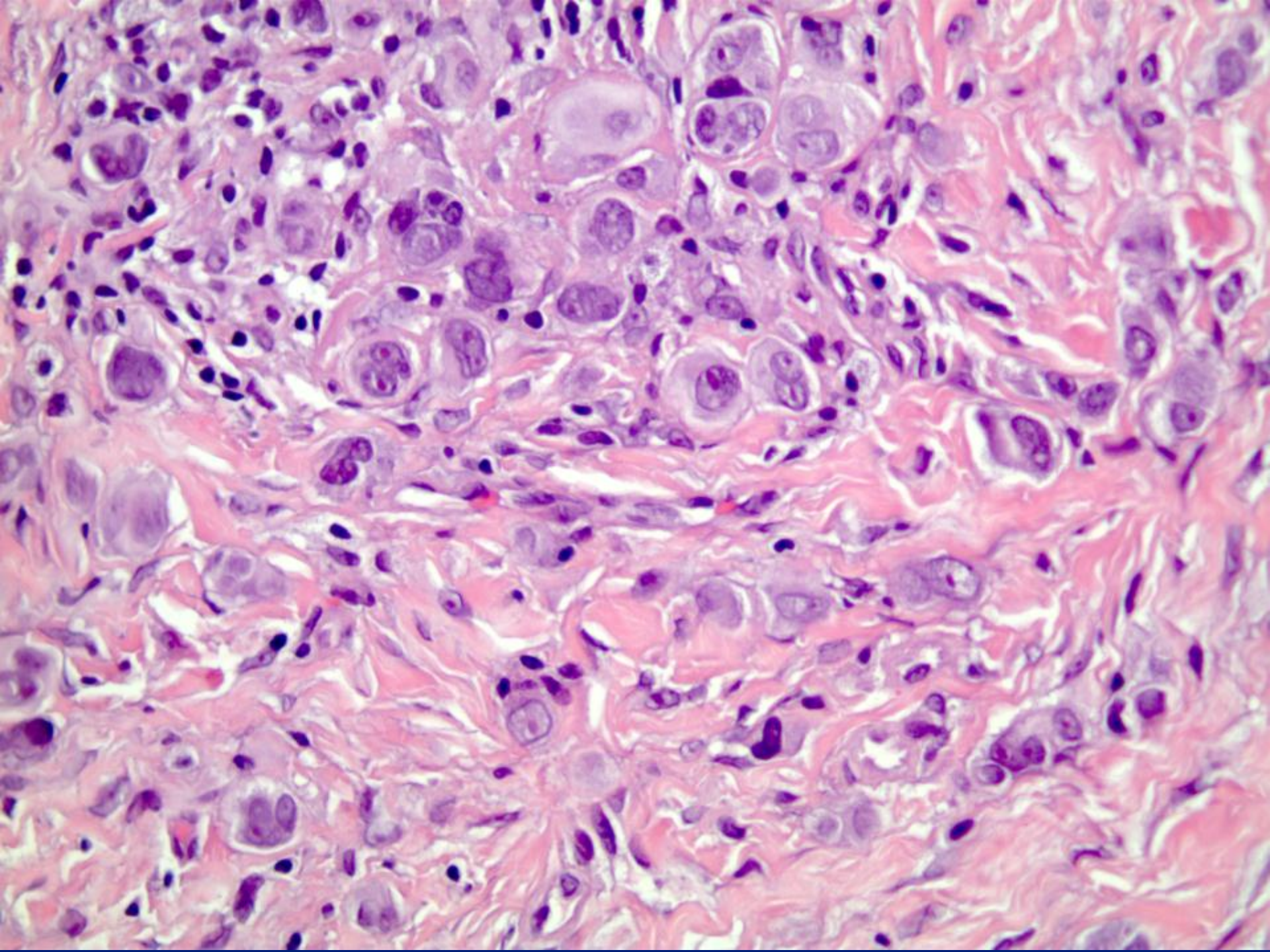
History

- **27 year old lady with a 0.8 cm lesion of the left arm.**
- **(outside diagnosis MM).**









What Is Your Diagnosis?

- A.** Malignant Melanoma.
- B.** Intradermal spitz nevus.
- C.** Epithelioid Histiocytoma.
- D.** Epithelioid Sarcoma.
- E.** Reticulohistiocytoma.

What Is Your Diagnosis?

- A.** Malignant Melanoma.
- B.** Intradermal spitz nevus.
- C.** Epithelioid Histiocytoma.
- D.** Epithelioid Sarcoma.
- E.** Reticulohistiocytoma.

Intradermal Spitz Nevus

- Rare variant of SN.
- Age range: 5-81 years.
- ♂/♀:1/3.
- Upper ext. & HN
- Size: 0.2 -1.3 cm.
- Limited to the dermis.
- Benign (recurrence in 5%)

Intradermal Spitz Nevus

Microscopy

- **Based in the reticular dermis.**
- **Epithelioid, spindle or mixed.**
- **Hyalinized (15), polypoid (14), desmoplastic (10), halo (7) & angiomatoid (3).**
- **Cytologic atypia: Mild to severe.**

Intradermal Spitz Nevus

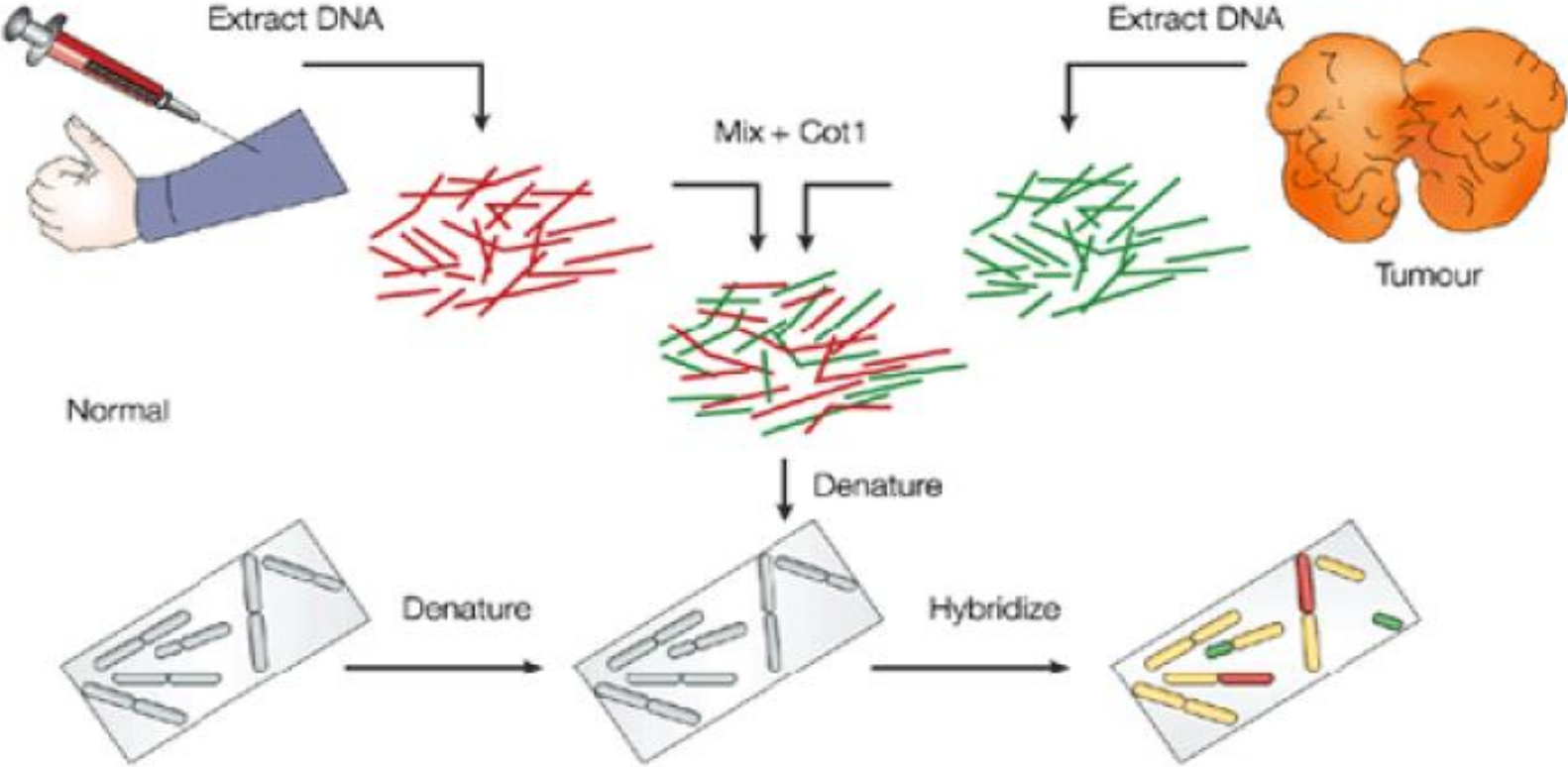
Microscopy

- **Maturation: in 85% of cases.**
- **Melanin pigment in 26%.**
- **Mitoses: in 38%.**
- **Number of mitoses:**
 - 1 in 21 cases
 - 2 mitoses in 7 cases
 - 3 mitoses in 1 case
 - always in superficial part of the lesion.

IPOX

- **Ki-67: 2-10% labeling only on superficial portion.**
- **HMB-45: Maturation in all cases.**

CGH




Normal

Tumour

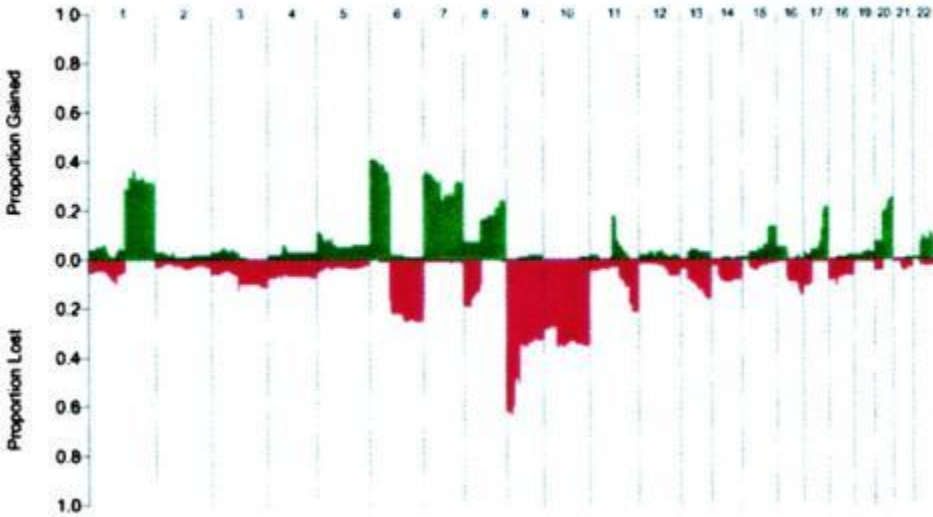
Normal metaphase chromosome

Nature Reviews | Cancer



The ratio of green:red signals along each chromosome is determined

Melanomas

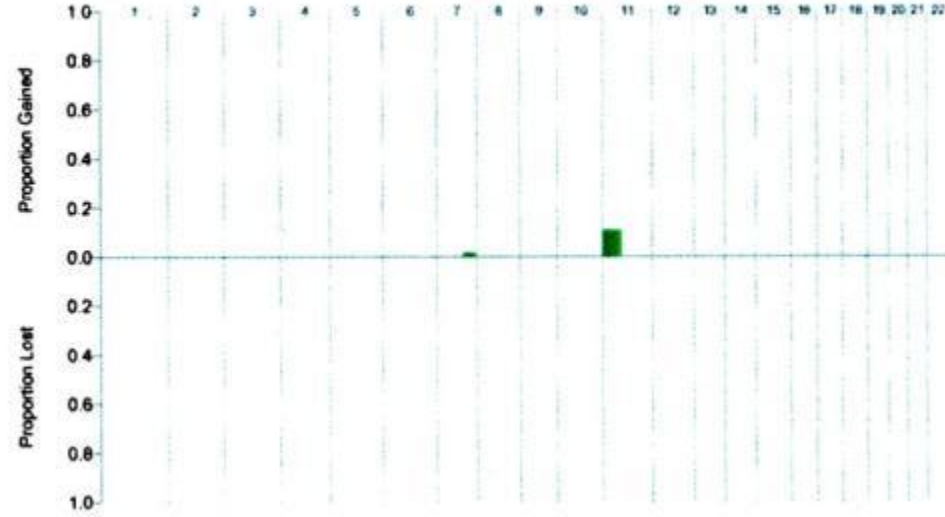


Gains: 6p
1q
7p
7q
8q
17q
20q

Losses: 9p
9q
10q
10p
6q
11q

96% of cases

Nevi

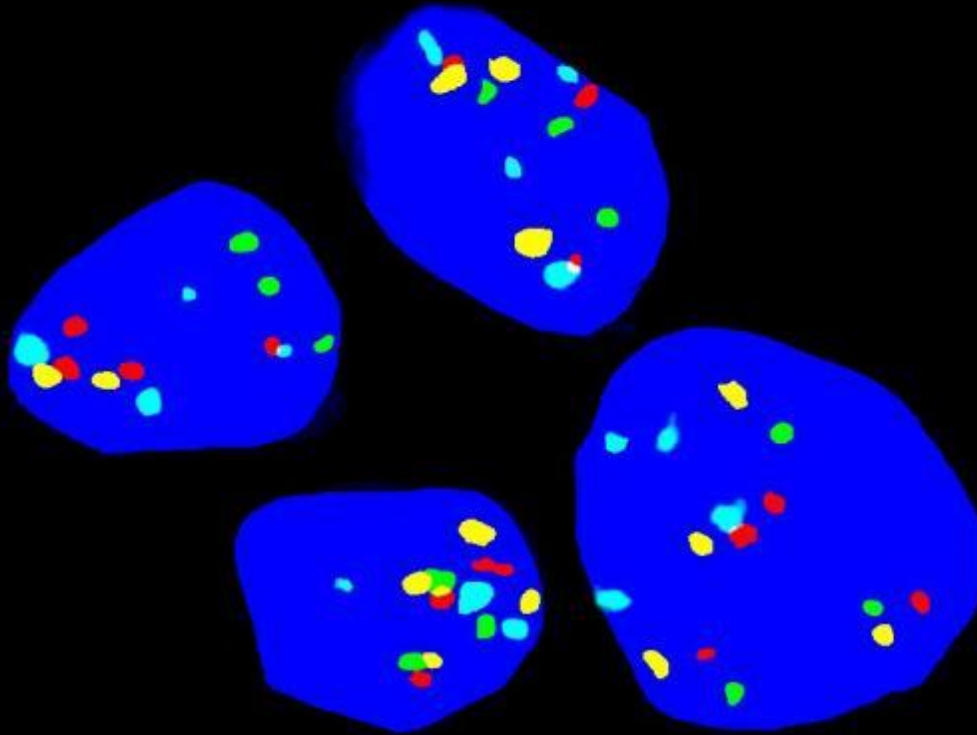


Gains: 11p: 11%
7q: 2%

Losses: 0%

•The 7 cases were all Spitz nevi
(no progression to MM at 7 yrs
FU)

Fluorescence in situ Hybridization



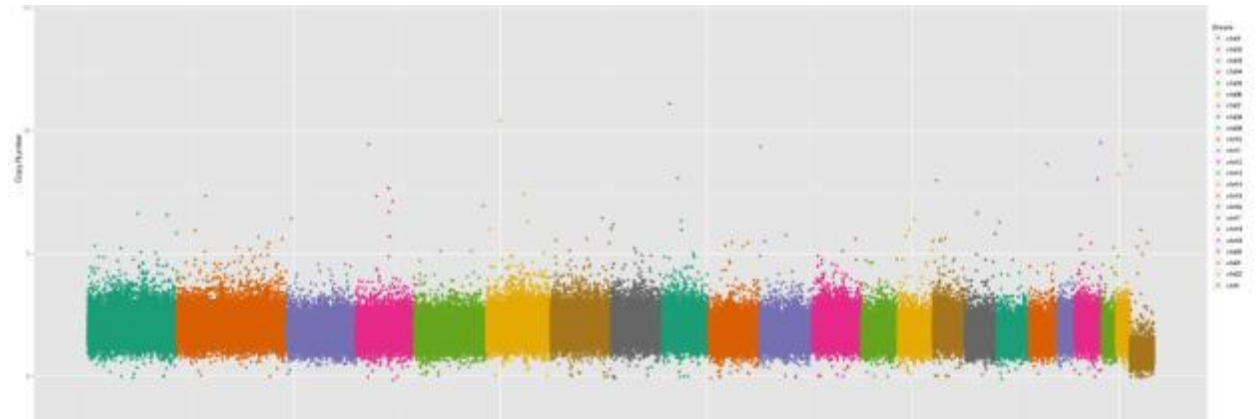
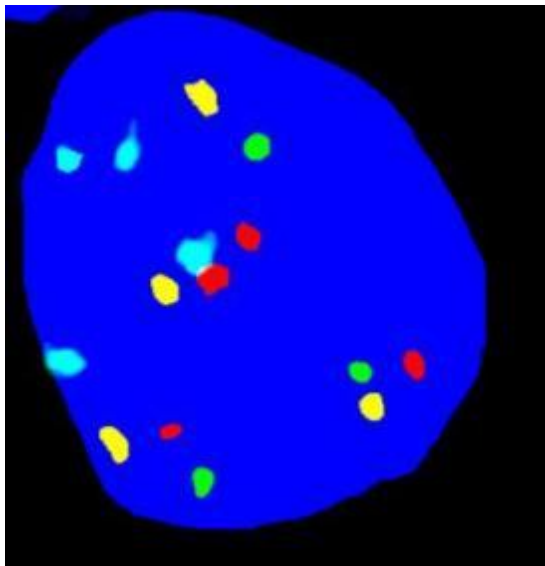
6p25 RREB1
6q23 MYB
CEP6
11q13 CCDN1

Our case

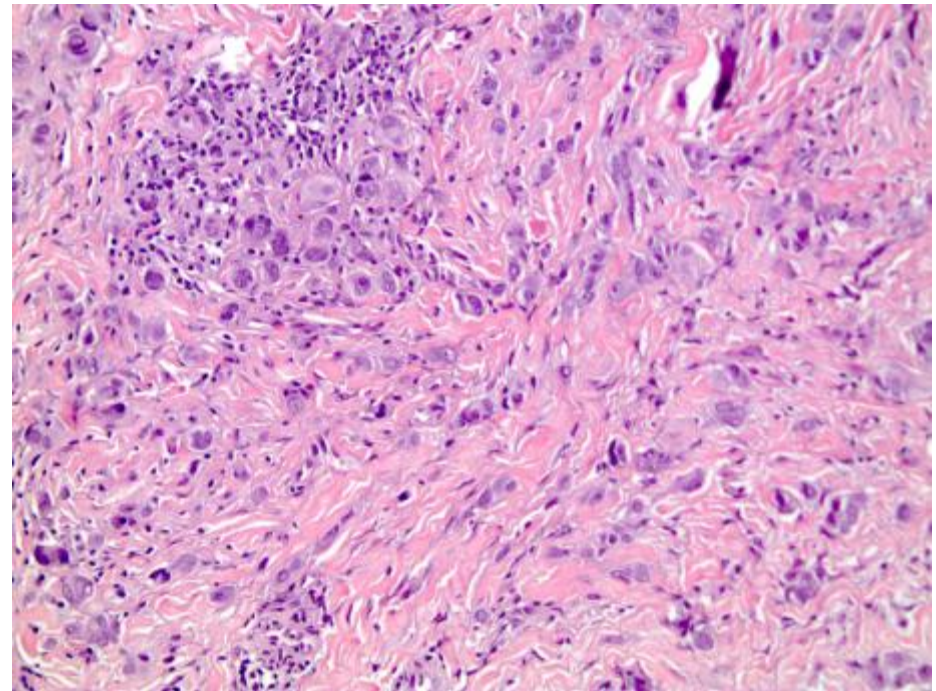
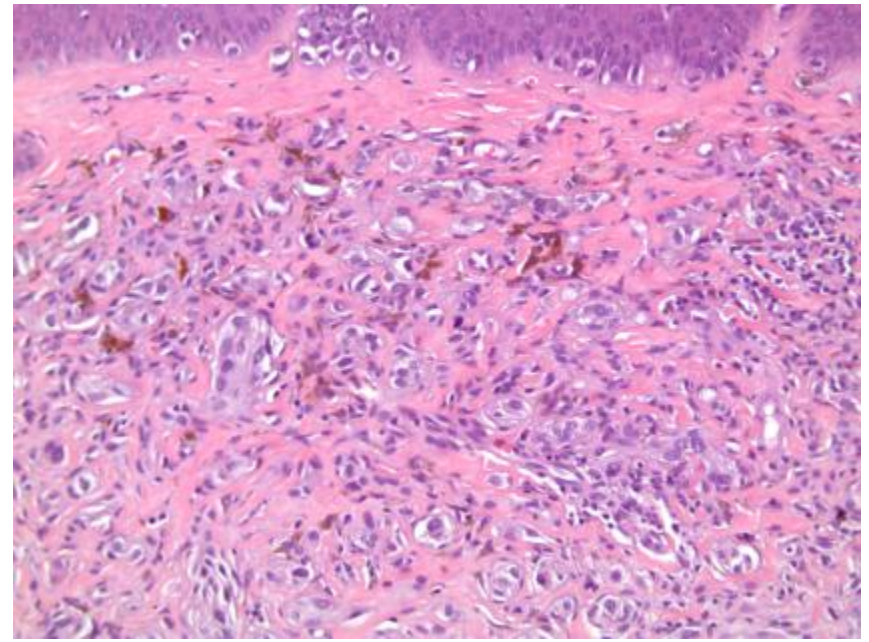
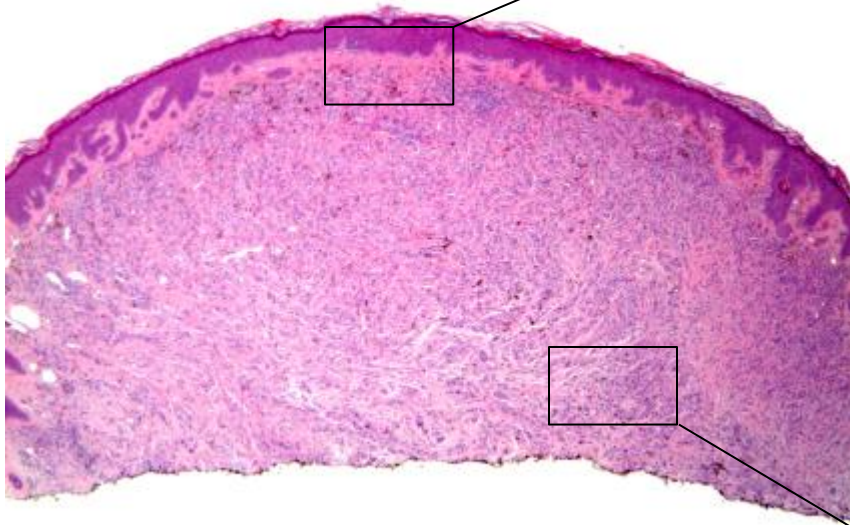
- CGH/ FISH results support benign nevus over melanoma

Tetraploidy

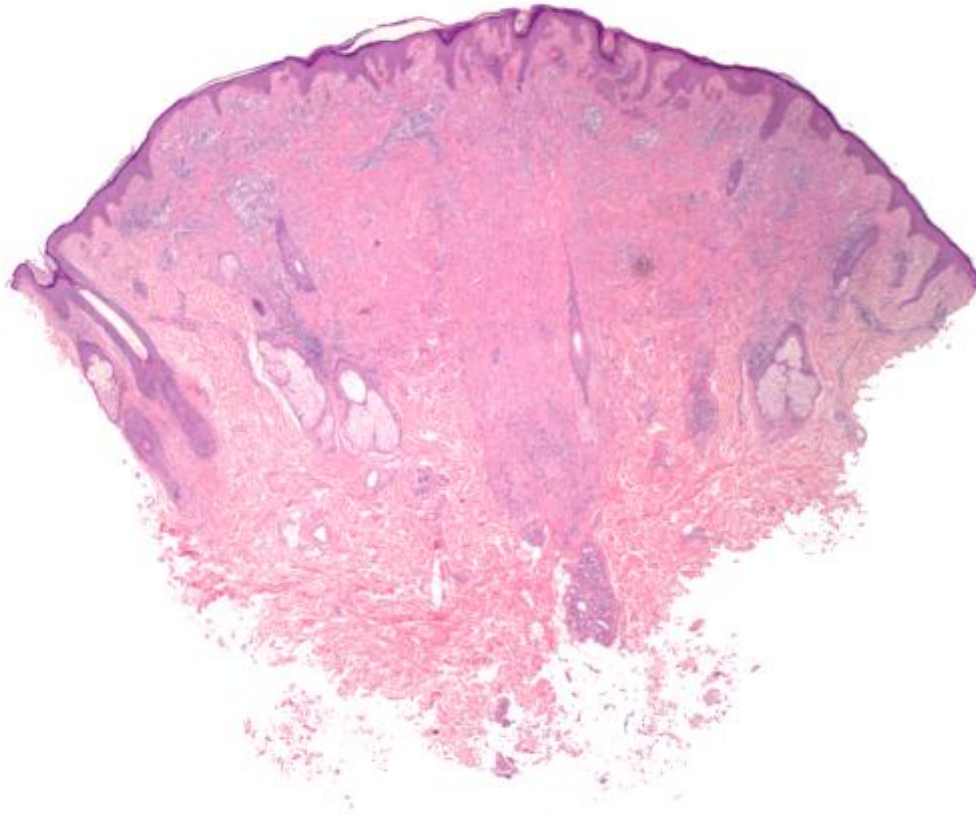
No Gains and losses

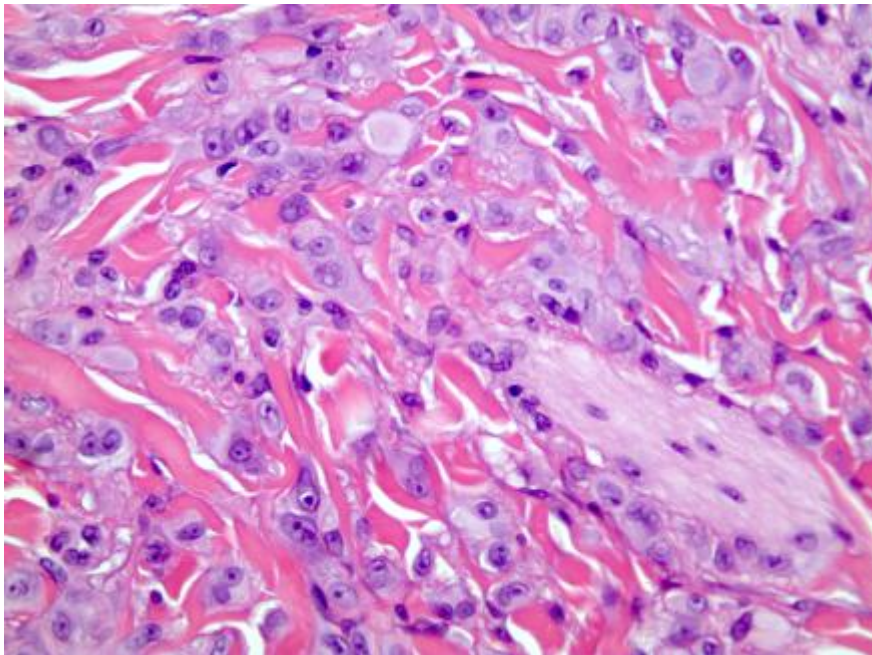
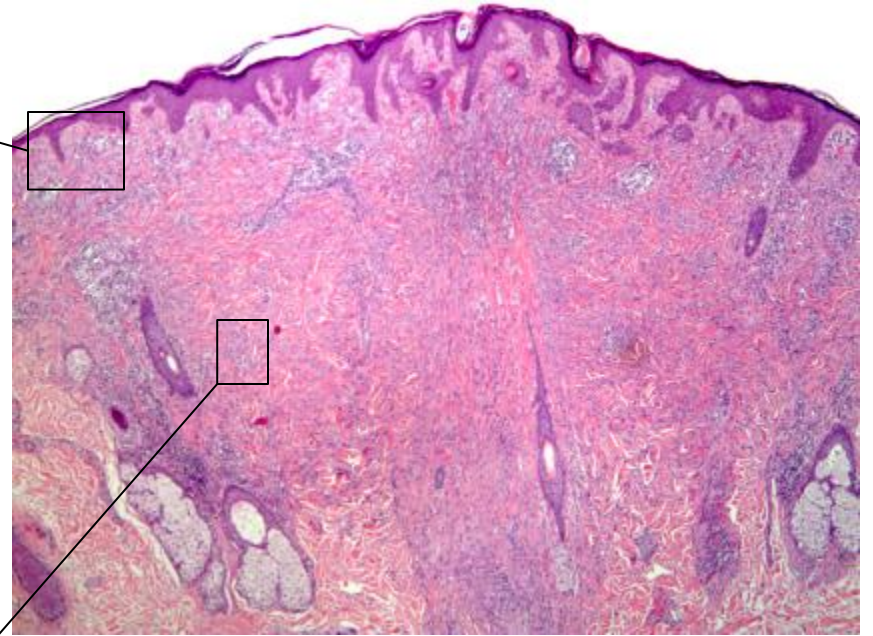
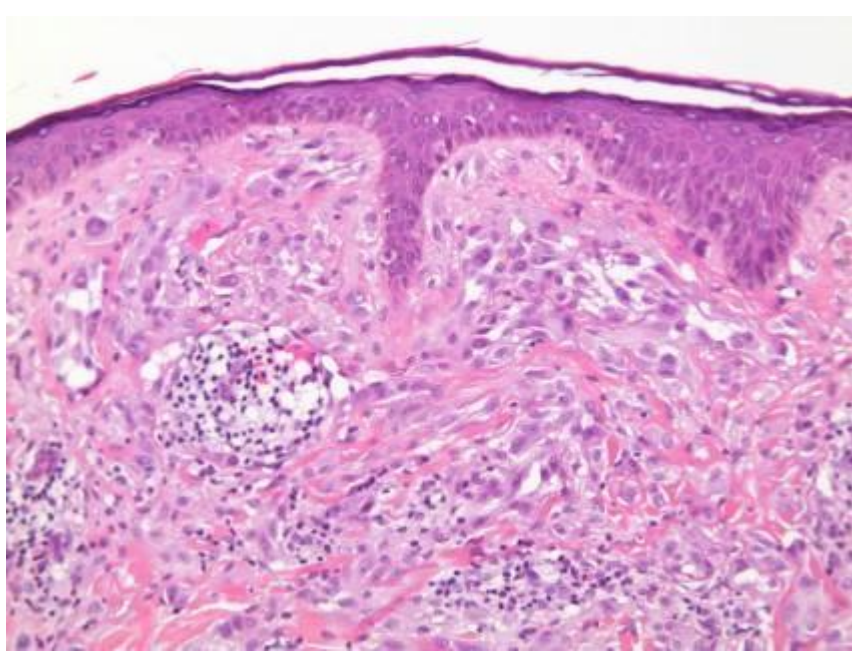


- 27 year old man with facial pigmented nodule.



- **51 year old women with skin color 1 cm nodule on proximal right upper ext.**

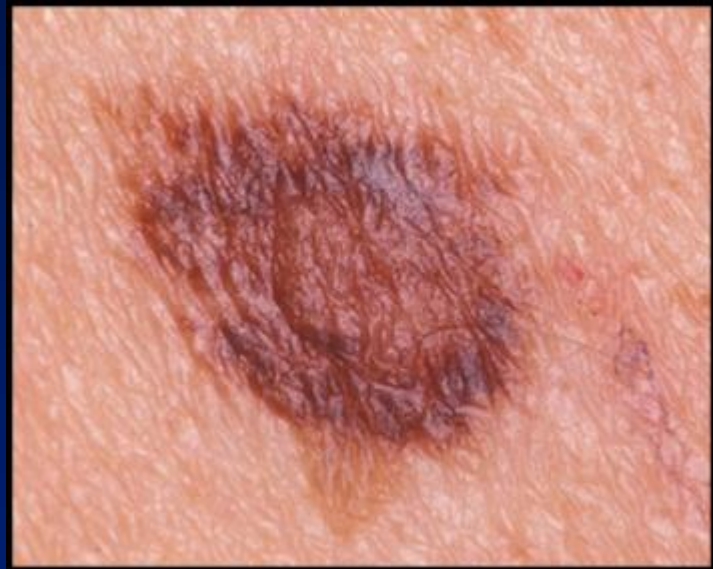


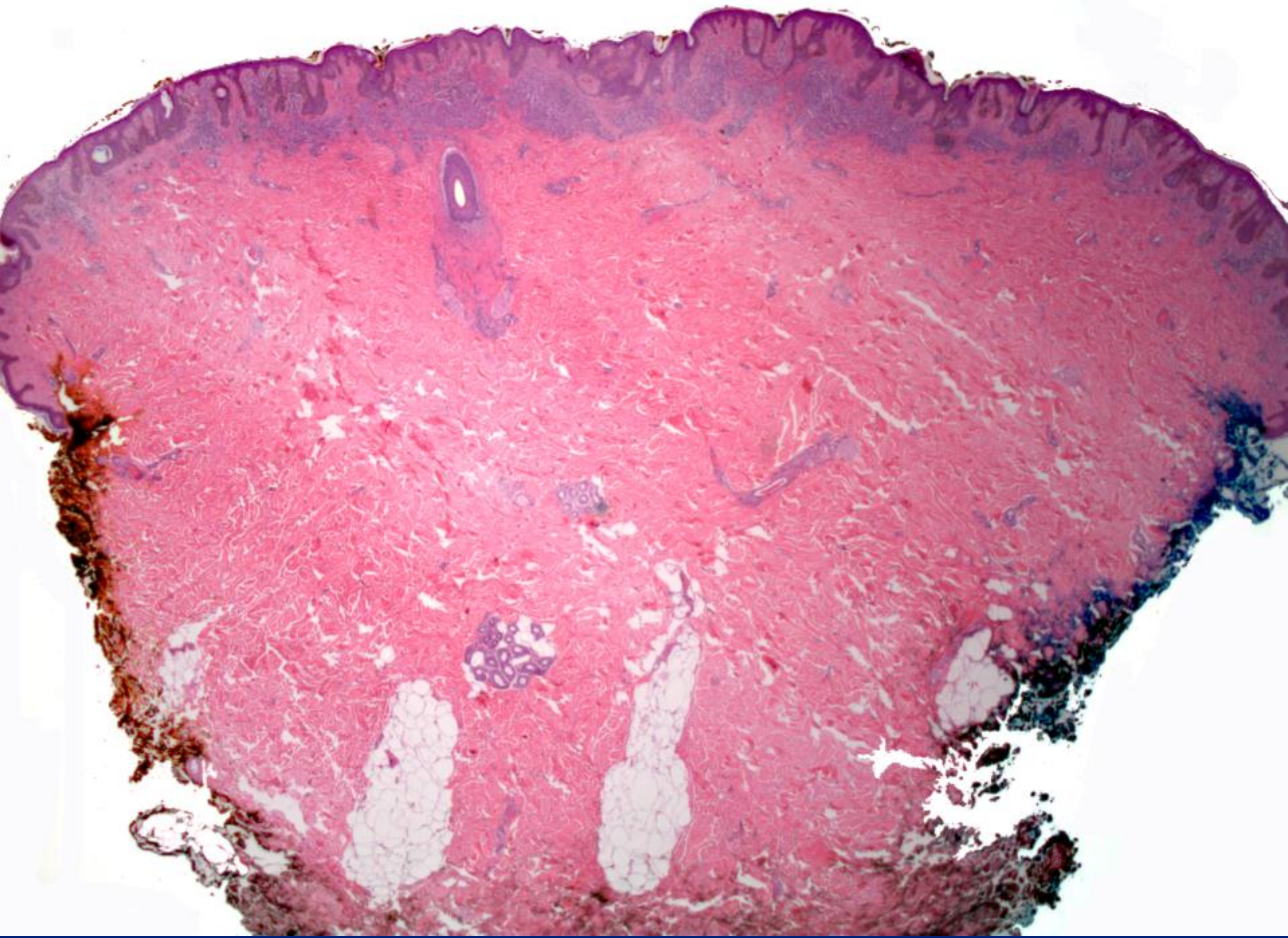


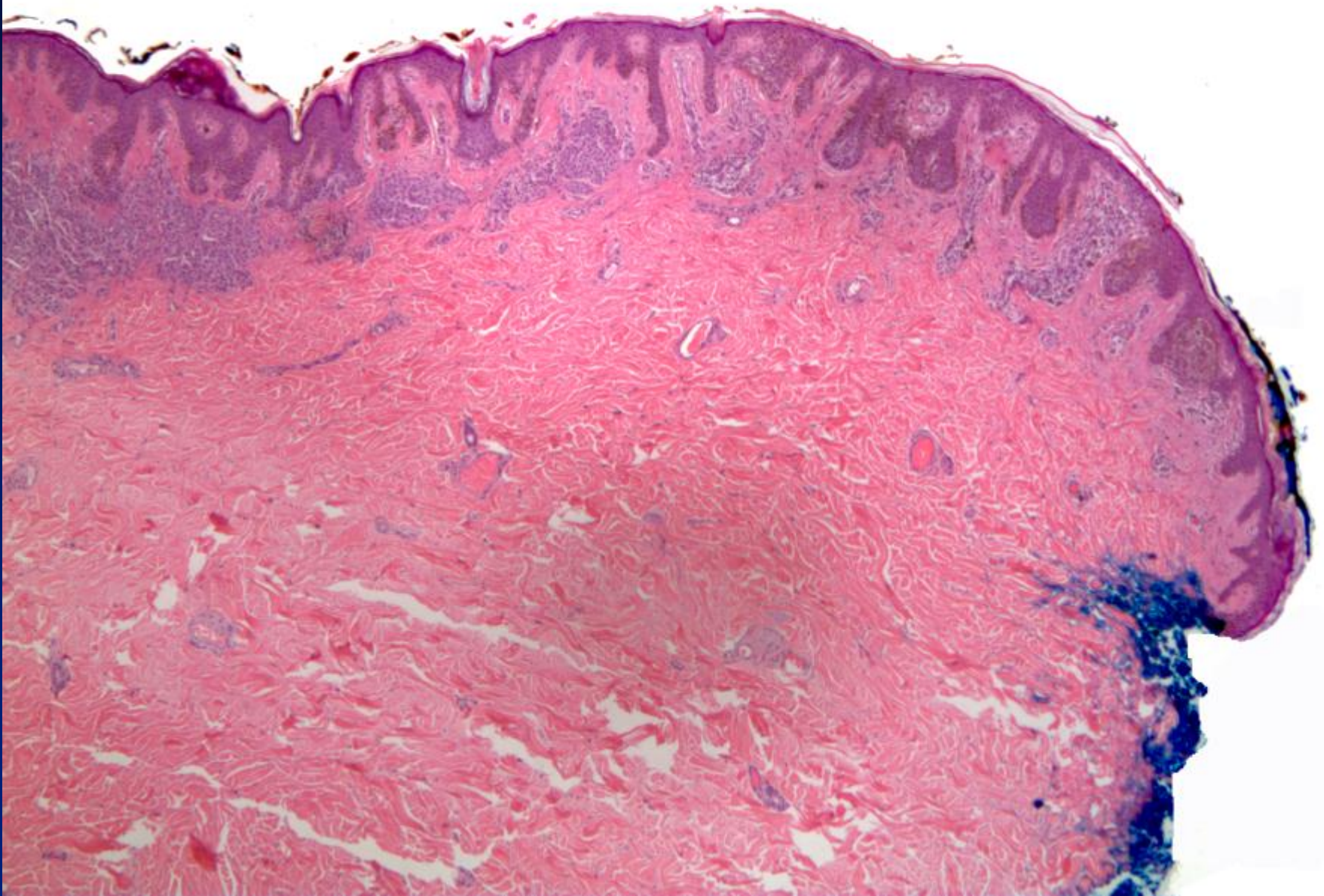
Case 3

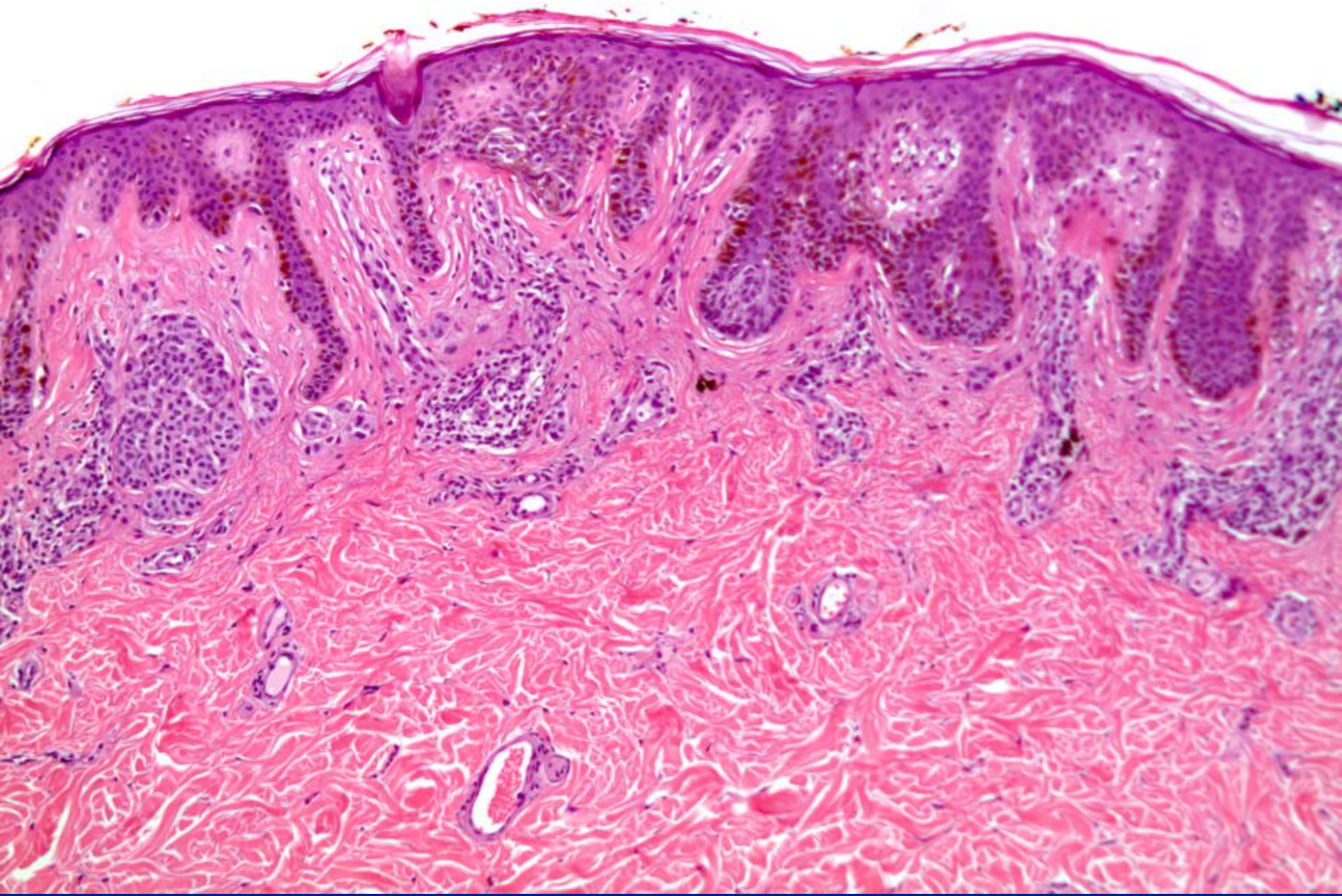
History

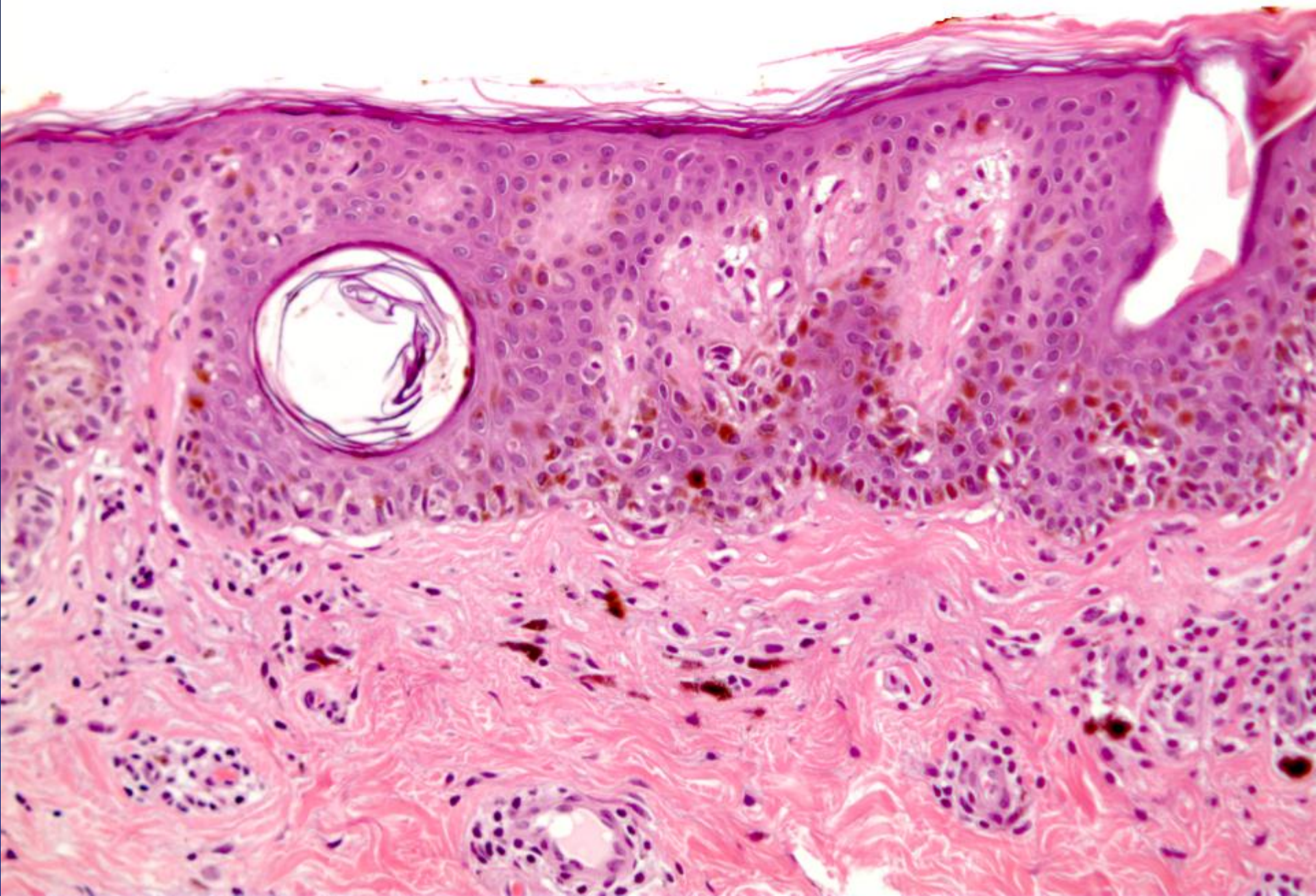
- **31 year-old resident with changing mole on the trunk 0.5 cm.**
- **? Melanoma**

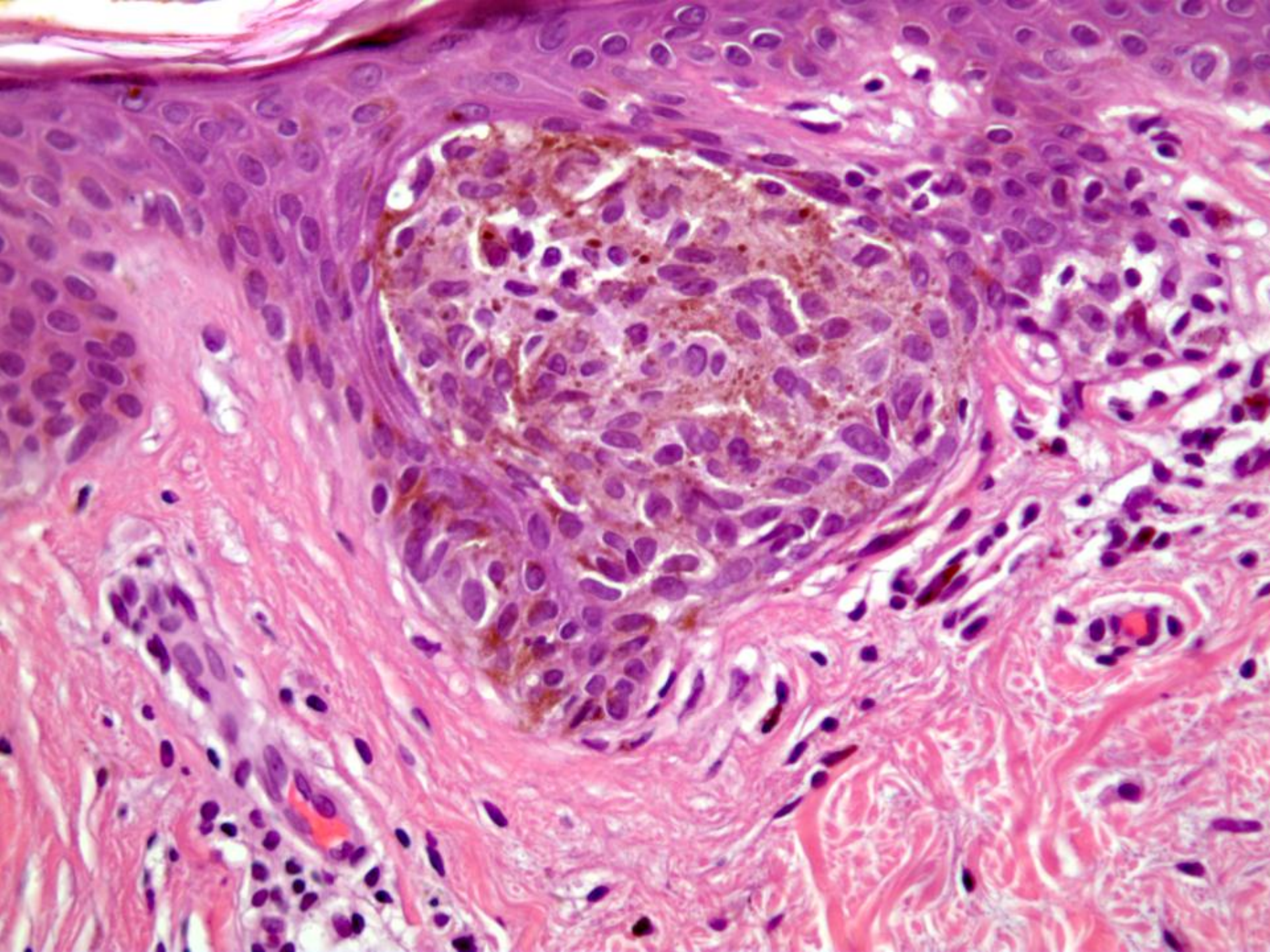


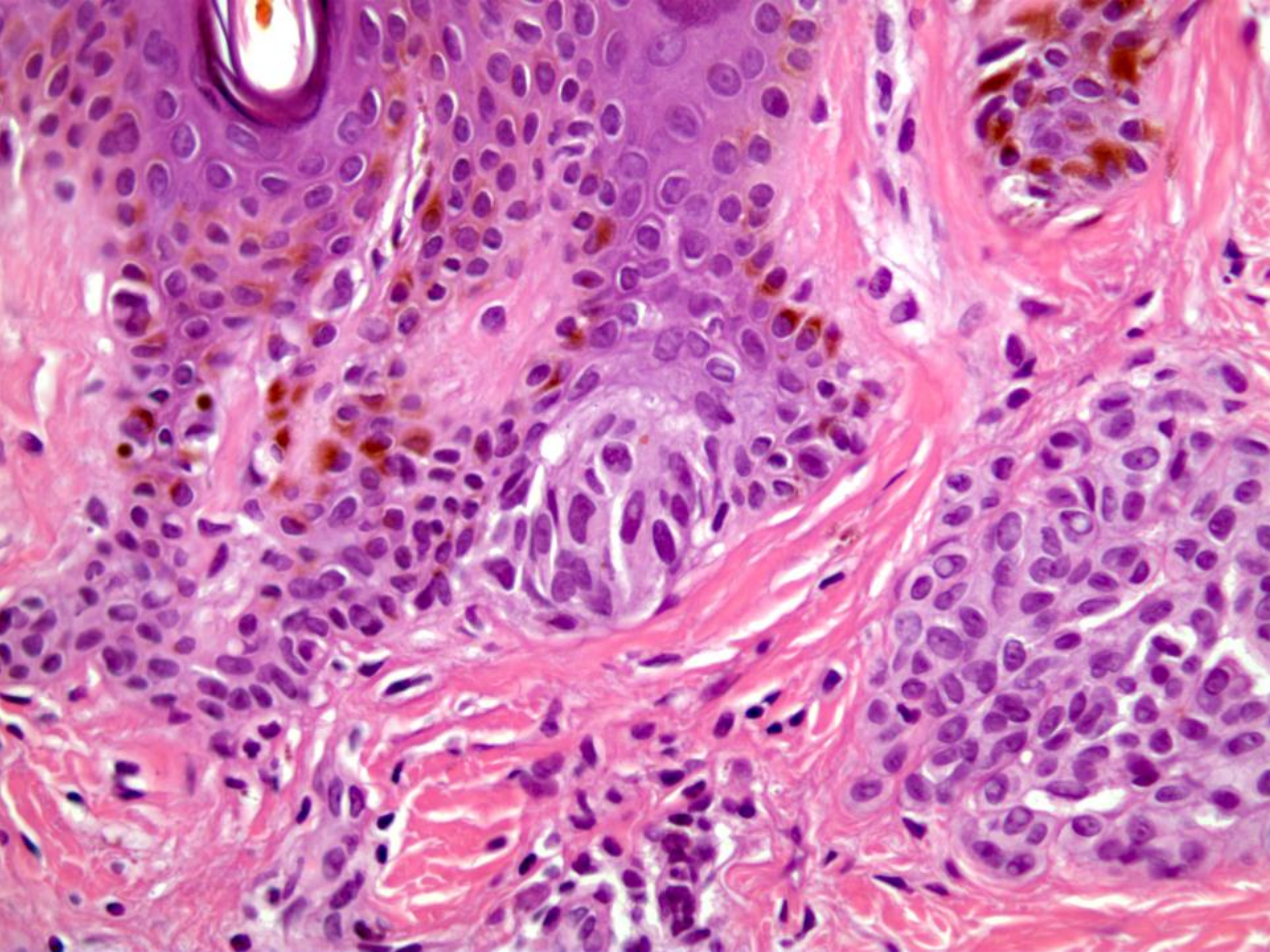


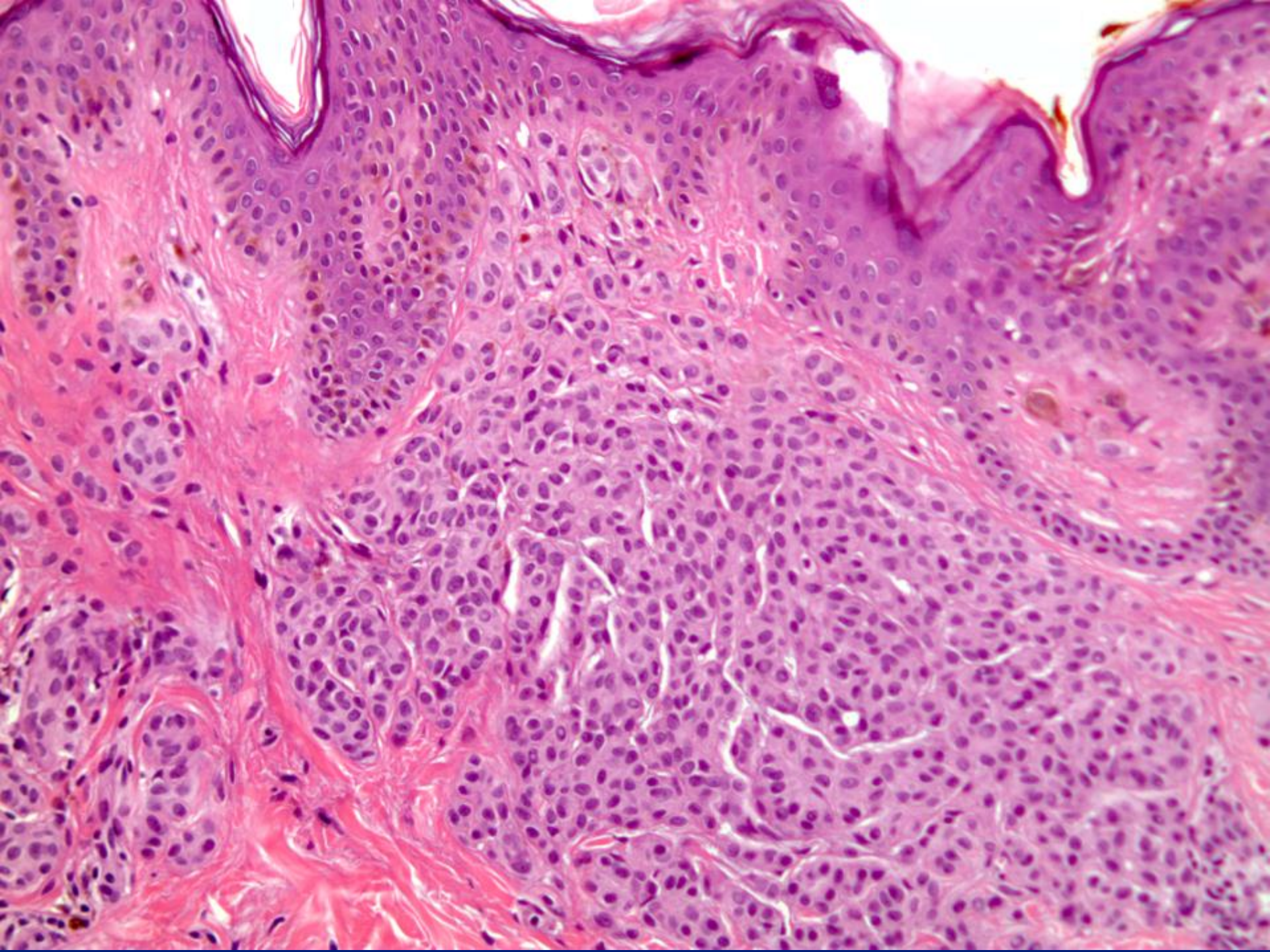


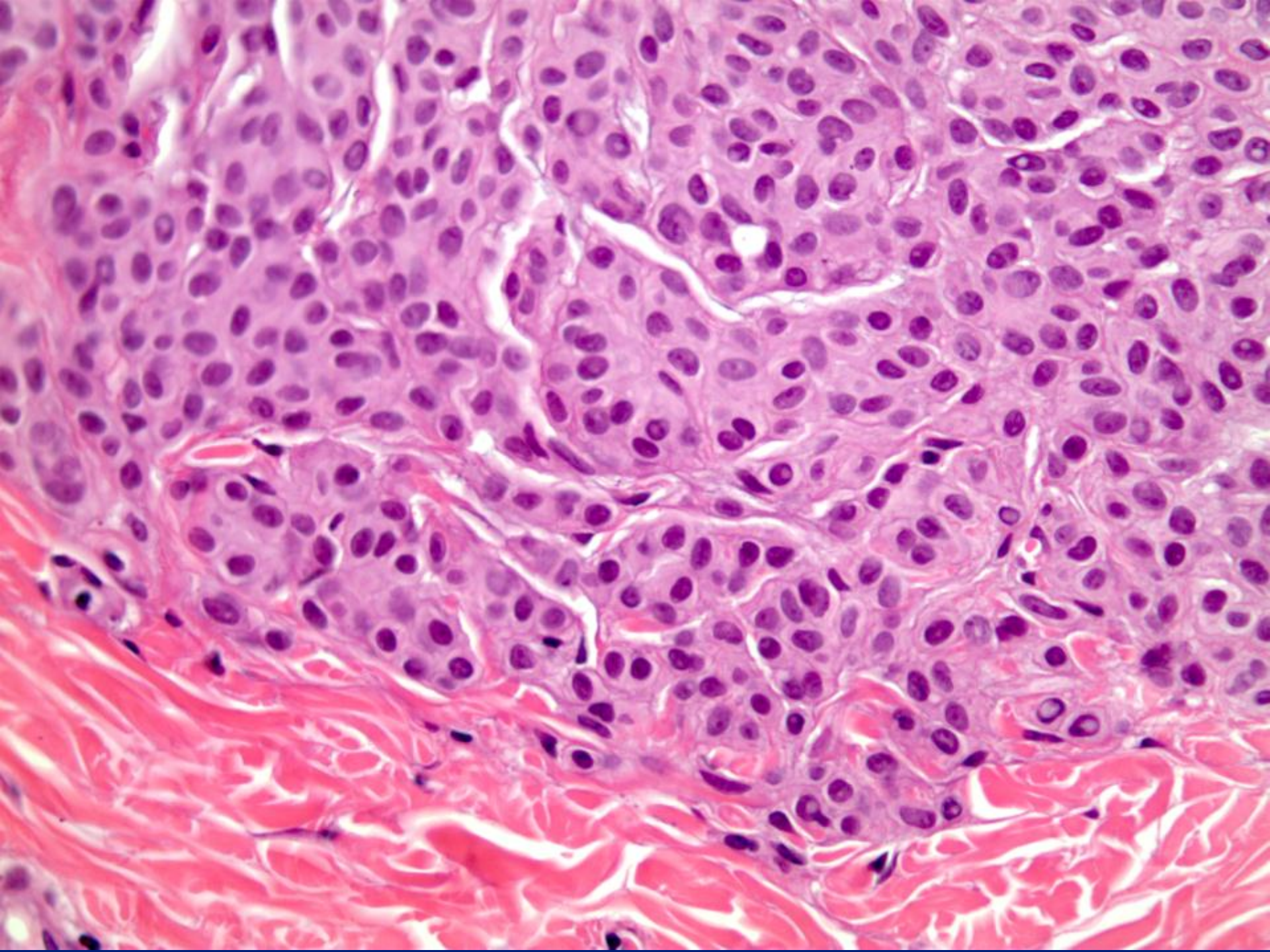












Your Diagnosis:

- A. Dysplastic Melanocytic Nevus.**
- B. Melanoma In-situ + IDN.**
- C. Invasive Melanoma.**
- D. Congenital Melanocytic Nevus.**

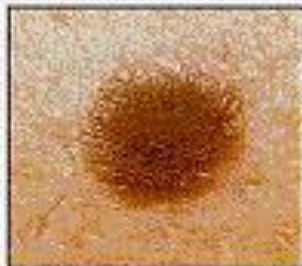Your Diagnosis:

- A.** *Dysplastic Melanocytic Nevus.*
- B.** Melanoma In-situ + IDN.
- C.** Invasive Melanoma.
- D.** Congenital Melanocytic
Nevus.

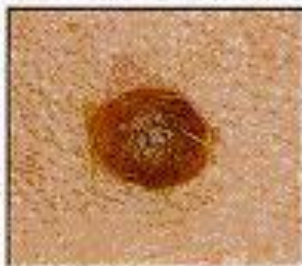Full Diagnosis

- **Dysplastic nevus mild architectural disorder and mild cytologic atypia.**
- **Margins: Negative in plane of sections**

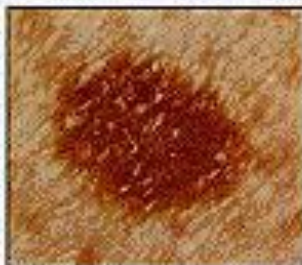
Benign



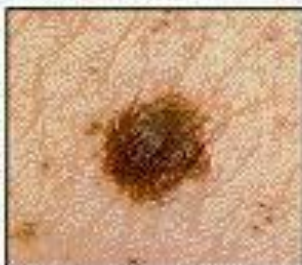A. Asymmetry Symmetrical



B. Border Even edges

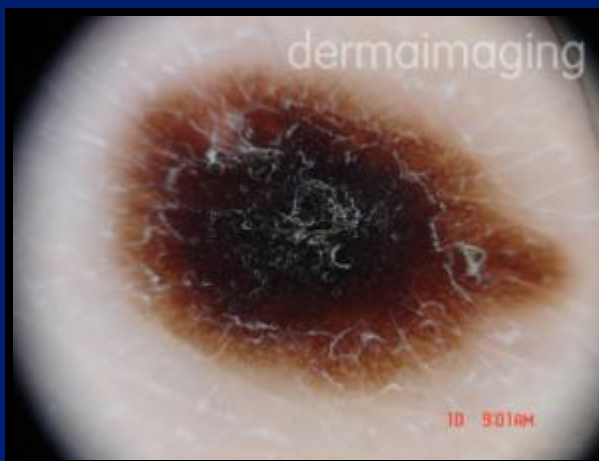
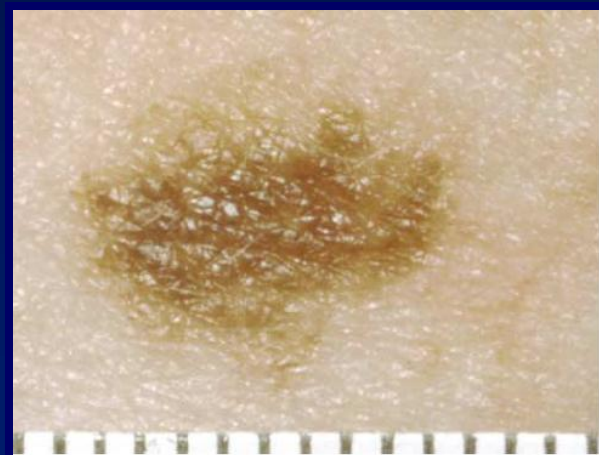
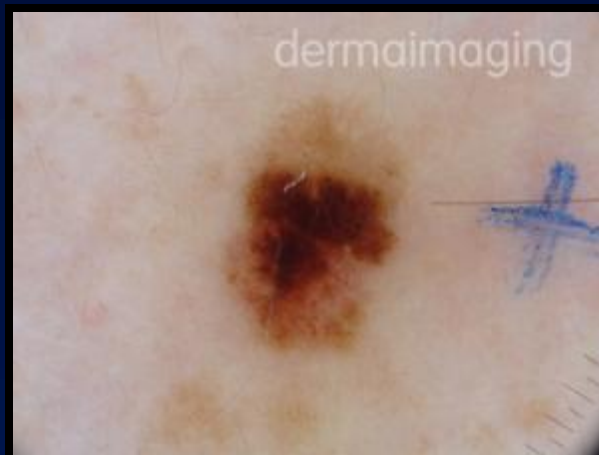C. Color One shade

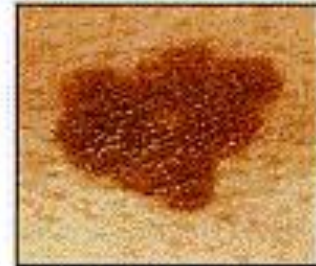

D. Diameter Smaller than 6 mm

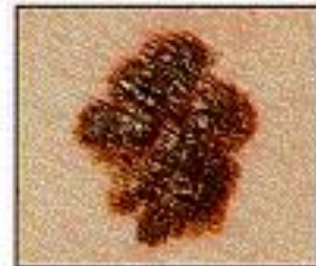dermaimaging



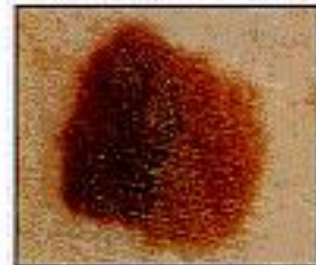Malignant



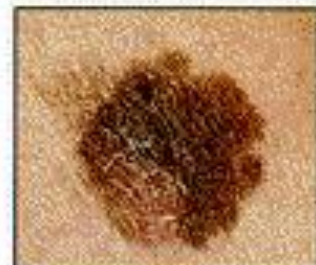A. Asymmetry Asymmetrical



B. Border Uneven edges



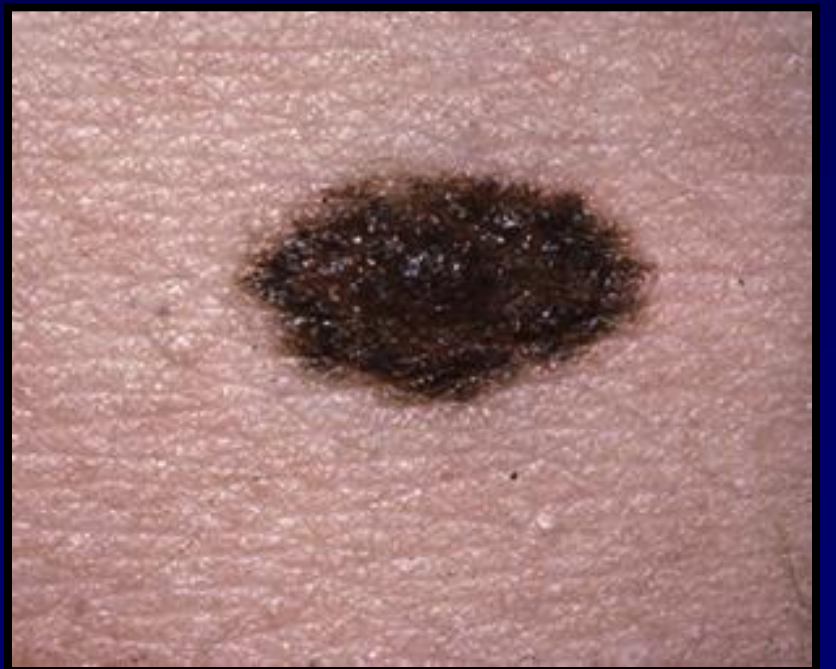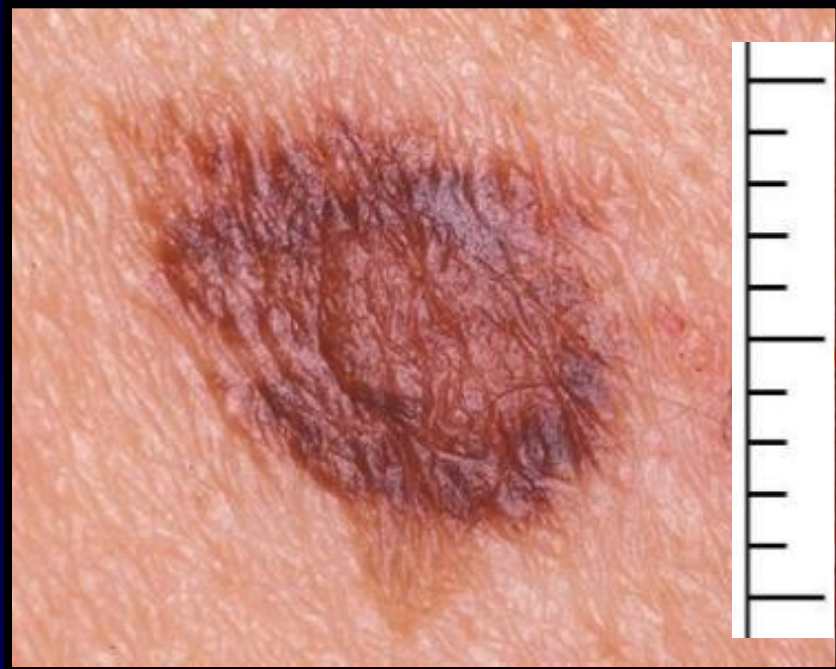
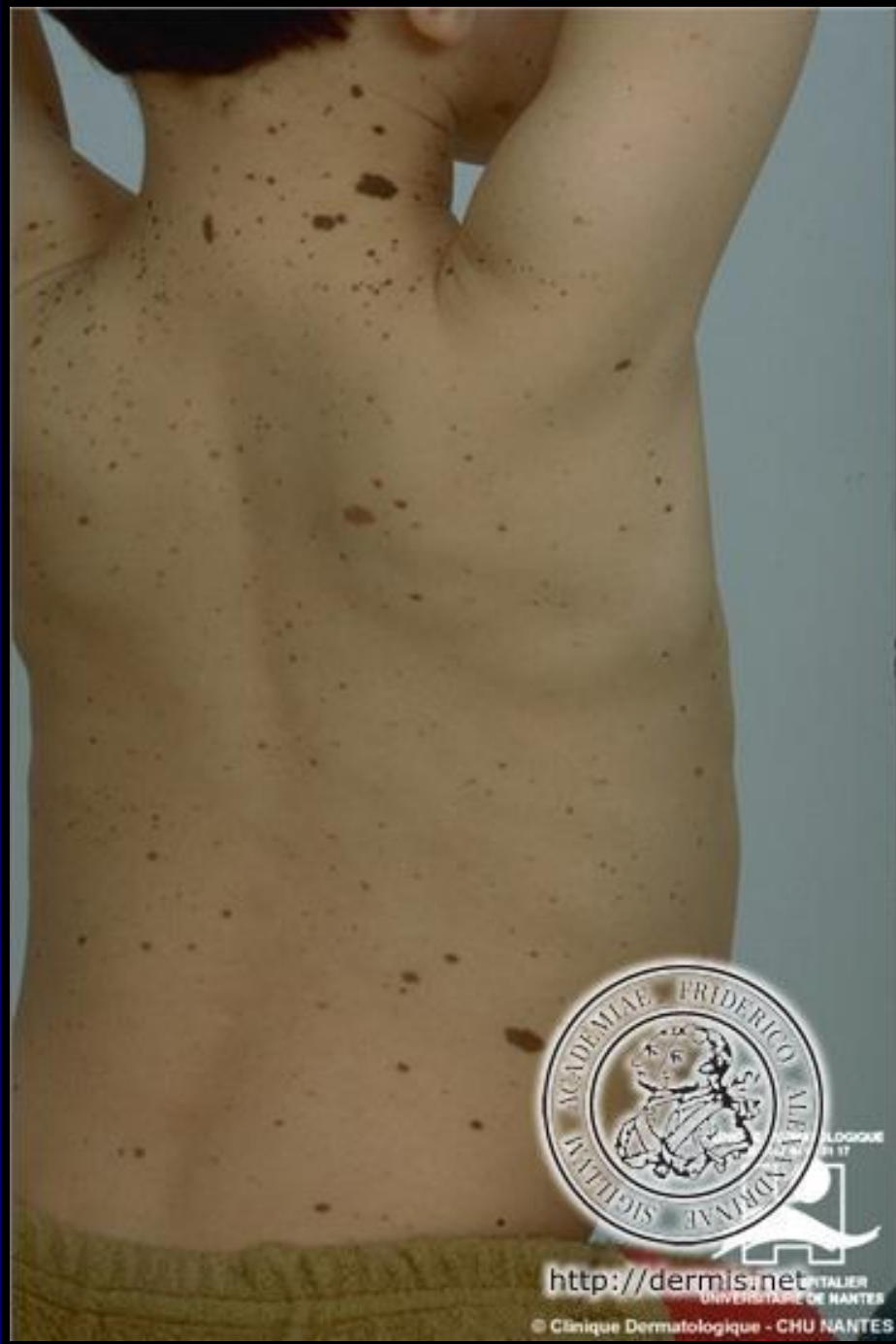C. Color Two or more shades



D. Diameter Larger than 6 mm

dermimaging

10 901AM



REVIEW ARTICLE

State of the Art, Nomenclature, and Points of Consensus and Controversy Concerning Benign Melanocytic Lesions: Outcome of an International Workshop

Raymond L. Barnhill, MD, Lorenzo Cerroni, MD,† Martin Cook, MD,‡ David E. Elder, MD,§ Helmut Kerl, MD,† Philip E. LeBoit, MD,|| Stanley W. McCarthy, MD,¶ Martin C. Mihm, MD,# Wolter J. Mooi, MD,** Michael W. Piepkorn, MD, PhD, †† Victor G. Prieto, MD, PhD,‡‡ and Richard A. Scolyer, MD¶*

TABLE 1. Classification of Benign Melanocytic Nevi

Common acquired nevi
Atypical (“dysplastic”) melanocytic nevi
Congenital melanocytic nevi
Spitz nevi and related lesions
Blue nevi and related lesions
Combined nevi (melanocytic nevi with phenotypic heterogeneity) and related lesions

TABLE 2. Common Acquired Melanocytic Nevi

Junctional nevus, not otherwise specified
Compound nevus, not otherwise specified
Dermal nevus, not otherwise specified
Halo melanocytic nevus
Recurrent melanocytic nevus
Balloon cell nevus
Nevus spilus
Melanocytic nevi from particular anatomic sites

Atypical or “Dysplastic” melanocytic Nevi

- Case-control studies show a positive, near-linear relationship between # of nevi and life time RR of melanoma
- Clinical dysplastic nevus constitute risk indicators for melanoma
- Histologic dysplastic nevus as a precursor lesion of melanoma is significantly contentious

Dysplastic Nevi and Melanoma risk

- Currently melanoma risk of patients is clinically established via
 - Total number of nevi
 - Presence and number of atypical nevi
 - Personal / family history of melanoma

ORIGINAL ARTICLE

BRAF mutational epidemiology in dysplastic nevi: Does different solar UV radiation exposure matter?

M. Saroufim,¹ M. Novy,² S. Taraif,³ R.H. Habib,⁴ A. Loya,⁵ B. Rauscher,² G. Kriegshäuser,² C. Oberkanins,² I. Khalifeh^{1,*}

¹Department of Pathology, American University of Beirut Medical Center, Beirut, Lebanon

²ViennaLab Diagnostics GmbH, Vienna, Austria

³Saad Specialist Hospital, AlKhobar, Kingdom of Saudi Arabia

⁴Department of Internal Medicine, Outcomes Research Unit, American University of Beirut Medical Center, Beirut, Lebanon

⁵Shaukat Khanum Memorial Center, Lahore, Pakistan

*Correspondence: Ibrahim Khalifeh. E-mail: ik08@aub.edu.lb

Abstract

Background Proto-oncogene B-Raf (BRAF) mutation rates have been reported in nevi and melanomas of homogeneous Caucasian cohorts.

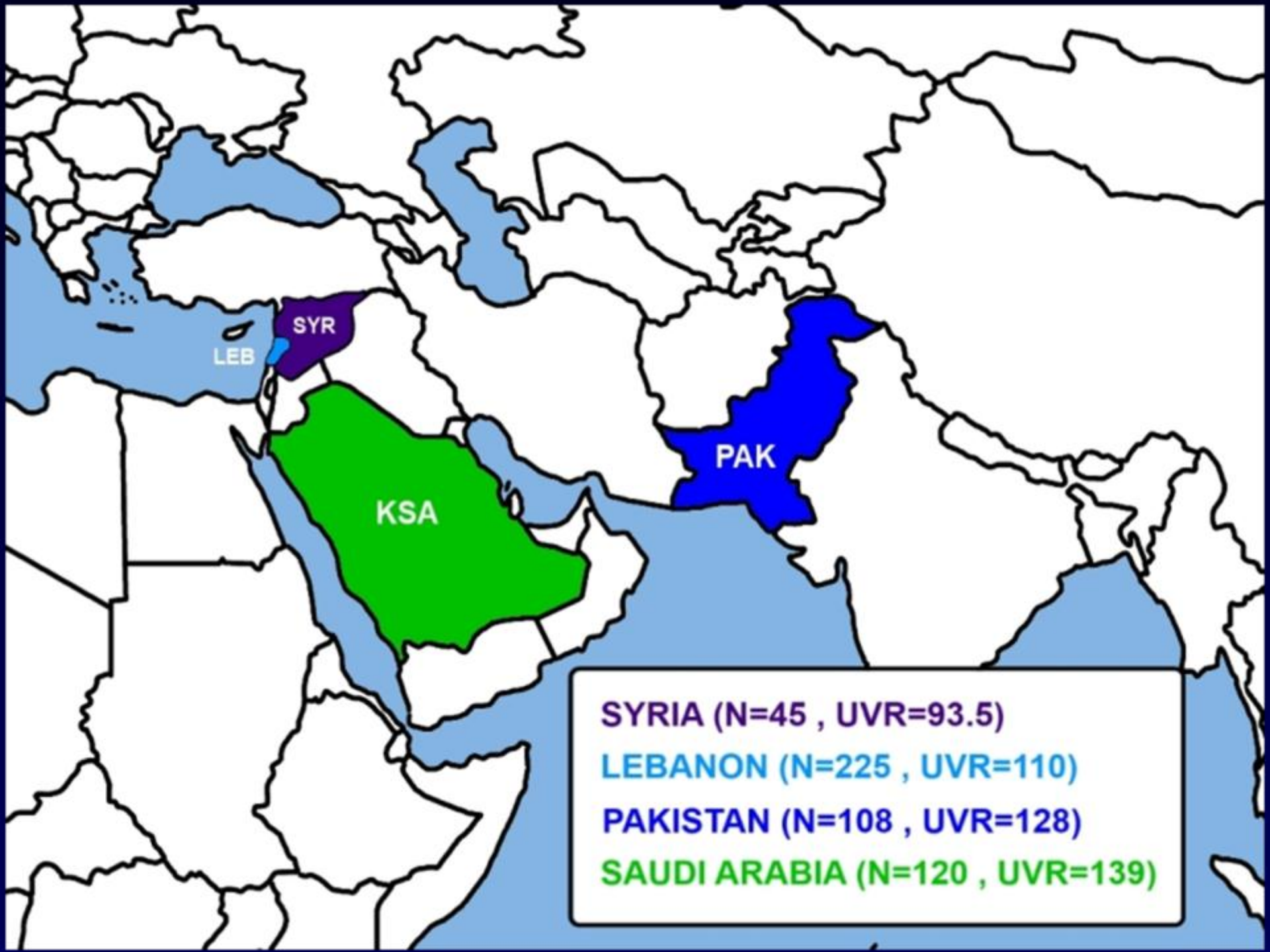
Objective To study the demographics of BRAF mutations in dysplastic nevi of populations with differing potential solar UV radiation exposure.

Methods Extended BRAF testing for 9 mutations in 125 dysplastic nevi from 101 patients, derived from populations with differing potential UV radiation exposure rates (Lebanon and Saudi Arabia), was performed. Clinical and microscopic parameters were recorded.

Results BRAF mutation status was carried out for 101/125 (80.8%) cases with an overall mutation rate of 62.4% (63/101). V600E (c.1799T > A) was the predominant mutation, found in 61/63 (96.8%) cases. BRAF mutation rate differed significantly by potential UV radiation exposure (Lebanon: 53.4%, Saudi Arabia: 74.4%, $P < 0.05$). A 43.8% discordant mutation rate (7/16 patients) was found in patients with multiple nevi, including 2 patients with different BRAF mutations. Microscopic examination subdivided the dysplasia into mild ($n = 24$), moderate ($n = 60$) and severe ($n = 41$) with trunk predominance (72.8%). Higher rates of pigment in the stratum corneum were identified in Saudi Arabia ($P < 0.05$). No statistical significant increase in BRAF mutation rate was noted with advanced architectural and cytological atypia. Parameters associated with a negative BRAF mutation status included upper extremity location, regression, cohesiveness and presence of suprabasal melanocytes ($P < 0.05$). Positive BRAF mutation status was reasonably predicted by multivariate binary logistic regression by 2 independent predictors: Geographic location and compound nevus type.

Conclusions In our Near Eastern cohort, the BRAF mutation rate varied significantly by geographic location. In patients with multiple dysplastic nevi examined, discordant BRAF mutation status potentially negates an underlying constitutional predilection.

Received: 3 November 2012; Accepted: 21 February 2013



SYRIA (N=45 , UVR=93.5)

LEBANON (N=225 , UVR=110)

PAKISTAN (N=108 , UVR=128)

SAUDI ARABIA (N=120 , UVR=139)

Histologic Grade of DN	Near East Cohort	Caucasian Cohort *
Low	19% (48 cases)	56%
Moderate	48 % (120 cases)	37 %
High	33% (82 cases)	7%

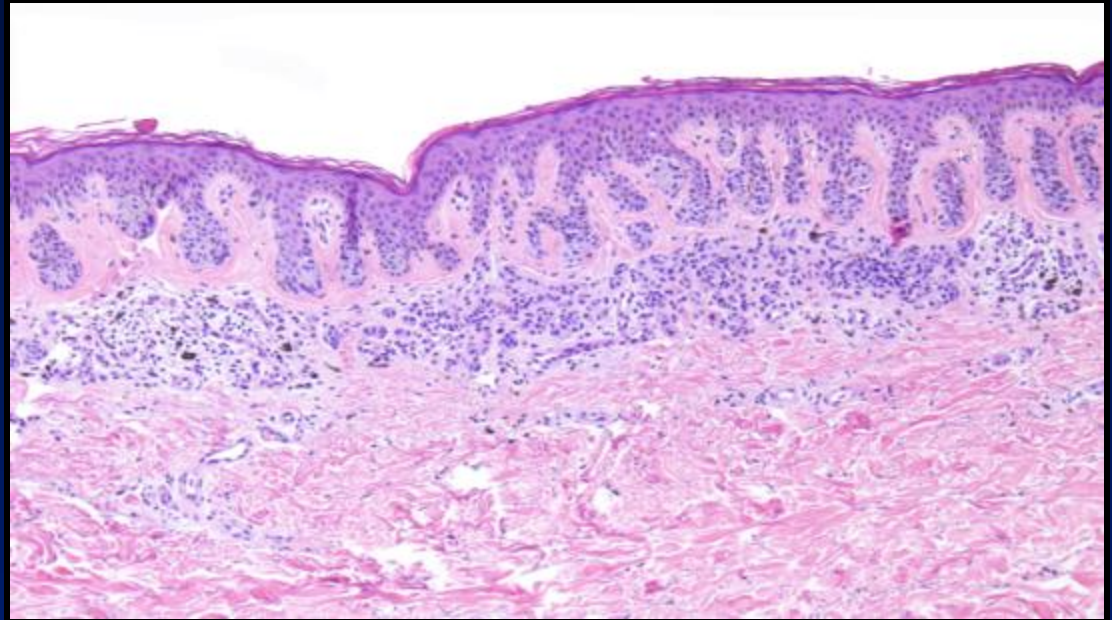
* Arumi-Uria M, et. al., Mod Pathol. 2003 Aug;16(8):764-71

Epidemiology

- Erythemally effective UV irradiance for each city averaged over the 21-year period was as follows (1979-2000):
 - Al-Khobar, Saudi Arabia: UVR= 139 J/m²/year
 - Lahore, Pakistan: UVR= 118 kJ/m²/year
 - Beirut, Lebanon: UVR= 110 kJ/m²/year
 - Lattakia, Syria: UVR= 93.5 kJ/m²/year
- Architectural and cytological grade did not vary significantly or systemically based on UVR ($p>0.05$).

Histology

- **Scanning (20x) magnification**
 - **Shoulder**
 - **Stromal response with fibrosis and inflammation**

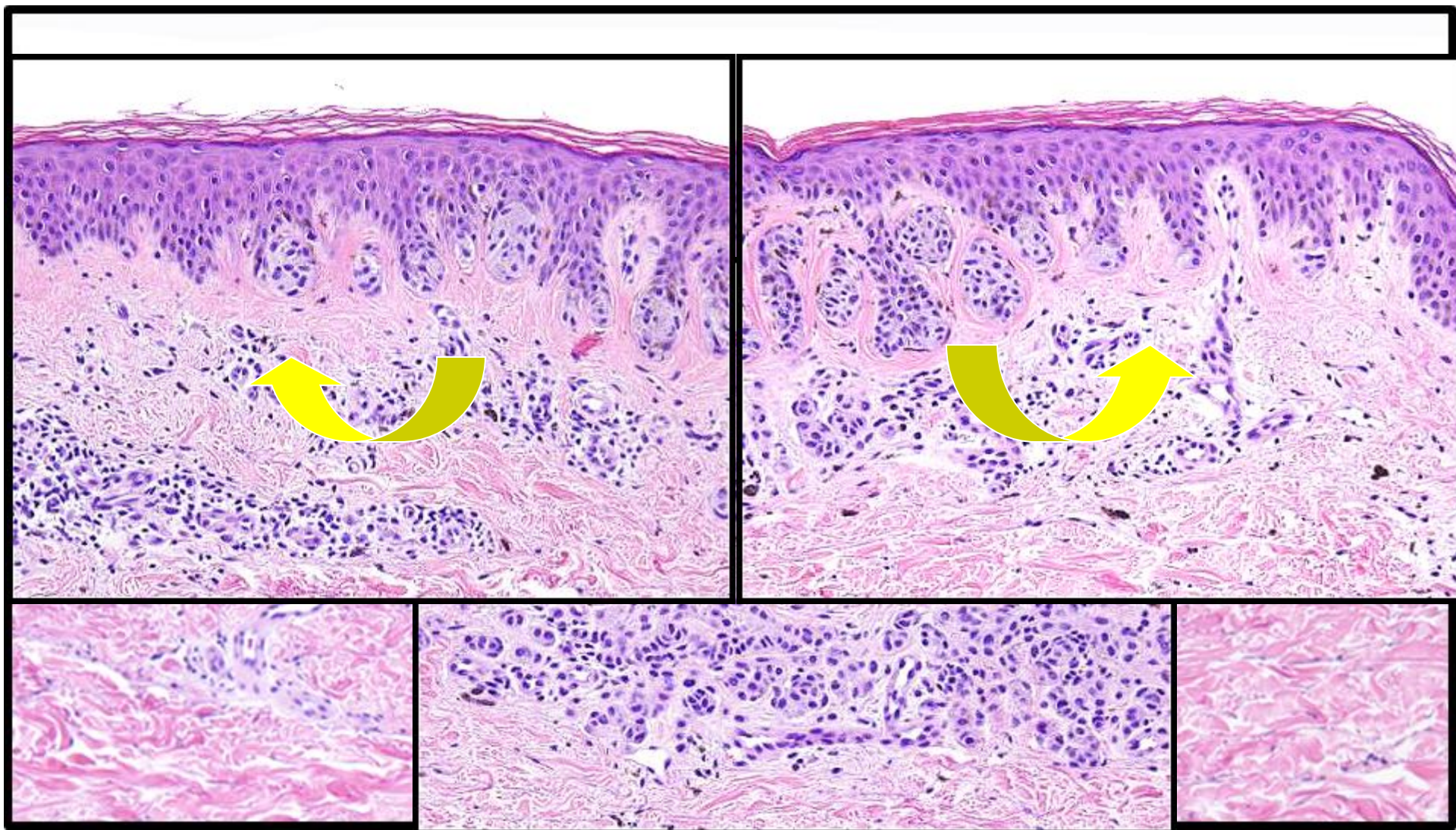


Histology

- **Architectural disorder:**
 - **Circumscription:** Junctional component nested at both edges vs. single-cell in at least one edge
 - **Symmetrical:** Good overall symmetry regarding edges, size of junctional nests, and stromal response
 - **Cohesiveness of nests:** >50% of nests cohesive
 - **Pagetoid spread:** prominent, at periphery
 - **Confluent growth:** in >50% of the junctional melanocytic proliferation, either as bridging of melanocytic nests or as contiguous single cells
 - **Single cell proliferation:** Junctional melanocytes arranged as single cells in more than 20% of the lesion
- **Sum**
 - **Mild: 0-1**
 - **Moderate: 2-3**
 - **Severe: 4-6**

Histology

- **Cytologic atypia**
 - **Nuclear shape and staining** round-oval & euchromatic
 - **Nuclear size** > basal-layer keratinocyte nuclei
 - **Nucleoli** prominent > 50% of cells
 - **Cell diameter** >2x basal-layer keratinocyte nuclei
- **Sum**
 - **Mild: 0-1**
 - **Moderate: 2**
 - **Severe: 3-4**



Architecture

Circum: 0

Symmetrical: 0

Cohesiveness: 1

Pagetoid: 0

Confluent: 0

Single C.P.: 0

Mild/Mild

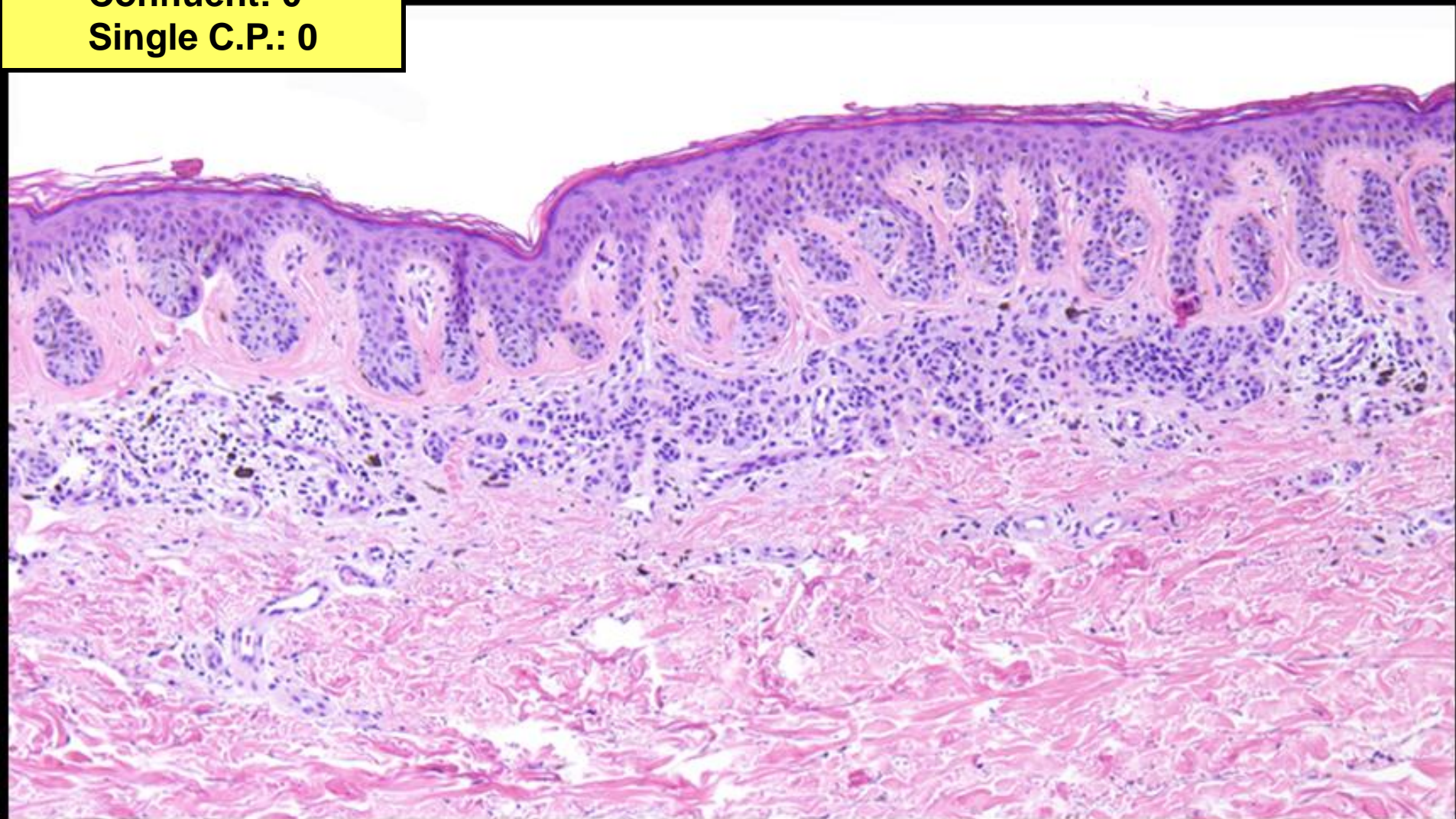
Cytology

Nuclei:0

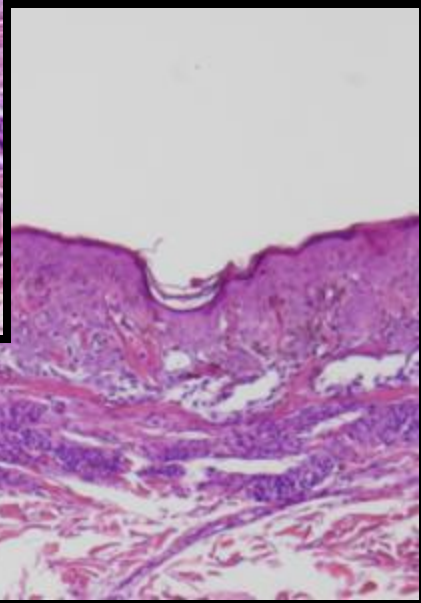
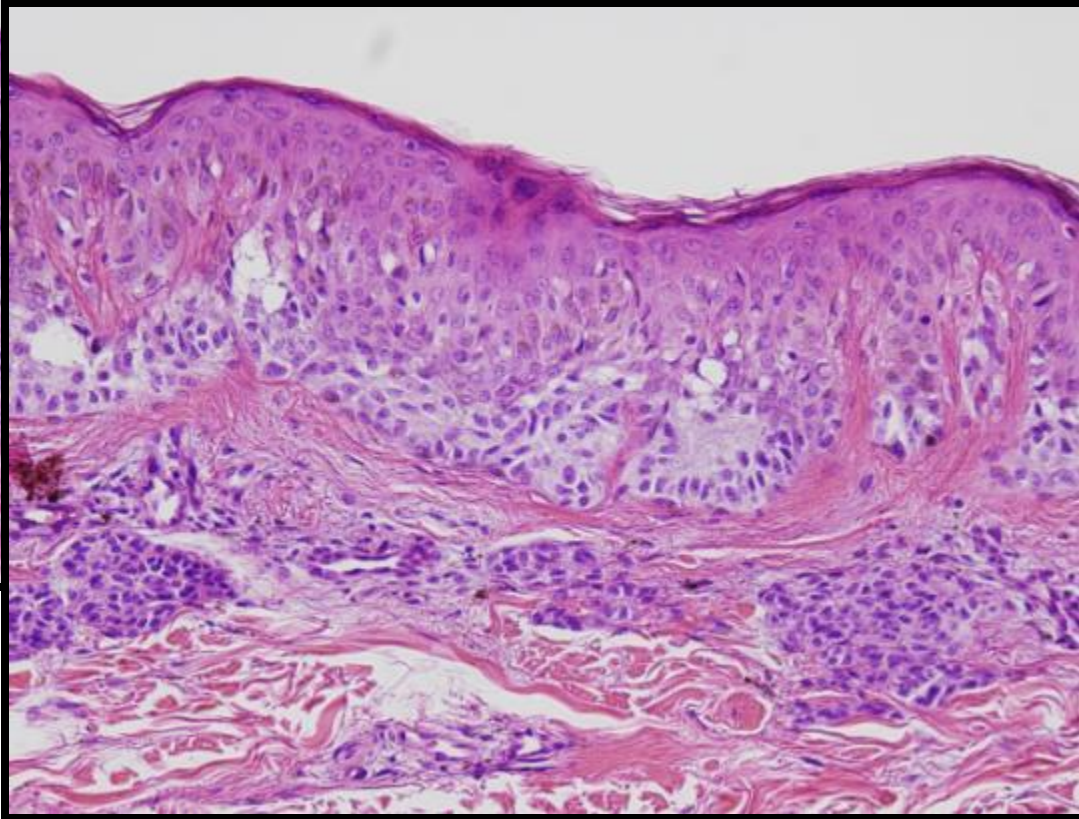
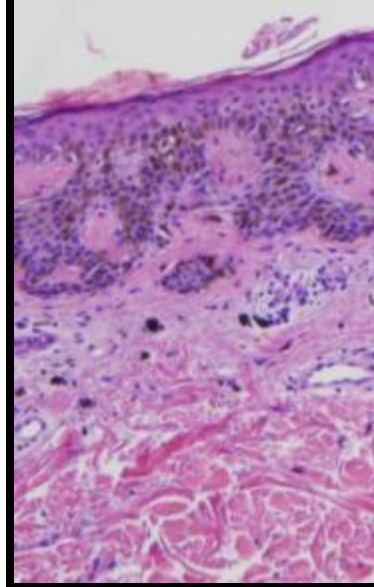

Nuclear size:0

Nucleoli: 0

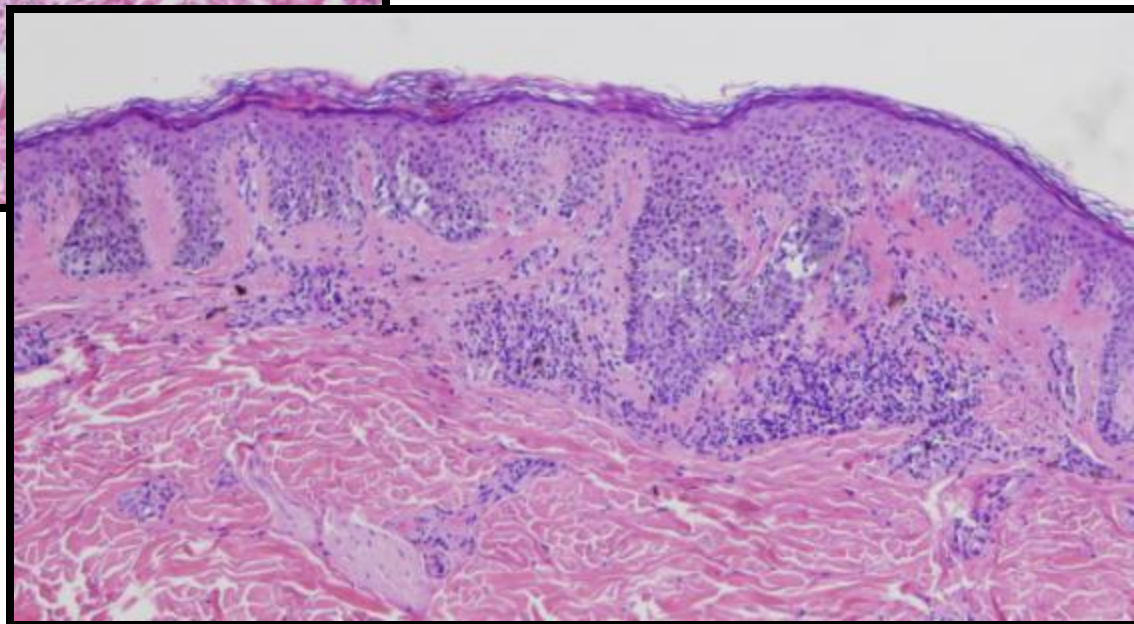
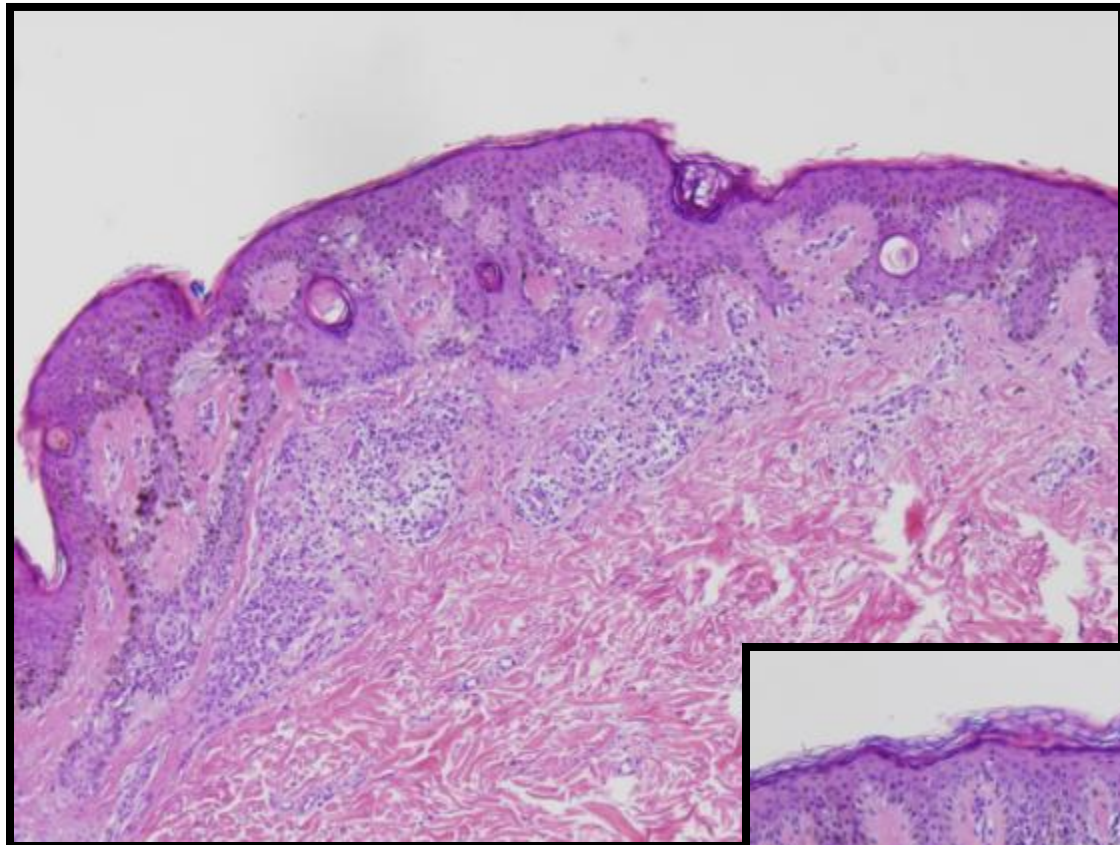
Cell diam:1

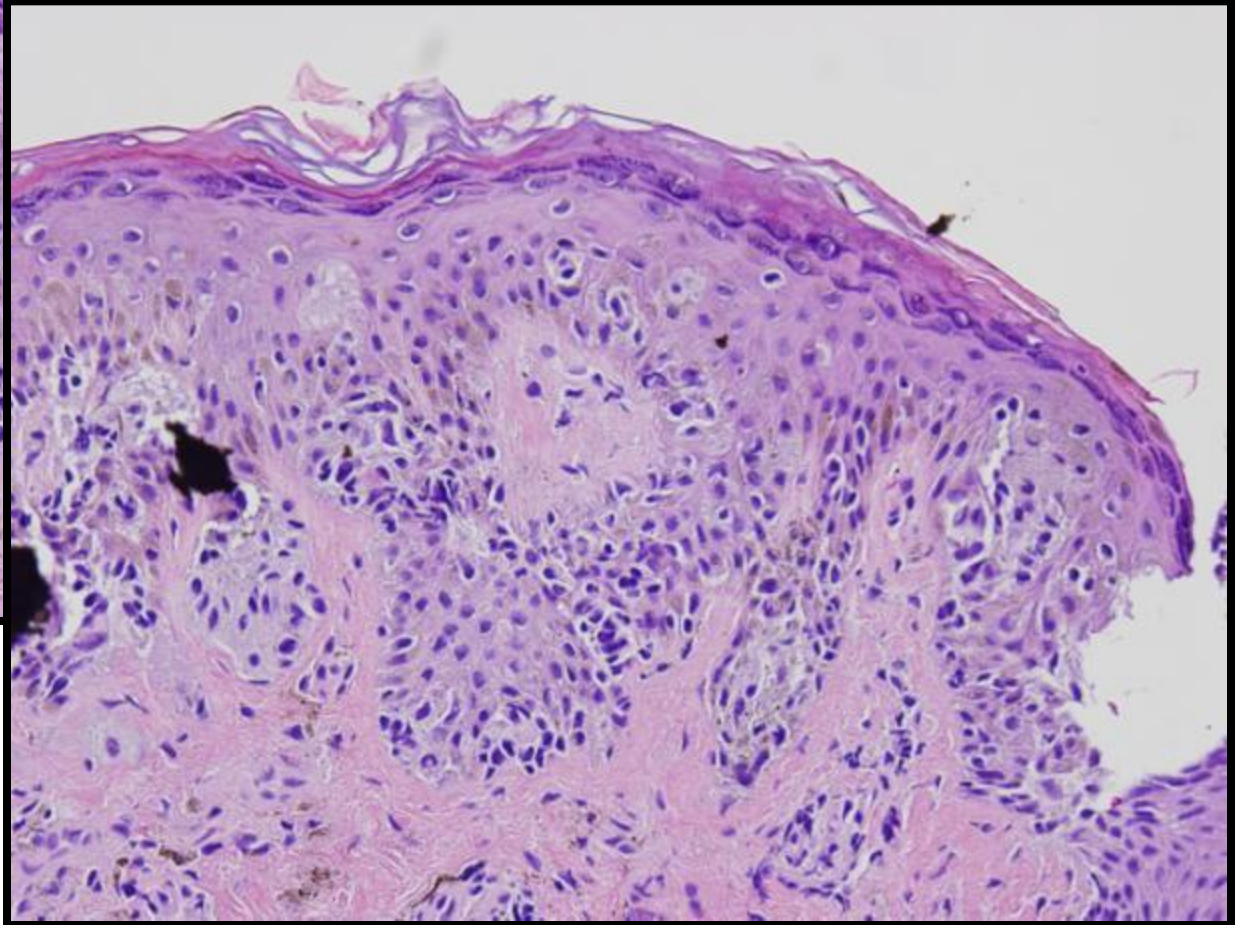
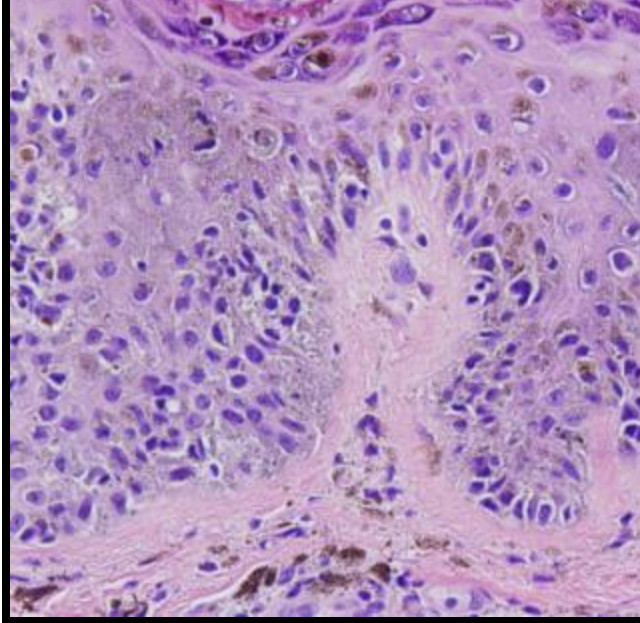
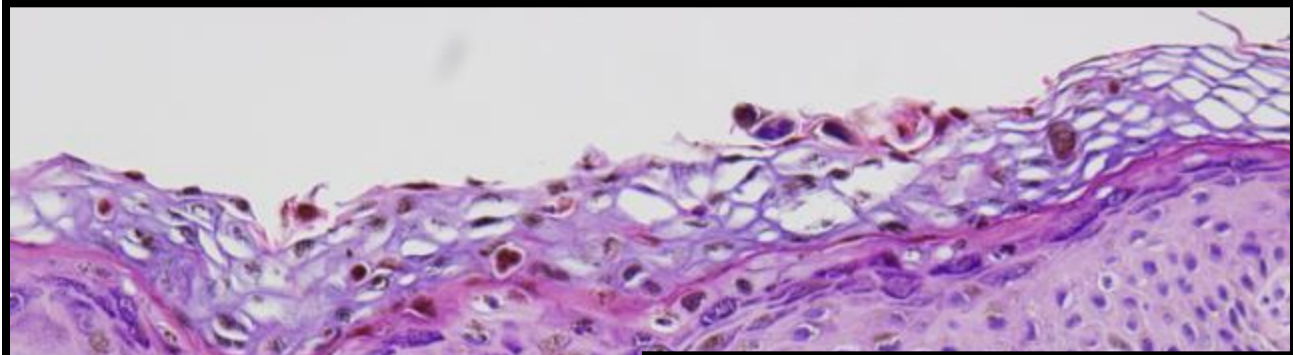


Moderate/Moderate

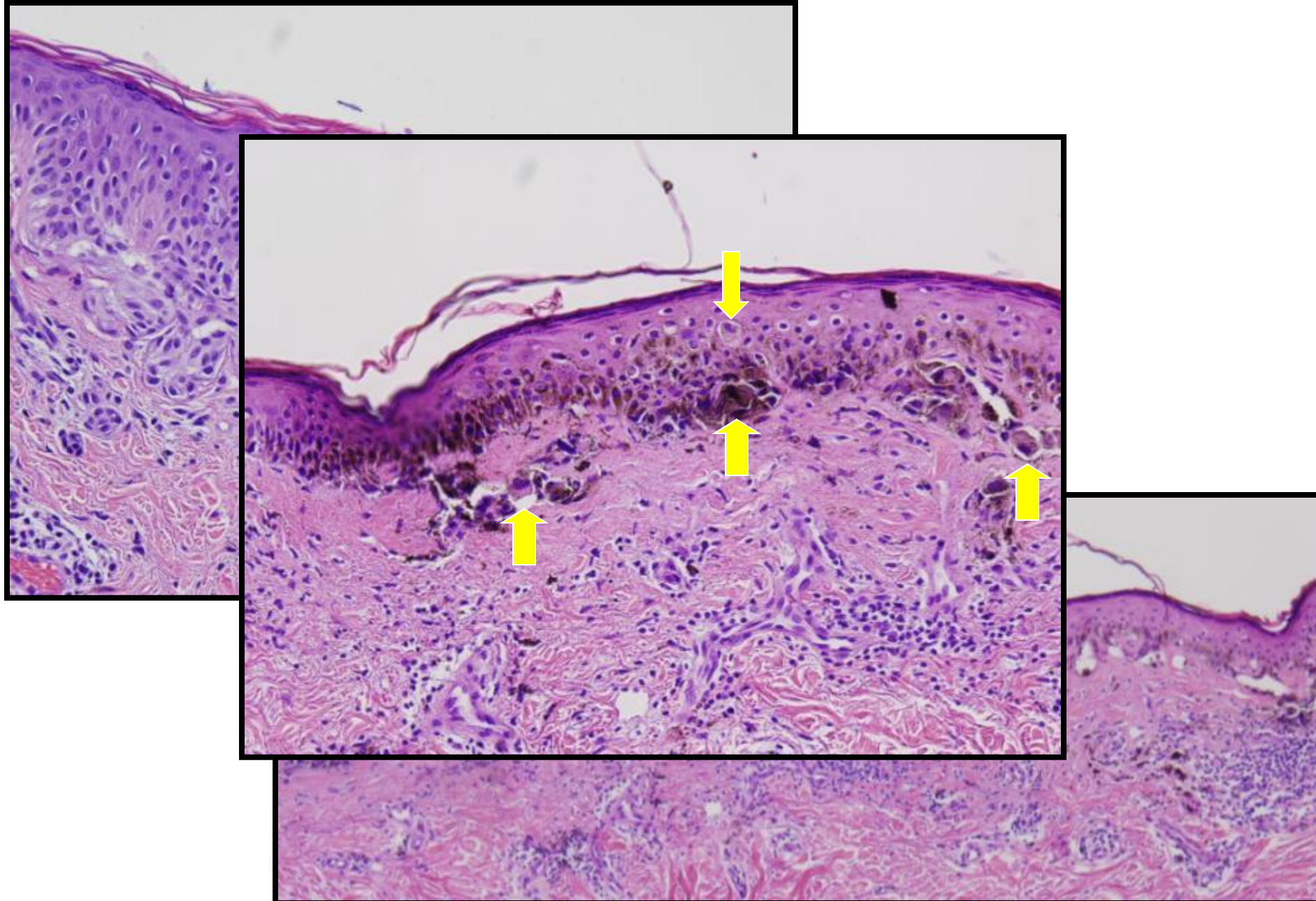


Severe/Severe





Severe/Severe

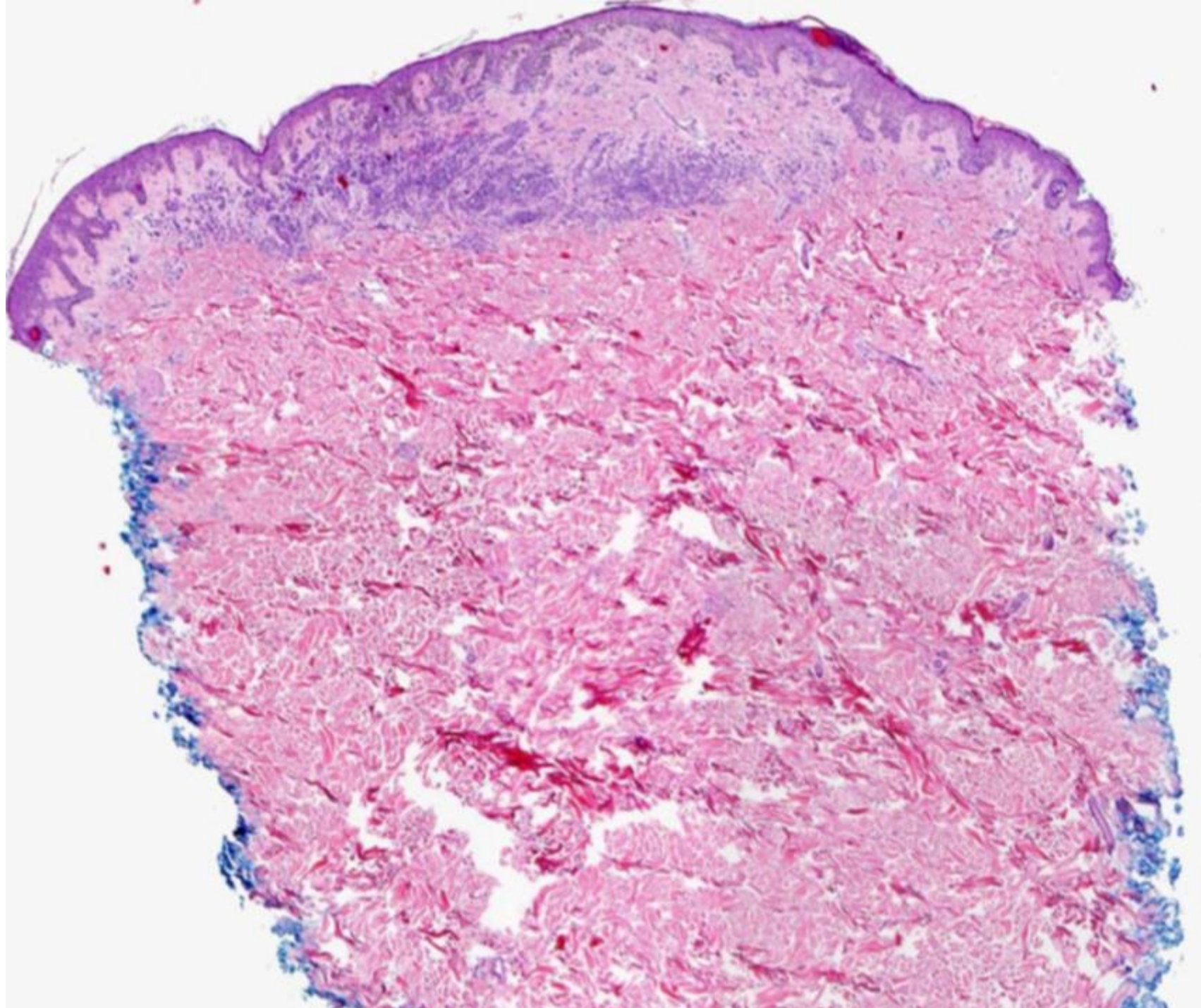


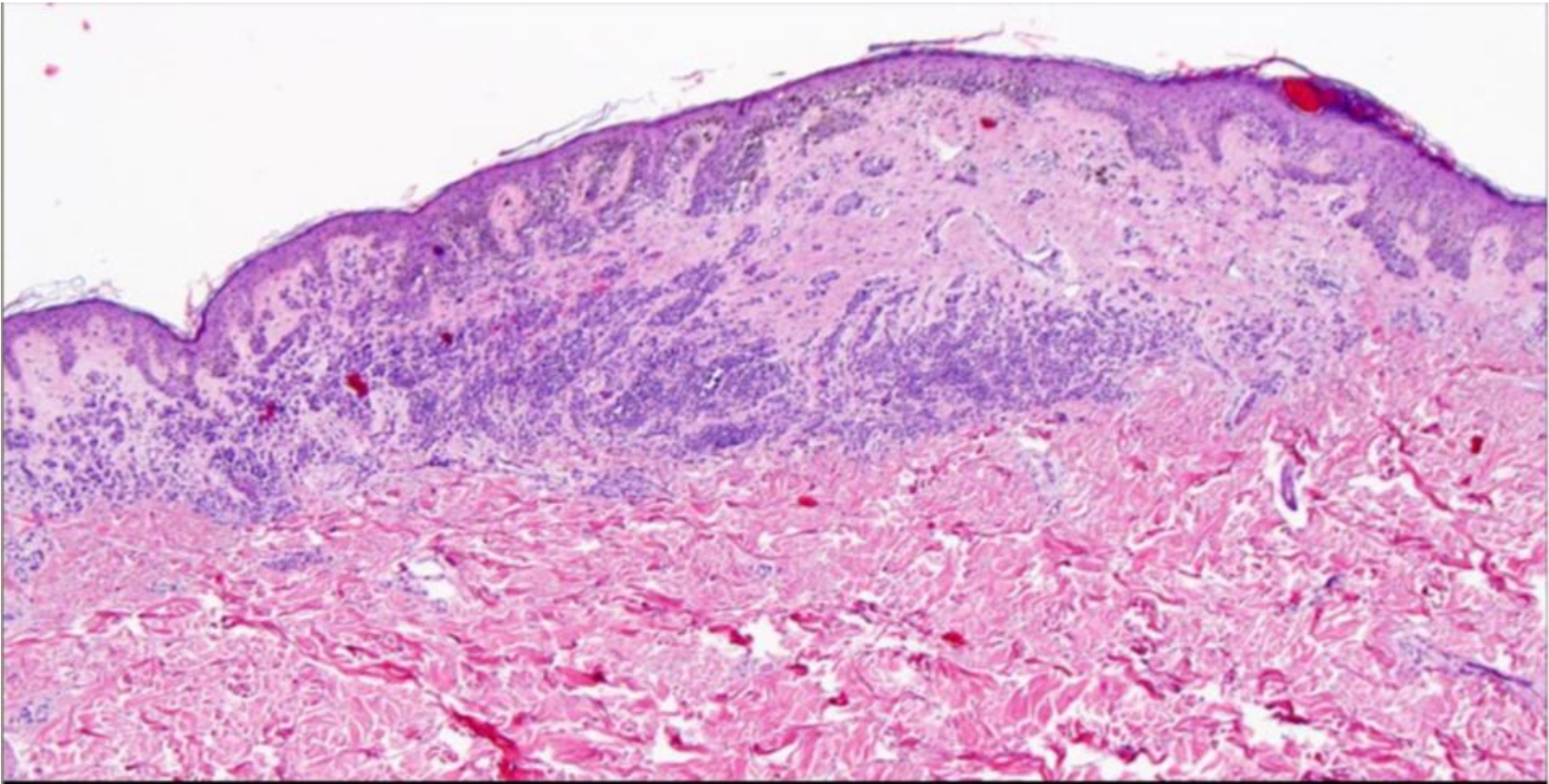
Take-Home Message

- DN are significant:
 - simulants of melanoma
 - a marker of individual at risk
 - ? occasionally precursors of melanoma
- Individuals with one or few DN and without other risk factors may be followed less intensely
- DN morphologically and biologically intermediate between common nevi and melanoma

Case 4

- **35 yo female**
- **Lesion of central back**
- **Clin Dx: Rule out malignant melanoma**





Epidermal hyperpigmentation, trizonal architecture

Trizonal pattern:

1

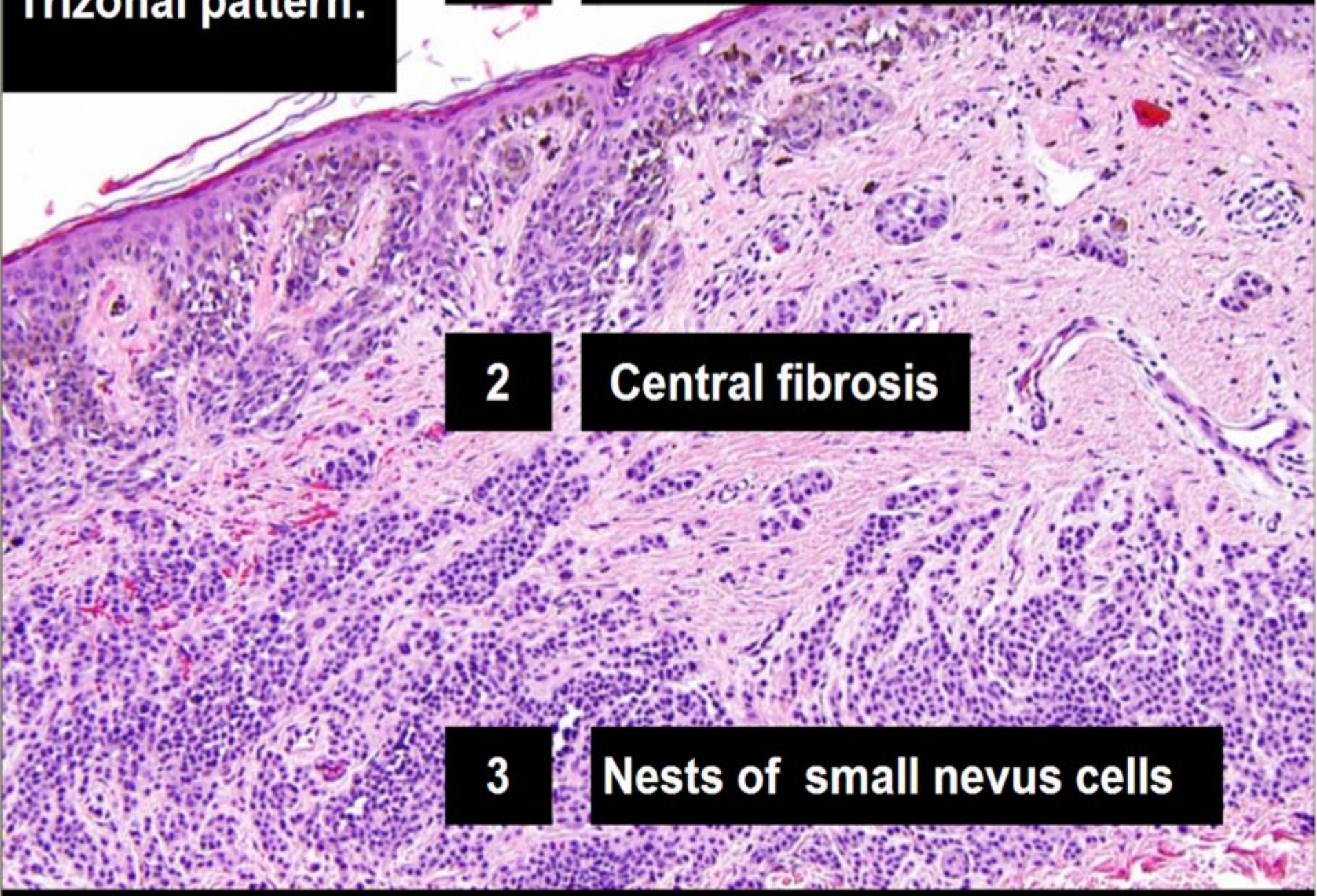
Confluent junctional component

2

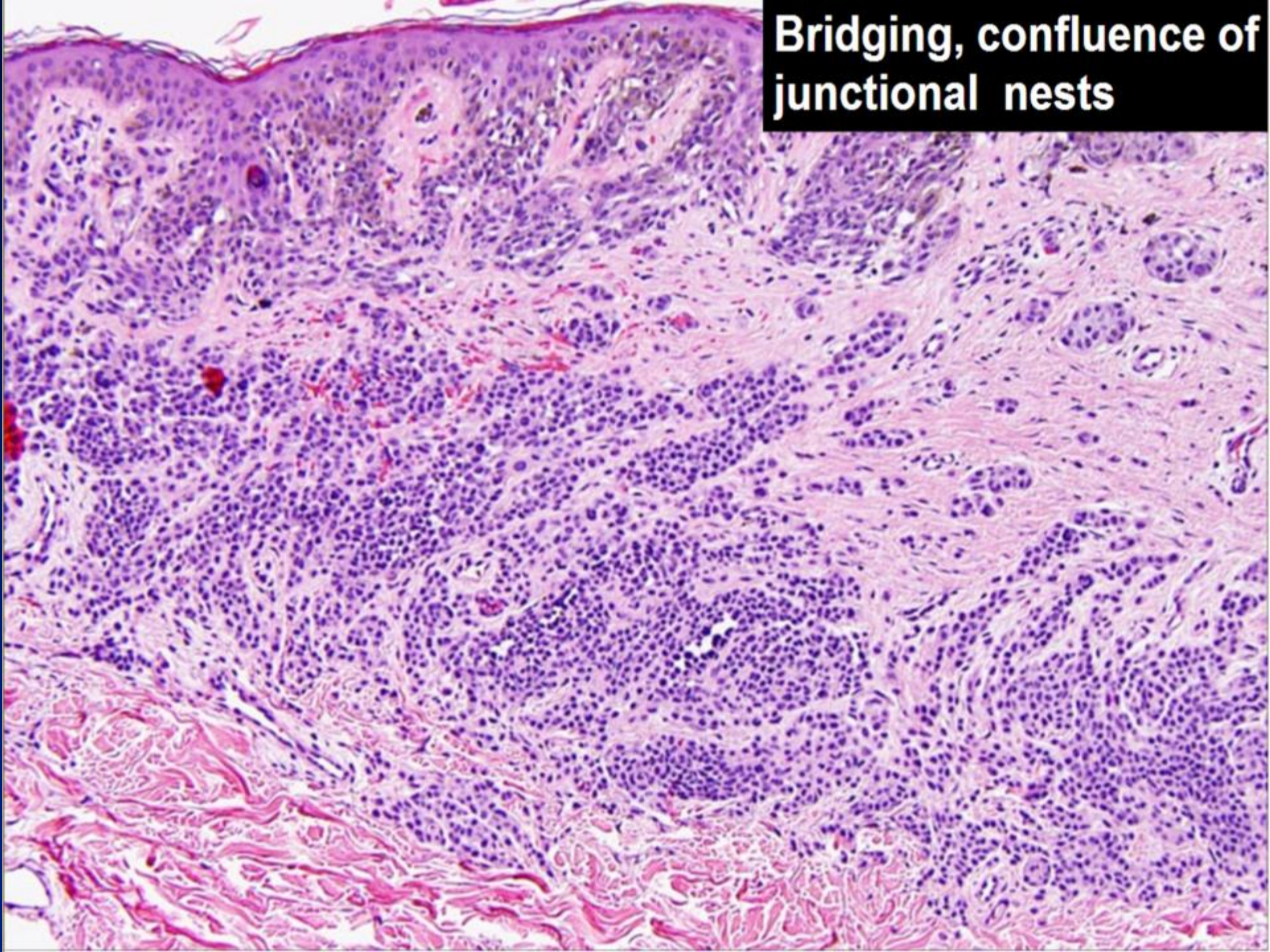
Central fibrosis

3

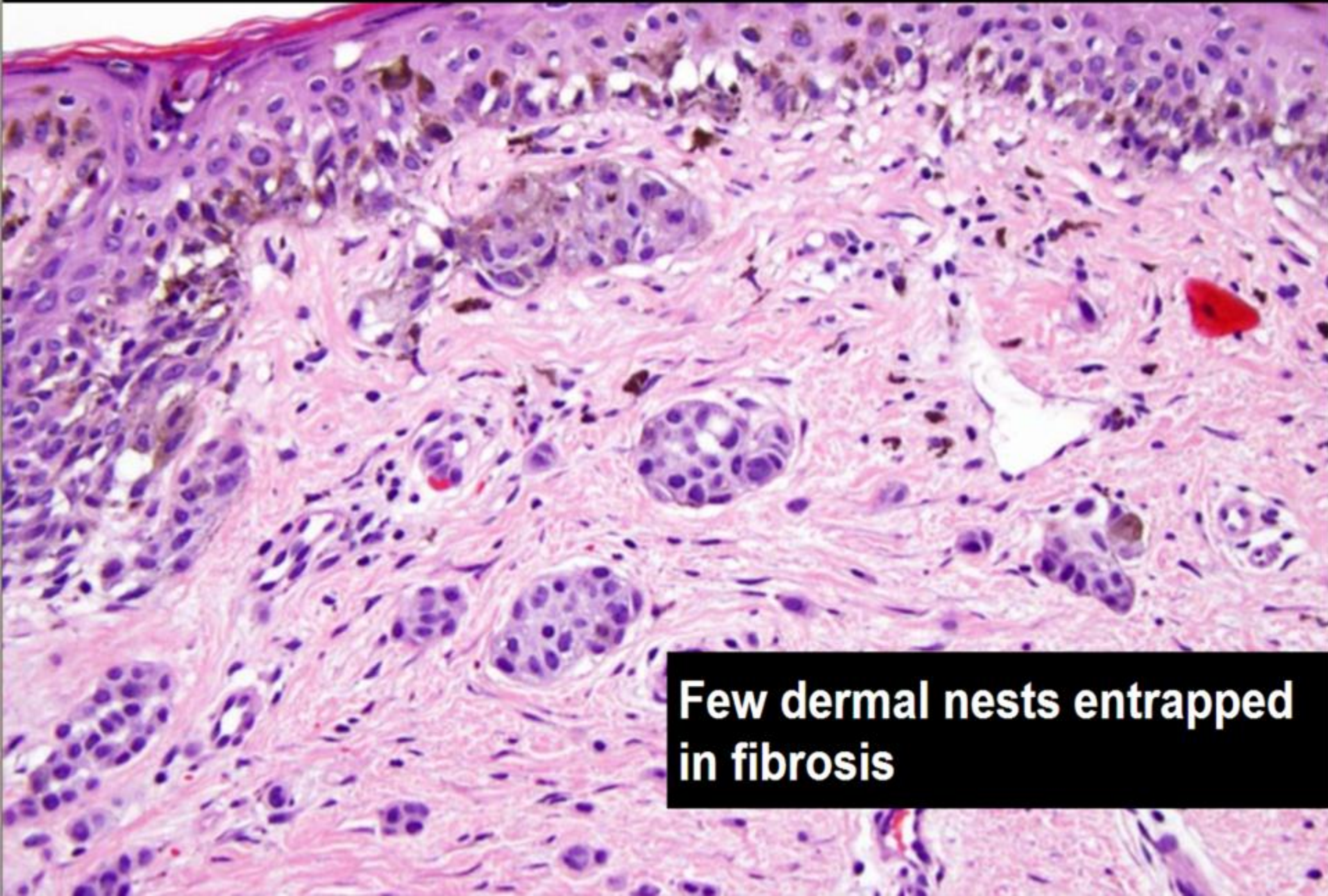Nests of small nevus cells



**Bridging, confluence of
junctional nests**

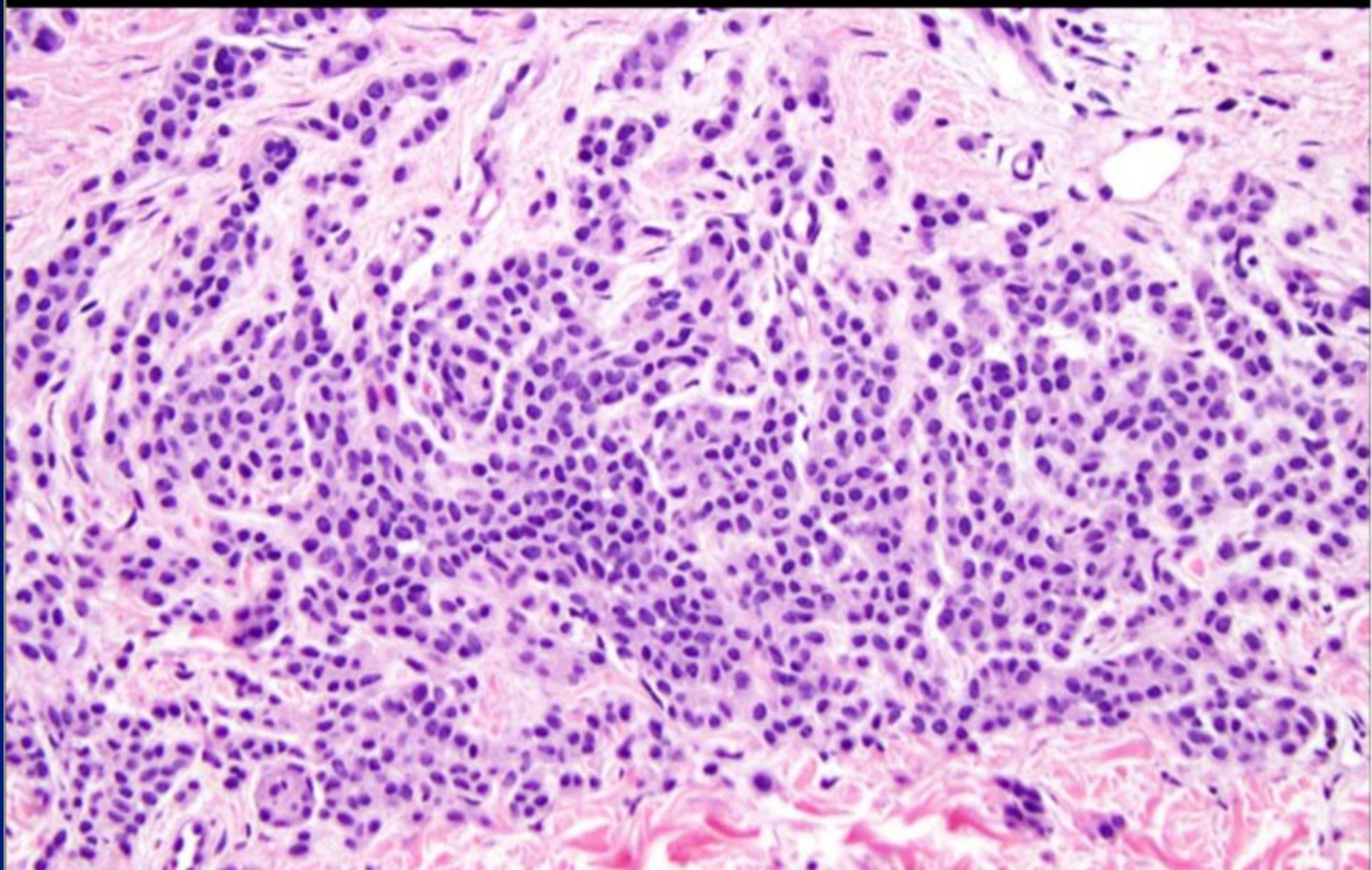


Single and nested melanocytes with hyperchromatic nuclei



Few dermal nests entrapped
in fibrosis

Deep dermal component of small cells lacking atypia



What Is Your Diagnosis?

- A.** Melanoma Associated with dermal melanocytic nevus.
- B.** Dysplastic melanocytic nevus with regression.
- C.** Recurrent/ persistent compound melanocytic nevus.

What Is Your Diagnosis?

- A.** Melanoma Associated with dermal melanocytic nevus.
- B.** Dysplastic melanocytic nevus with regression.
- C.** Recurrent/ persistent compound melanocytic nevus.

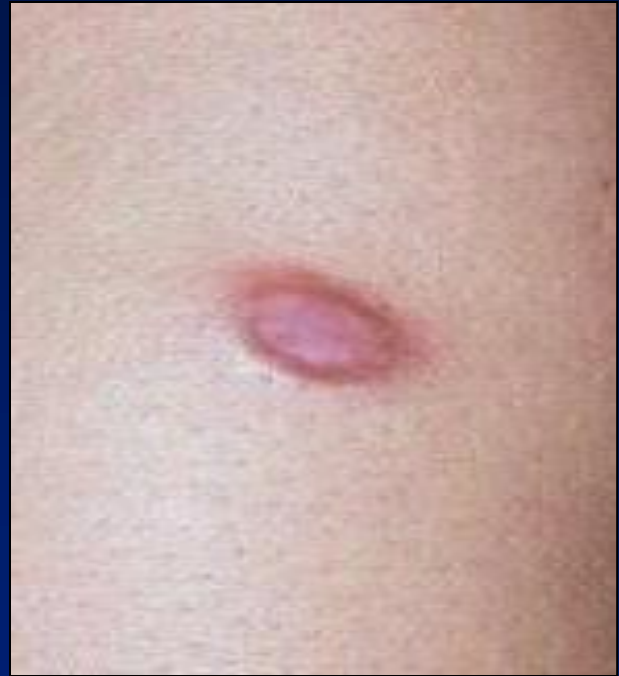Histologic Features

- Compound melanocytic lesion
- Trizonal pattern
- Central dermal fibrosis
- Architectural disorder and cytologic atypia of junctional component
- Benign-appearing deep dermal component

Case 5

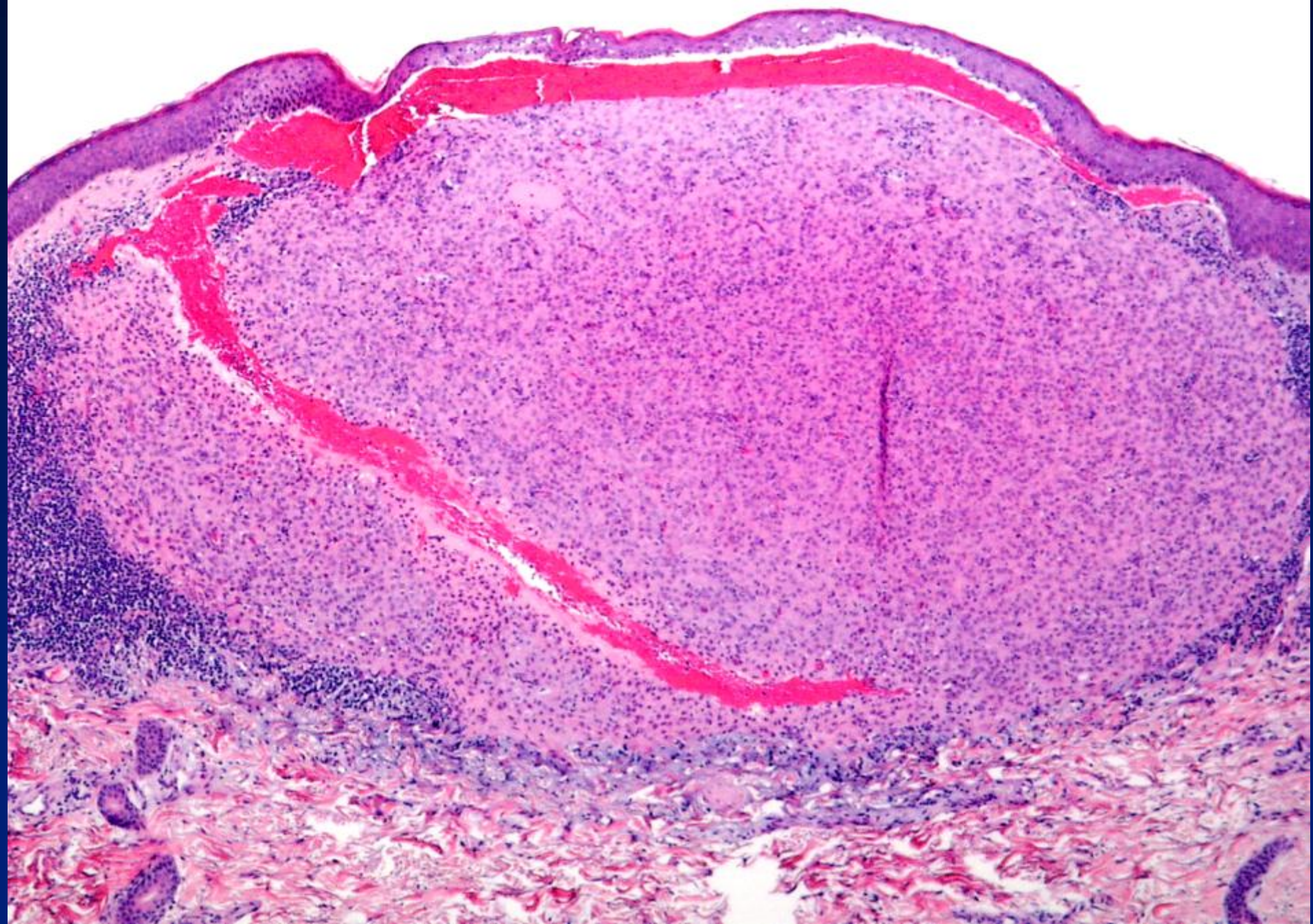Clinical Data

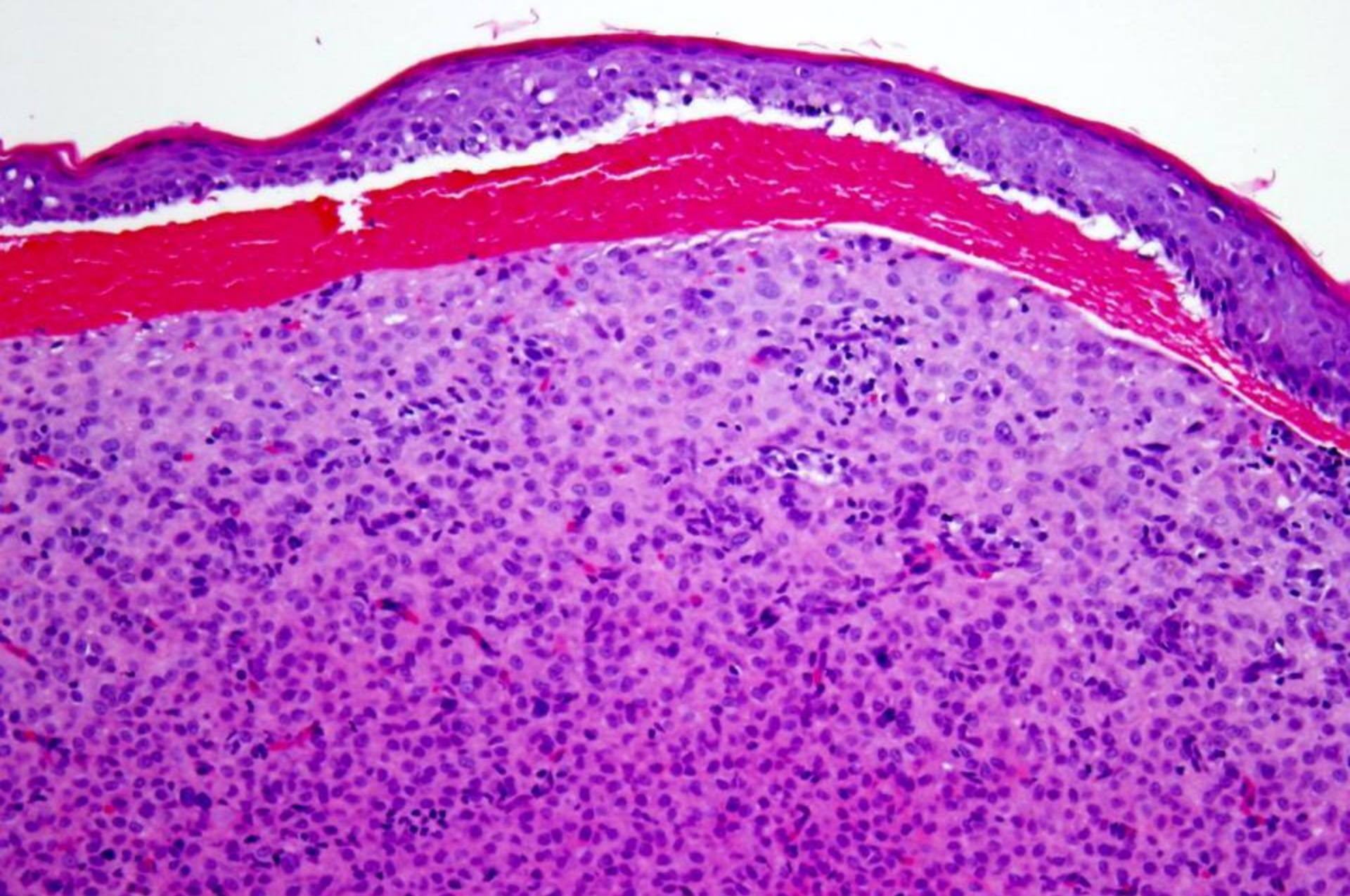
- 38-year-old male with nodule on right calf

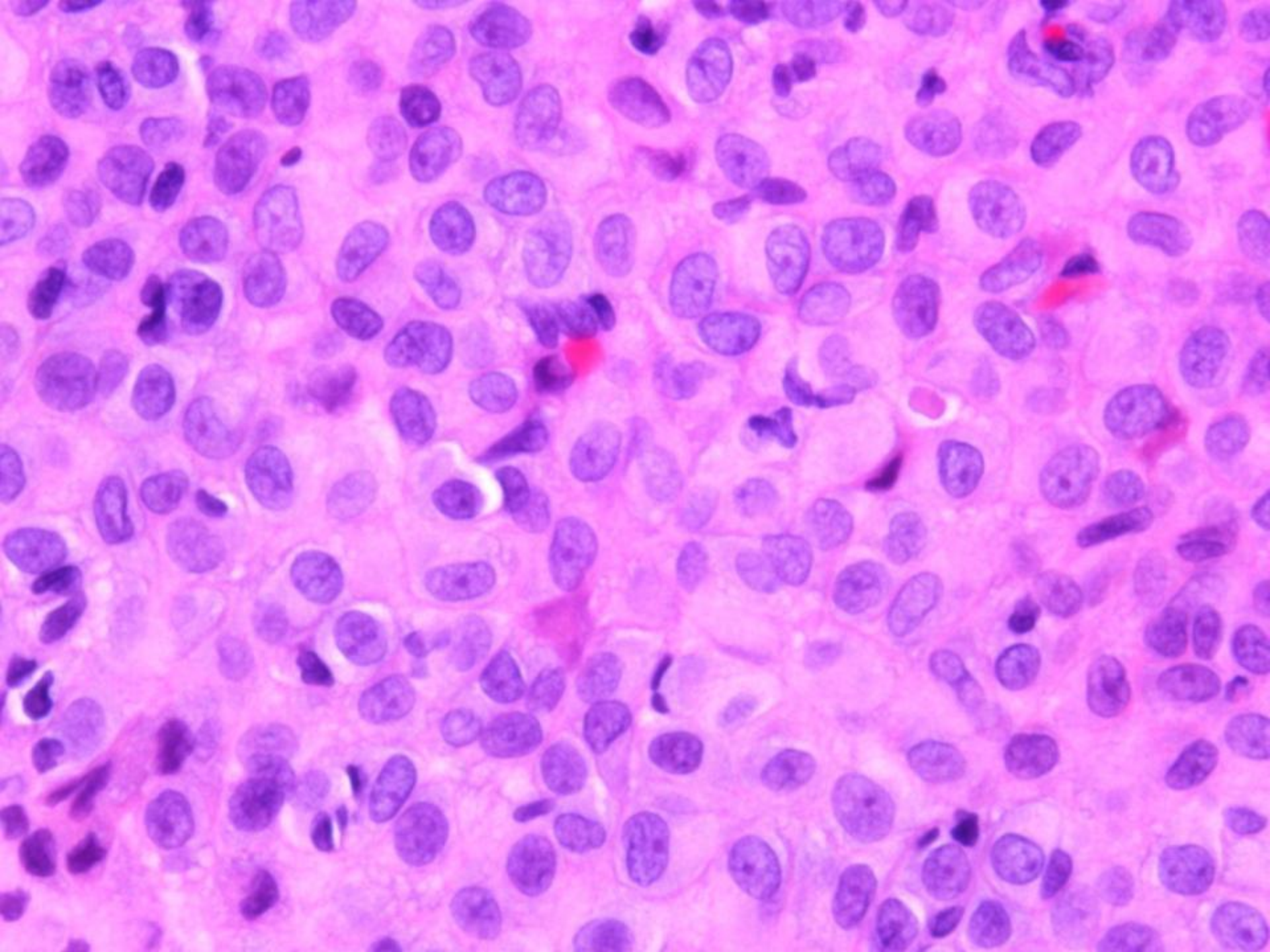


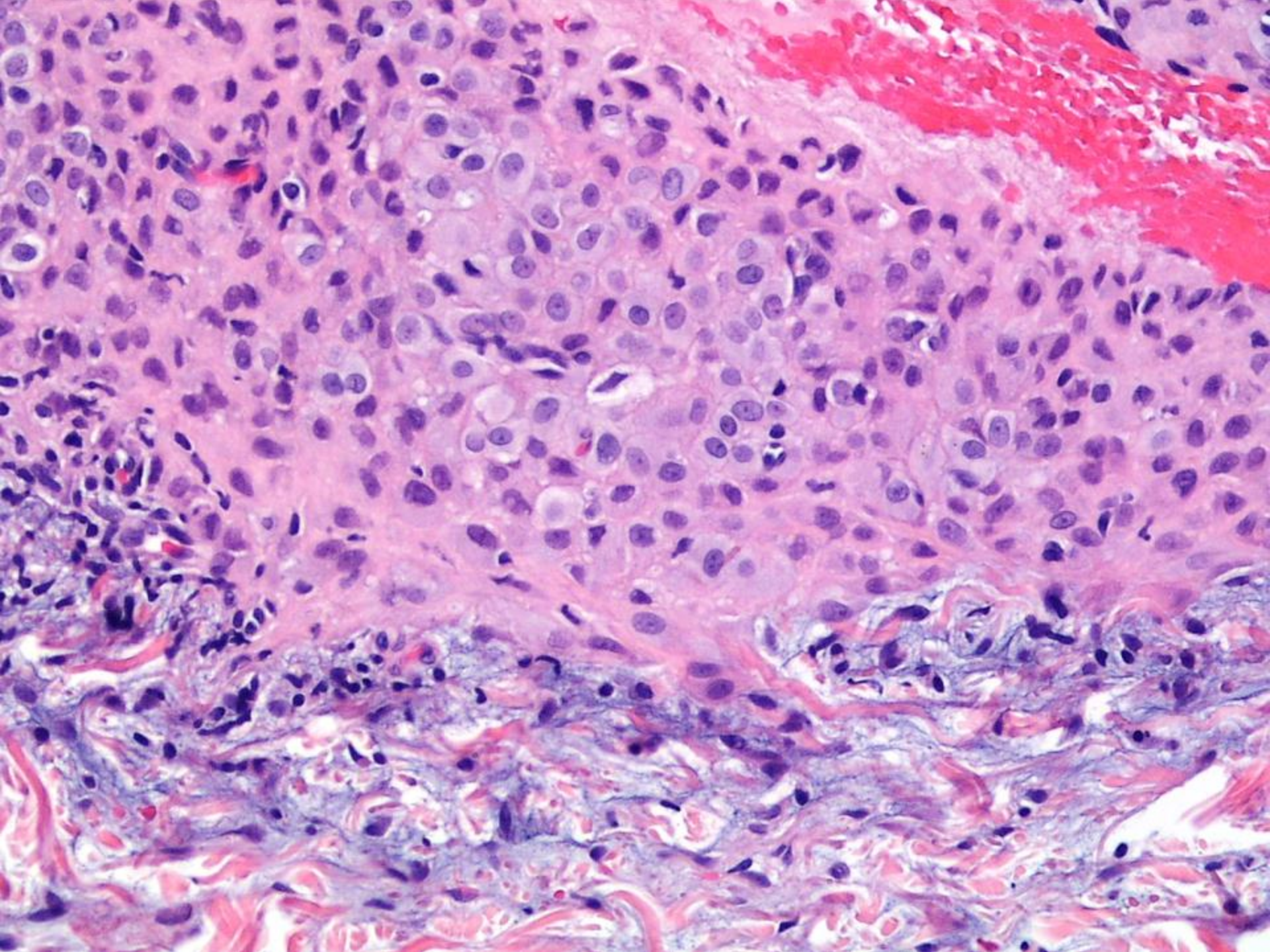
Gross Description

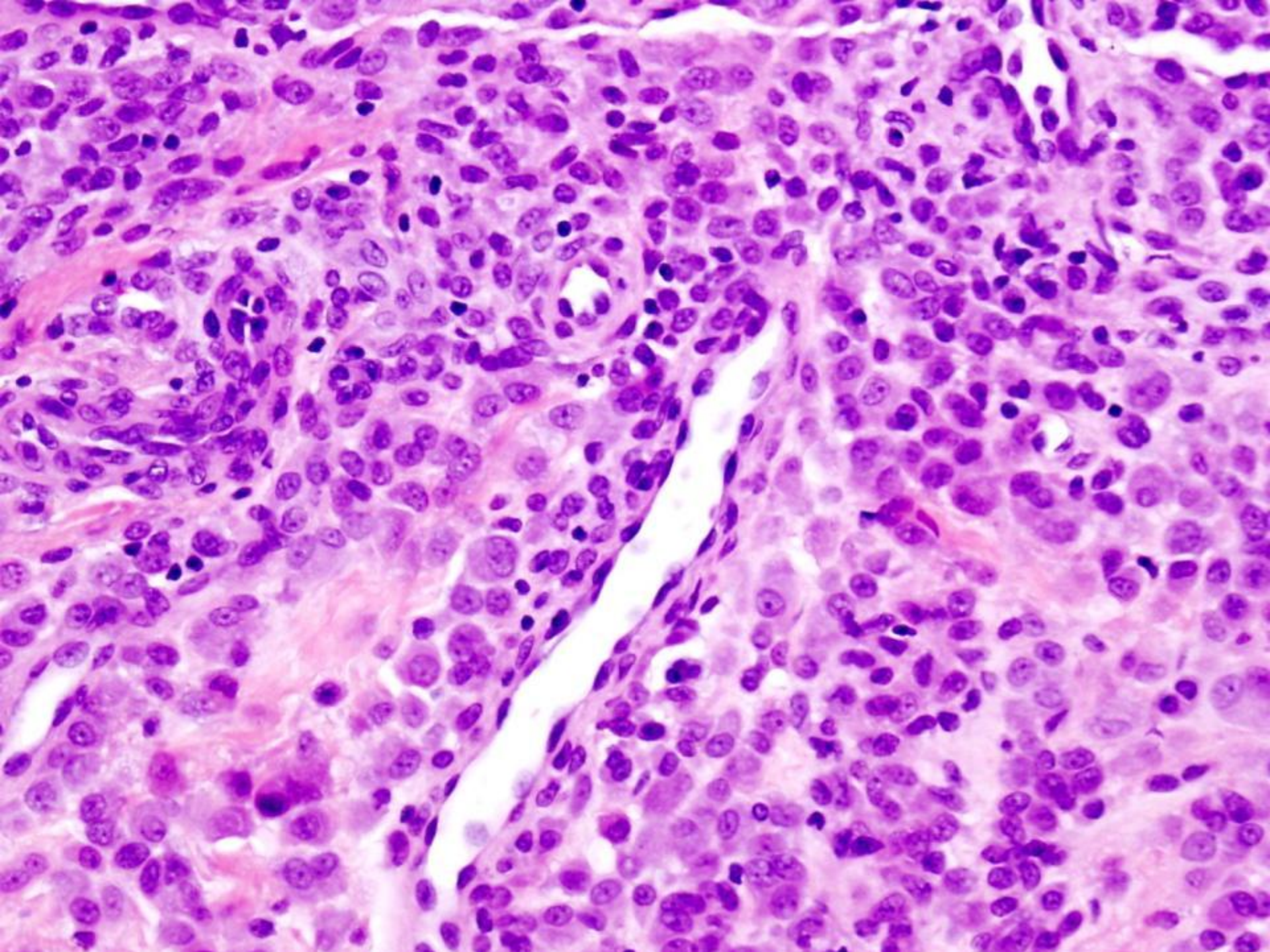
- **Punch biopsy of skin measuring 0.4 x 0.4 x 0.3 cm**











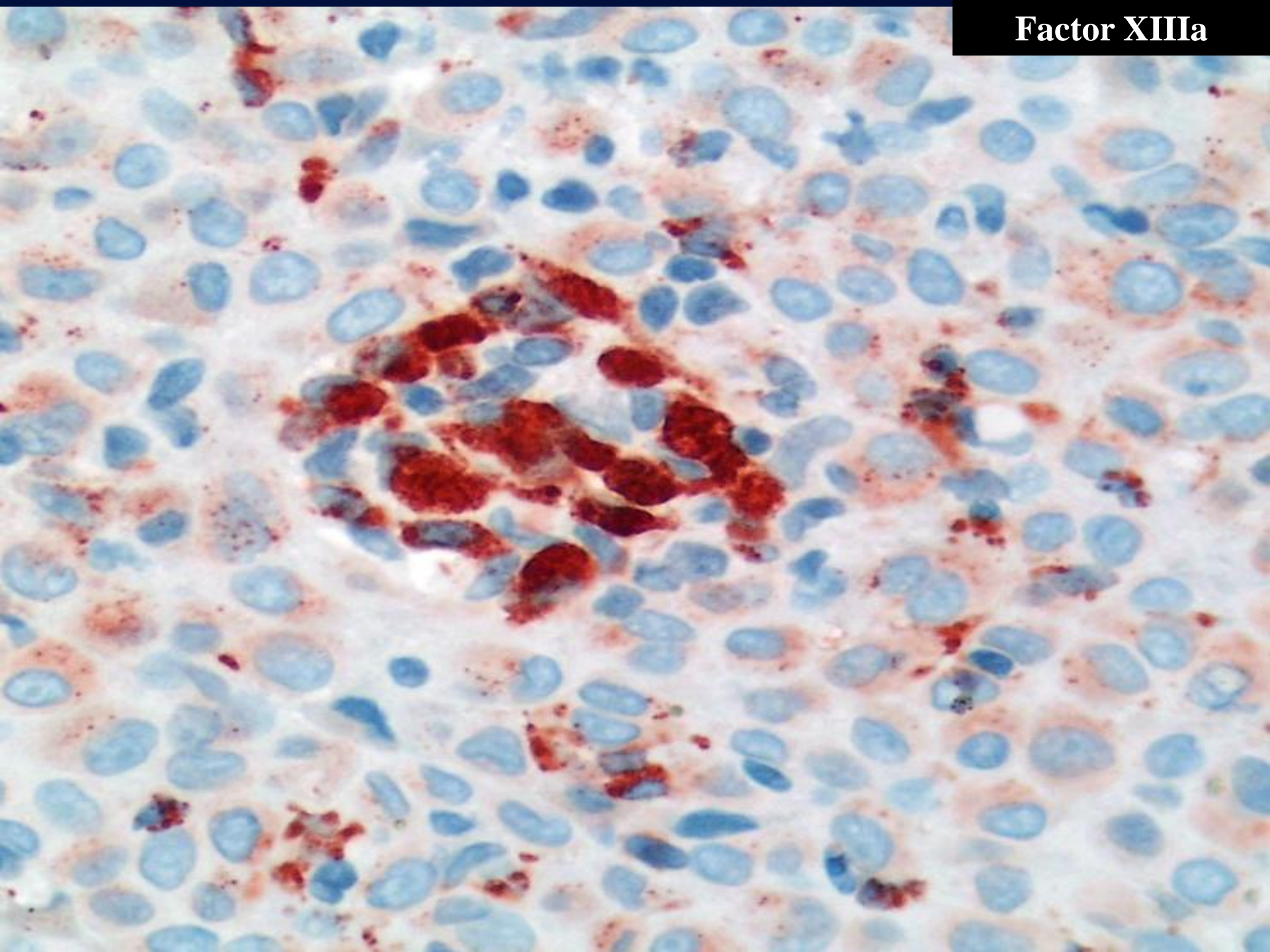
Your Diagnosis?

- A. Epithelioid cell histiocytoma**
- B. Granular cell tumor**
- C. Squamous cell carcinoma**
- D. Epithelioid
hemangioendothelioma**
- E. Intradermal Spitz nevus**

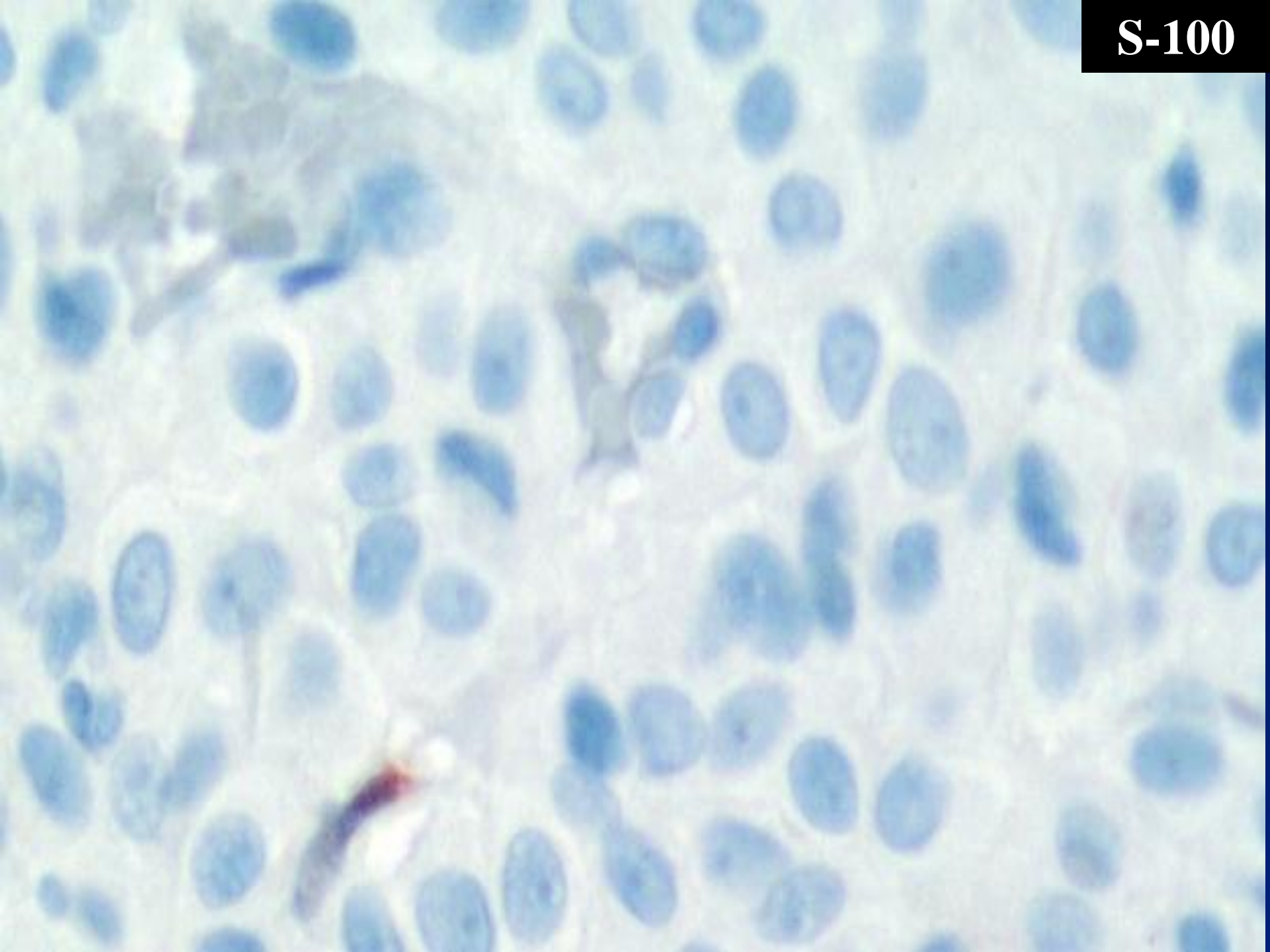
Your Diagnosis?

- A.** *Epithelioid cell histiocytoma*
- B.** Granular cell tumor
- C.** Squamous cell carcinoma
- D.** Epithelioid
hemangioendothelioma
- E.** Intradermal Spitz nevus

Factor XIIIa



S-100



Epithelioid Cell Histiocytoma

- **Originally described by Wilson-Jones in 1988**
- **Single lesion, young adults**
- **A Simulant of Vascular and Melanocytic neoplasms.**

Epithelioid cell histiocytoma

- **Variant of dermatofibroma**
 - **Epithelioid cells predominant**
 - **Lack of other types such as giant, foamy cells**
 - **Sharp circumscription**
 - **Prominent vascularity**
 - **Usually papillary dermis lesion**

ECH vs. Melanocytic Neoplasm

- **Lack of nesting in ECH**
- **Lack of junctional component in ECH**
- **Lack of melanin in ECH**
- **Negative for melanocytic markers**
- **Factor XIIIa & CD68 positivity**

Differential Diagnosis

- **Melanoma**
- **Intradermal spitz nevus**
- **Squamous cell carcinoma**
- **?Vascular lesion**

Key Points

- **Epithelioid cells, generally in upper dermis**
- **No junctional component**
- **Immunohistochemistry:**
Keratin, S-100, melanocytic markers -, CD68 +, Factor XIIIa +

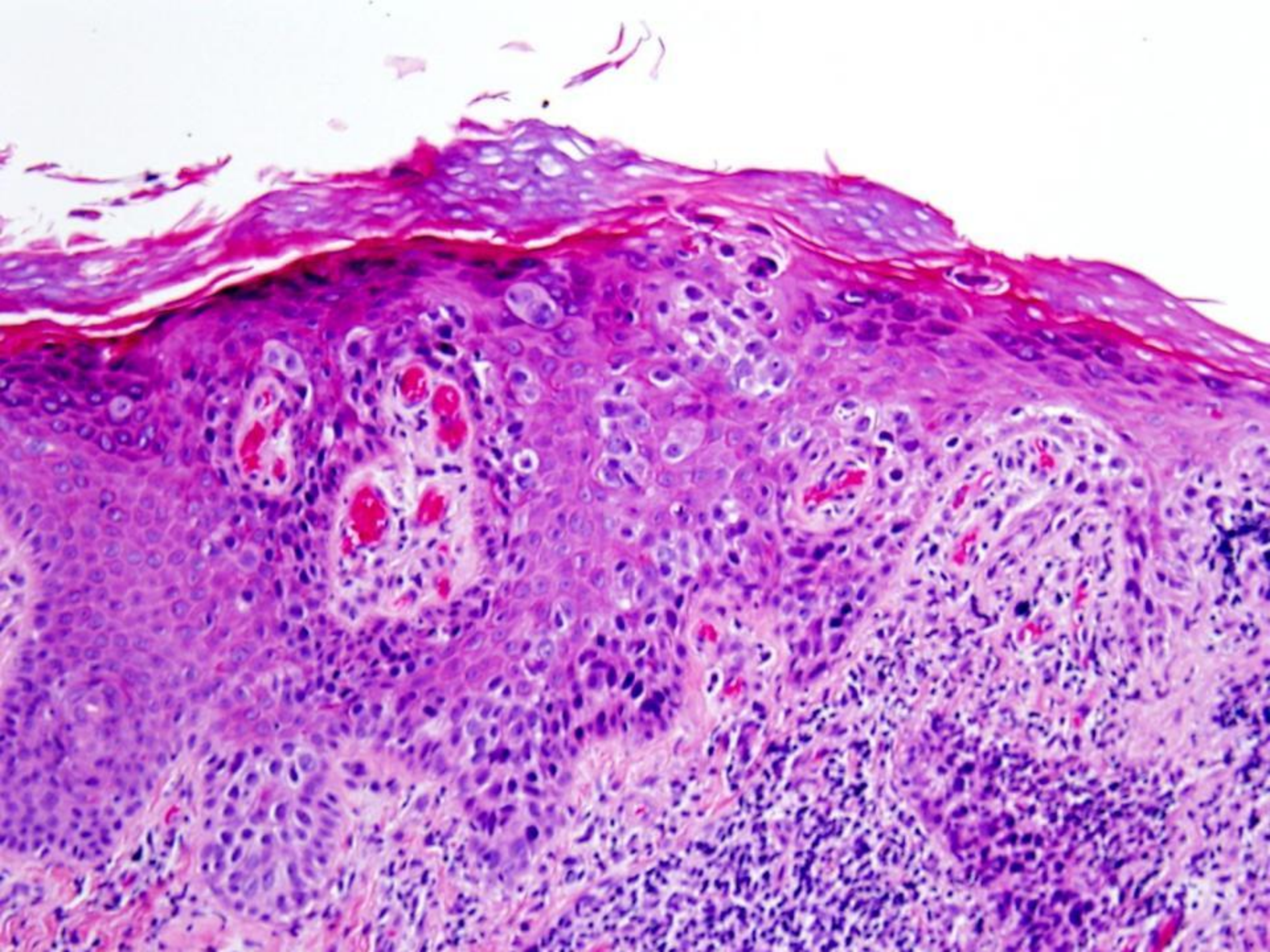
Case 6

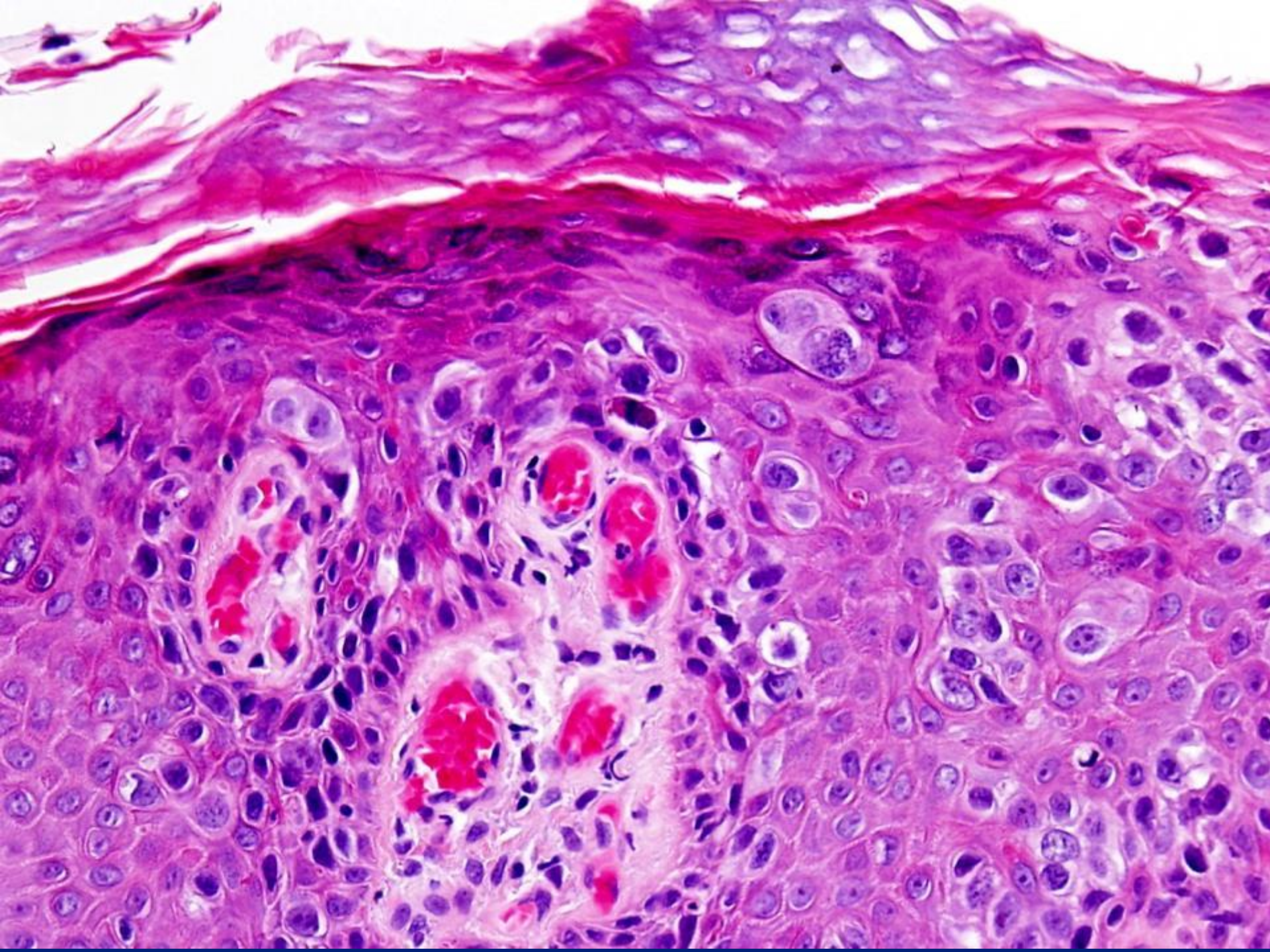
Clinical Data

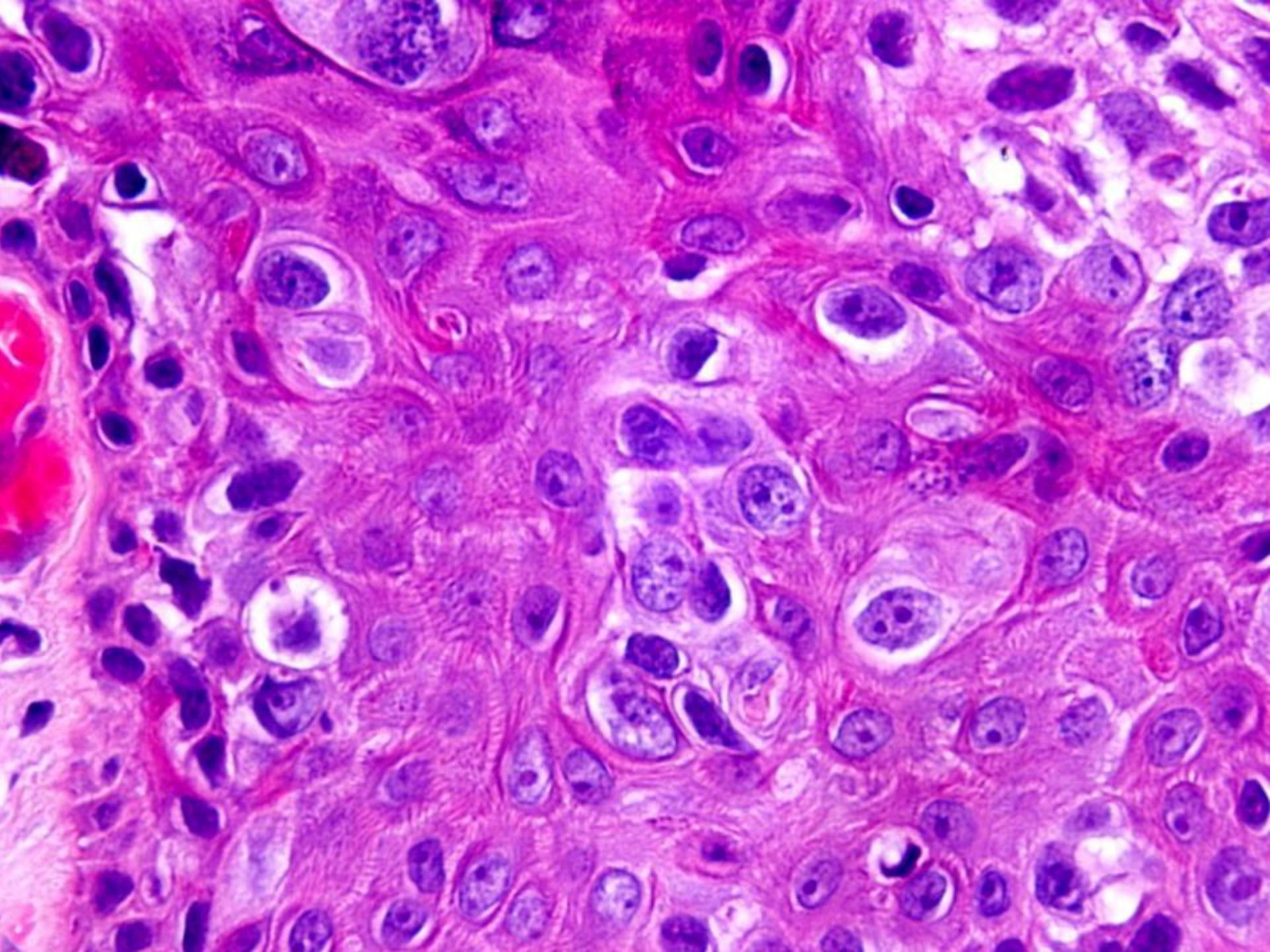
- N/A

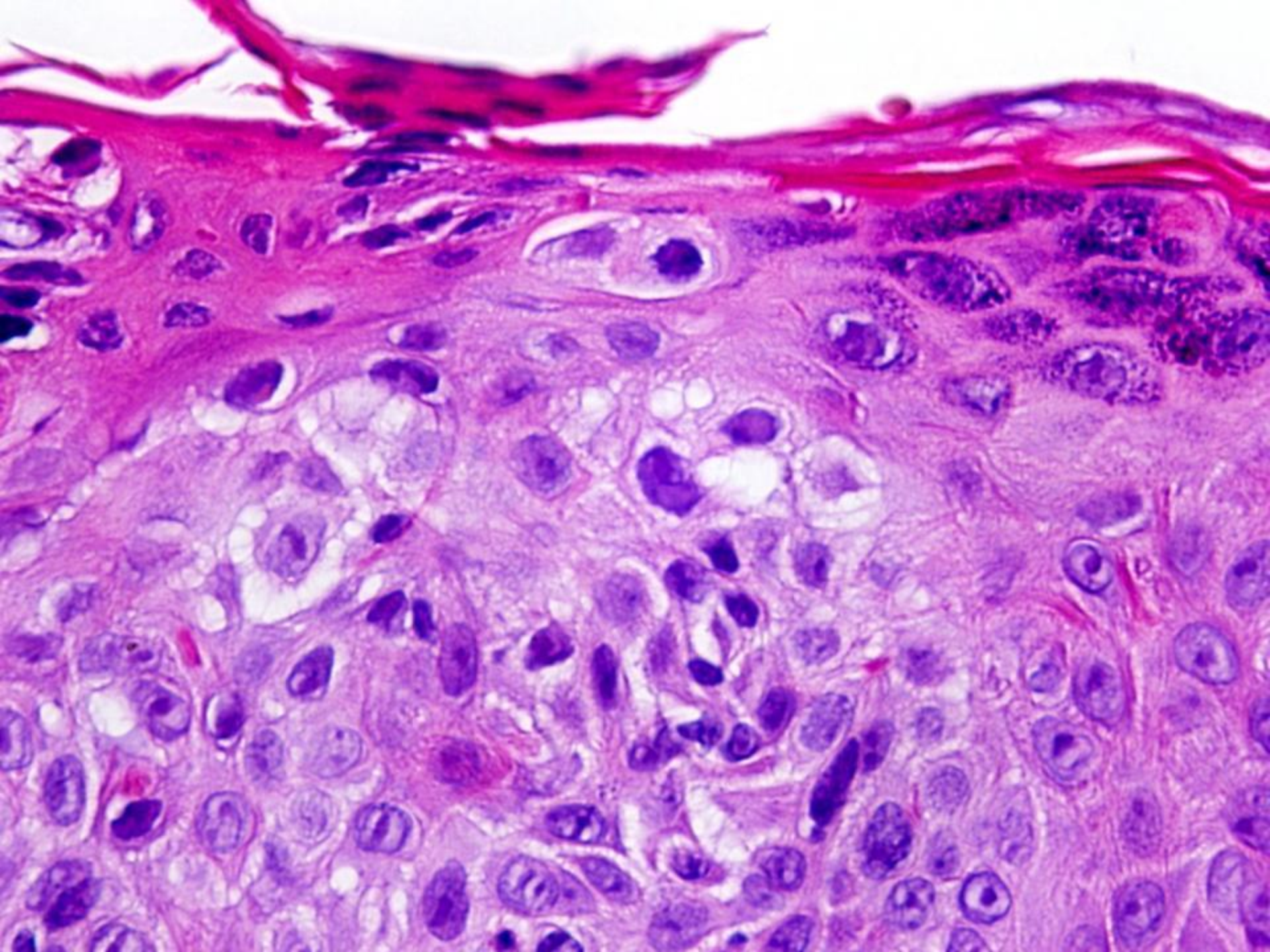
Gross Description

- **Punch biopsy of skin measuring 0.3 x 0.3 x 0.2 cm.**









Your Diagnosis?

- Langerhans cell histiocytosis
- Pagetoid squamous cell carcinoma in situ
- Pagetoid reticulosis
- Epithelioid variant of Merkel cell carcinoma
- MIS

Your Diagnosis?

- Langerhans cell histiocytosis
- *Pagetoid squamous cell carcinoma in situ*
- Pagetoid reticulosis
- Epithelioid variant of Merkel cell carcinoma
- MIS

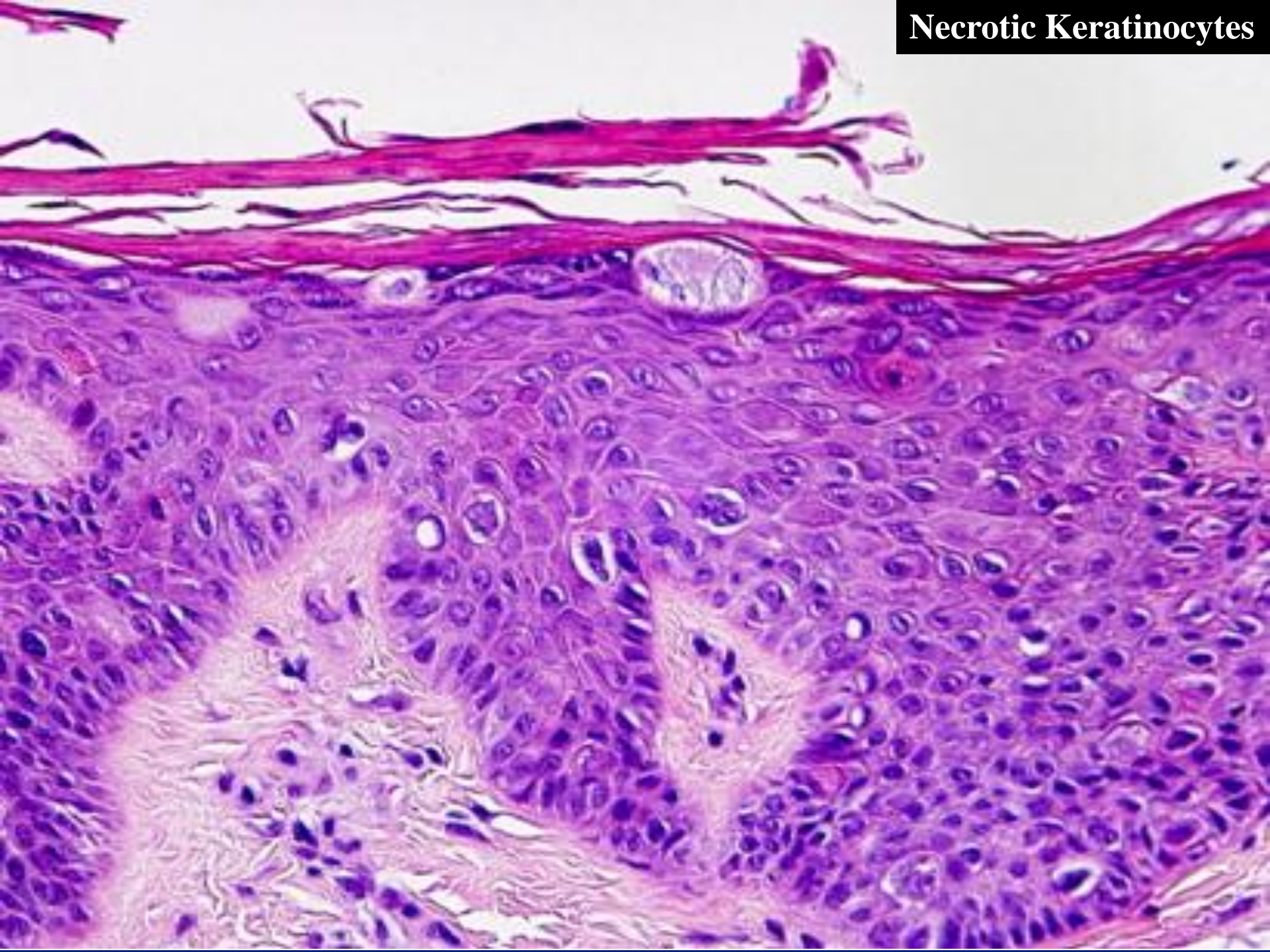
PSCCIS

- 5% of SCC
- No prognostic implications
- Diagnostic implications

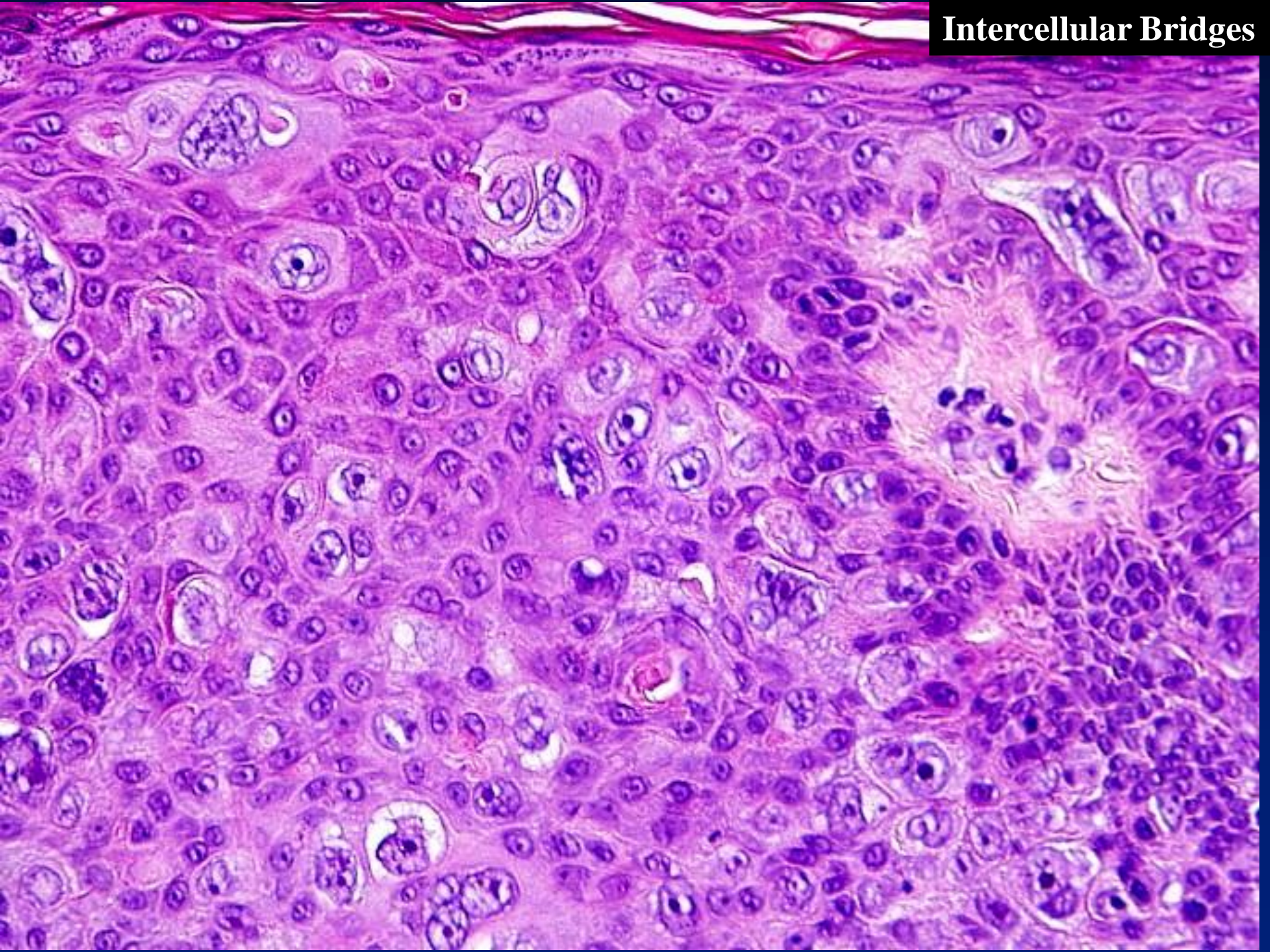
PSCCIS

- **Intercellular bridges**
- **Presence of squamous atypia/
squamous cell carcinoma in situ**
- **Gradation from obvious
squamous atypia to “pagetoid”
cells**
- **Keratohyaline granules**

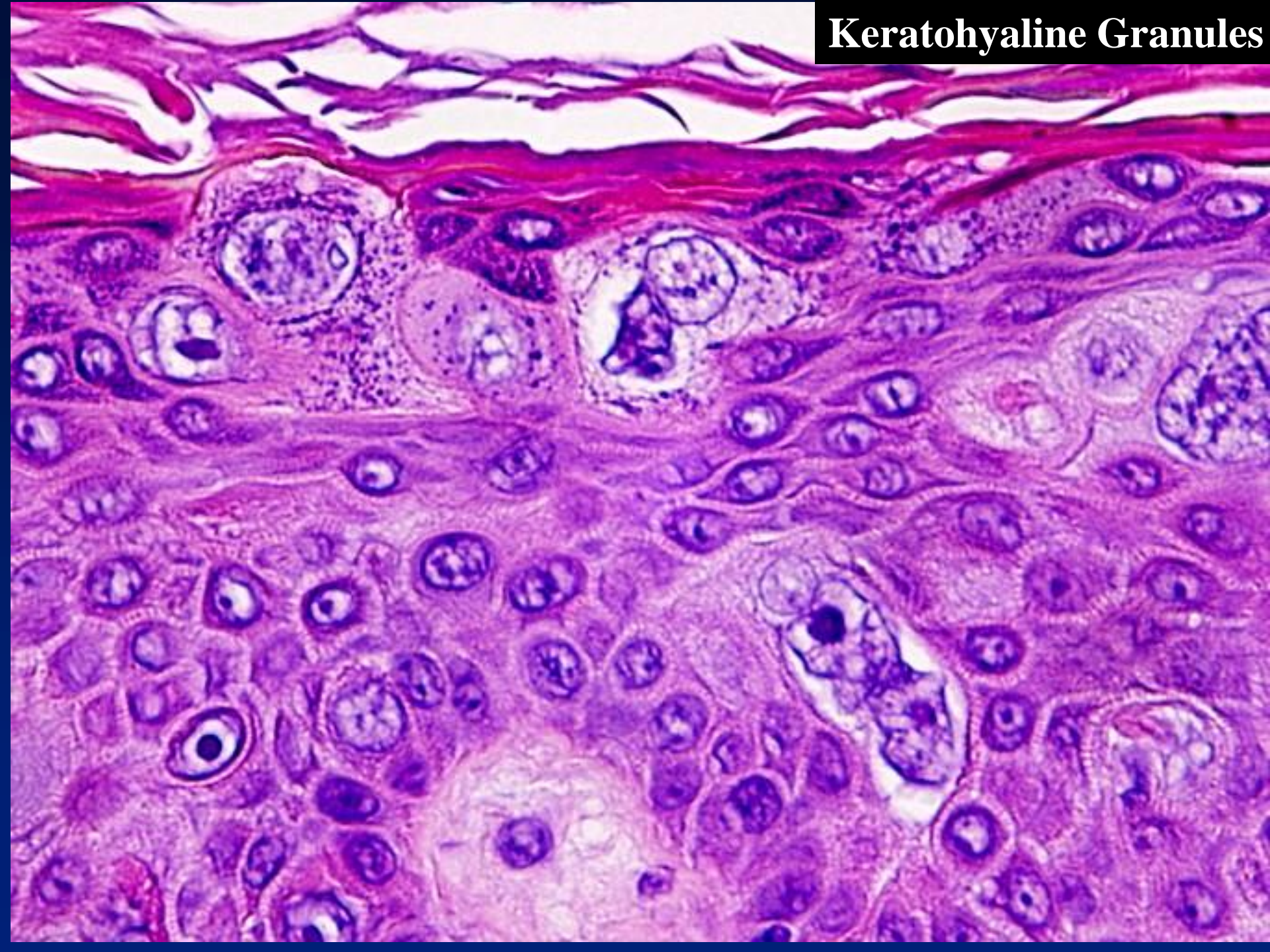Necrotic Keratinocytes

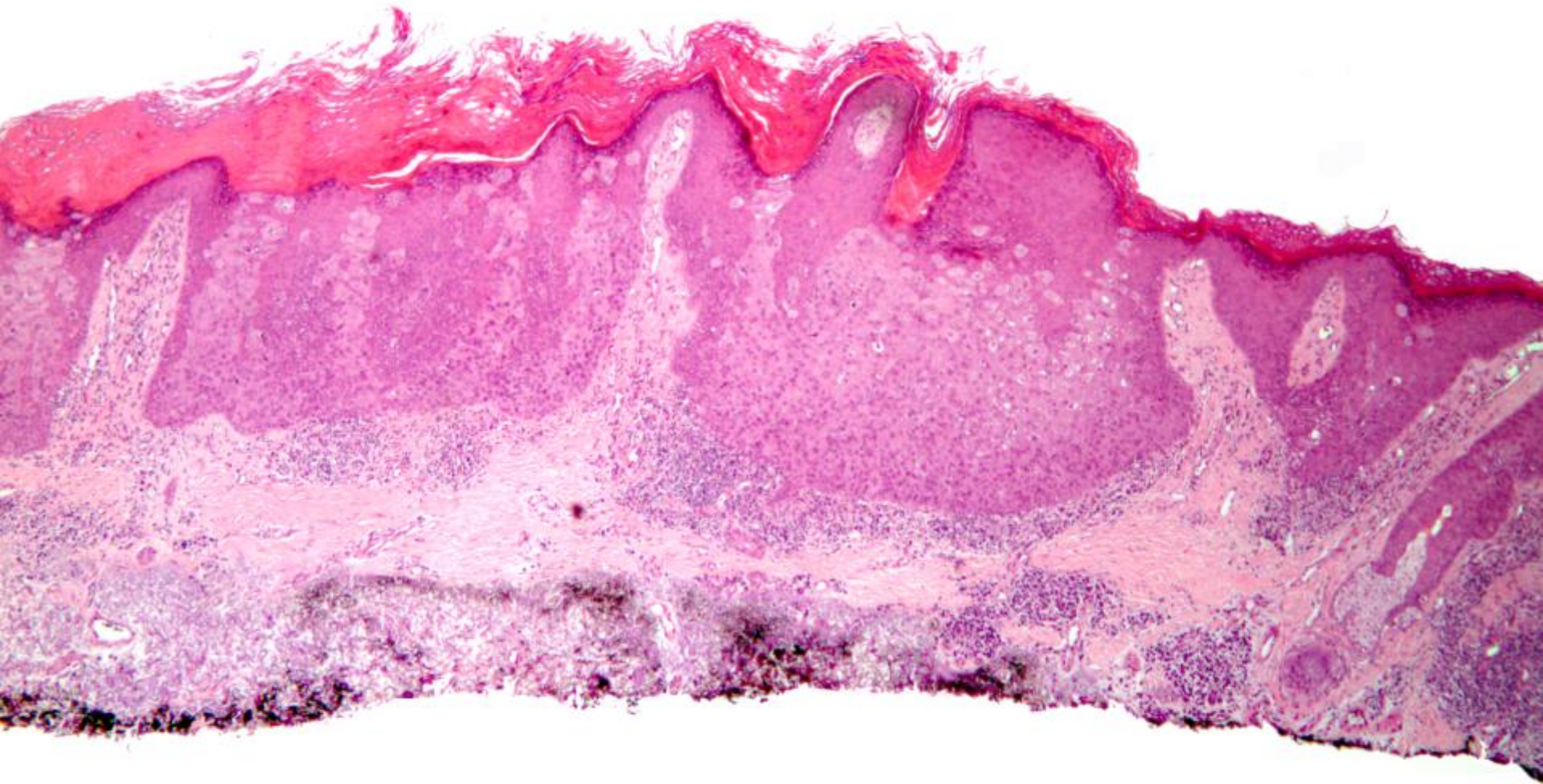


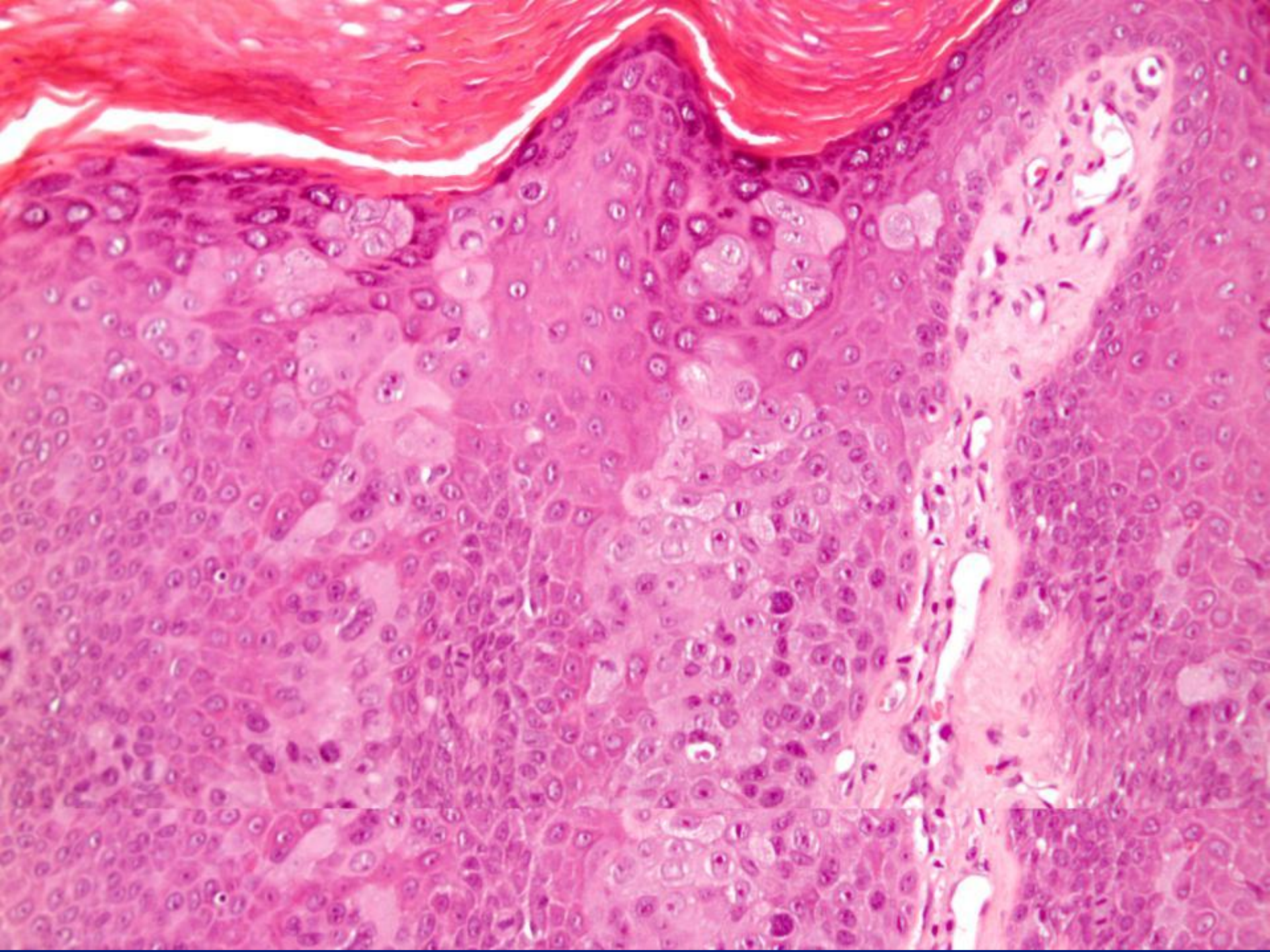
Intercellular Bridges



Keratohyaline Granules



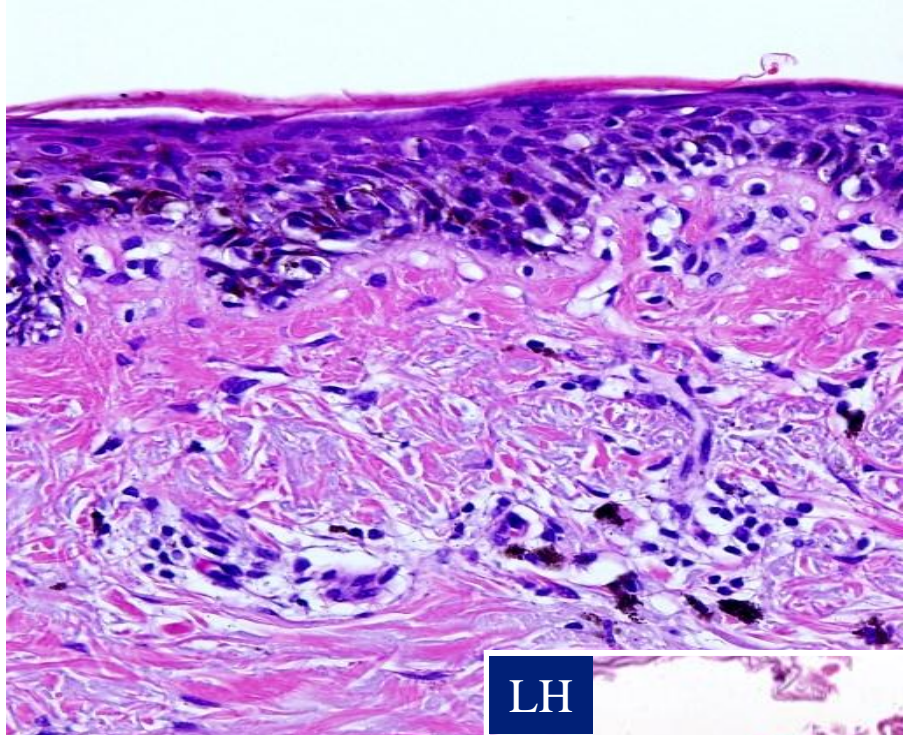




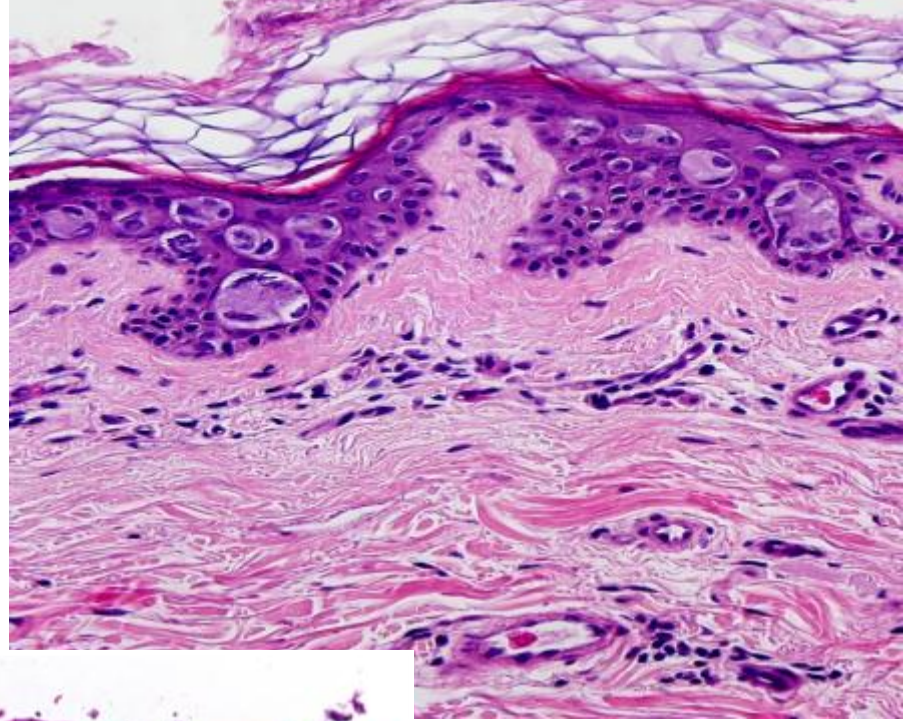
Differential Diagnosis

- Malignant melanoma in situ
- Paget's disease
- Langerhans cell histiocytosis

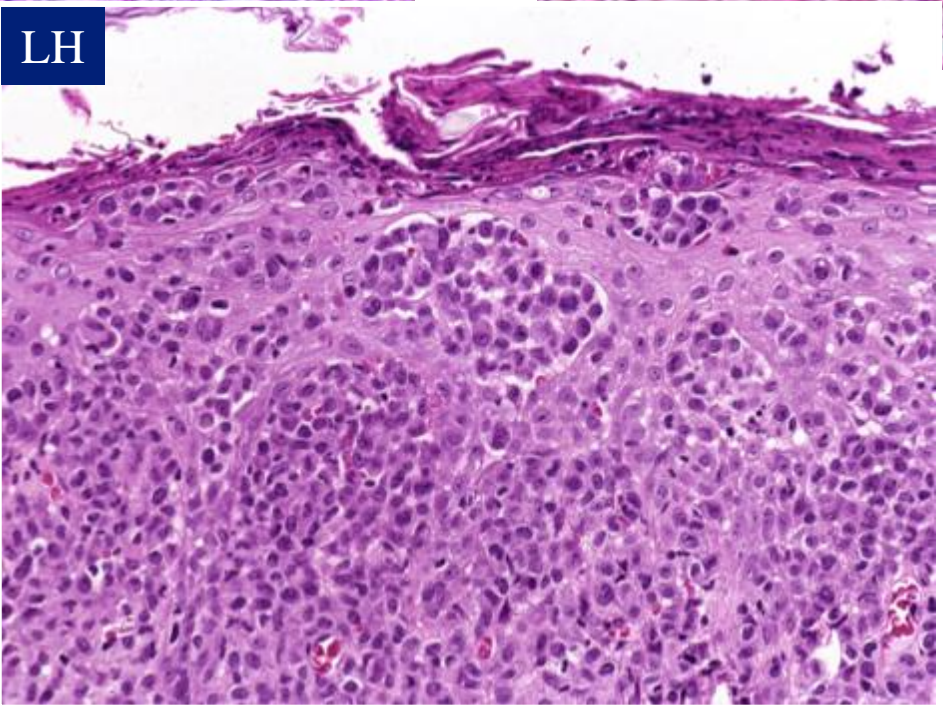
MIS



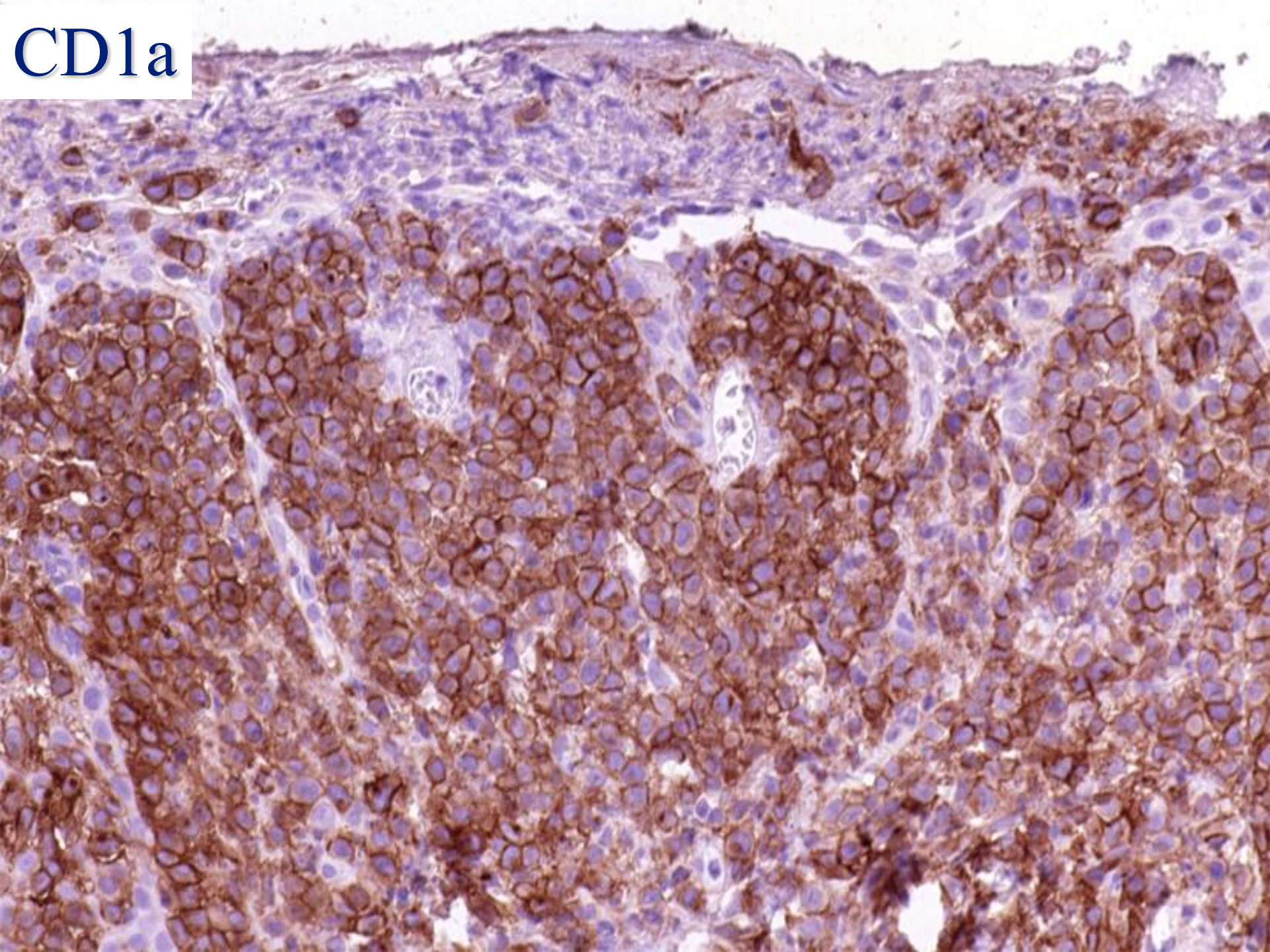
PD



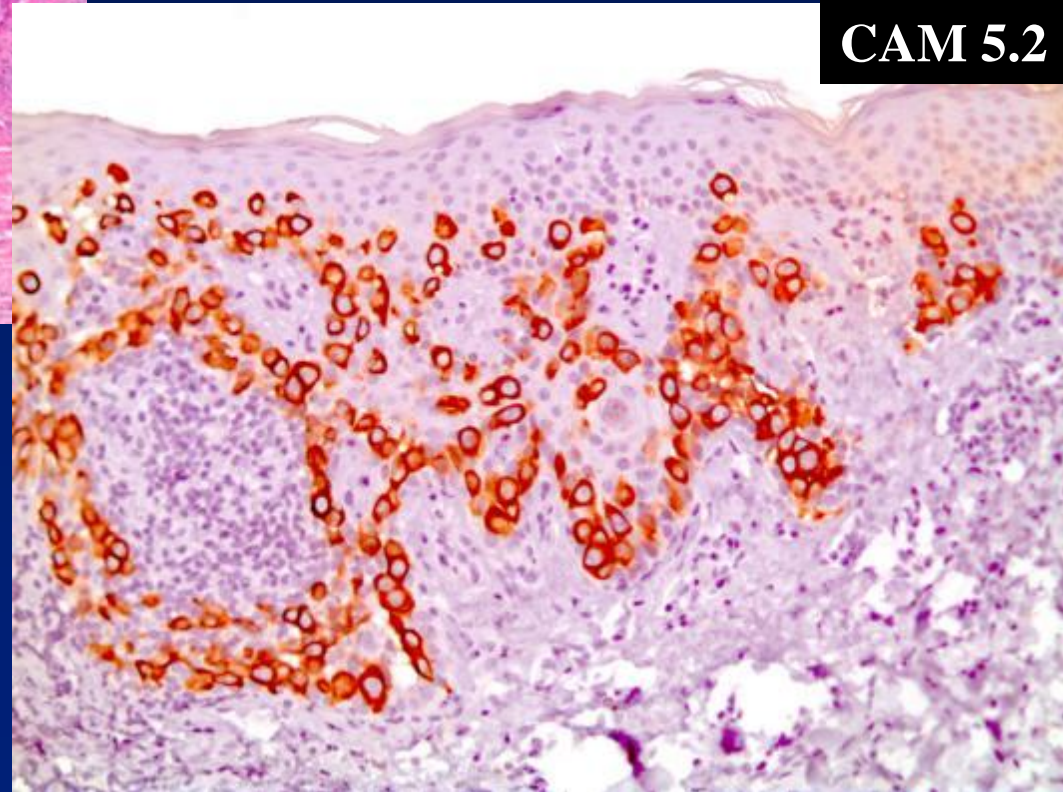
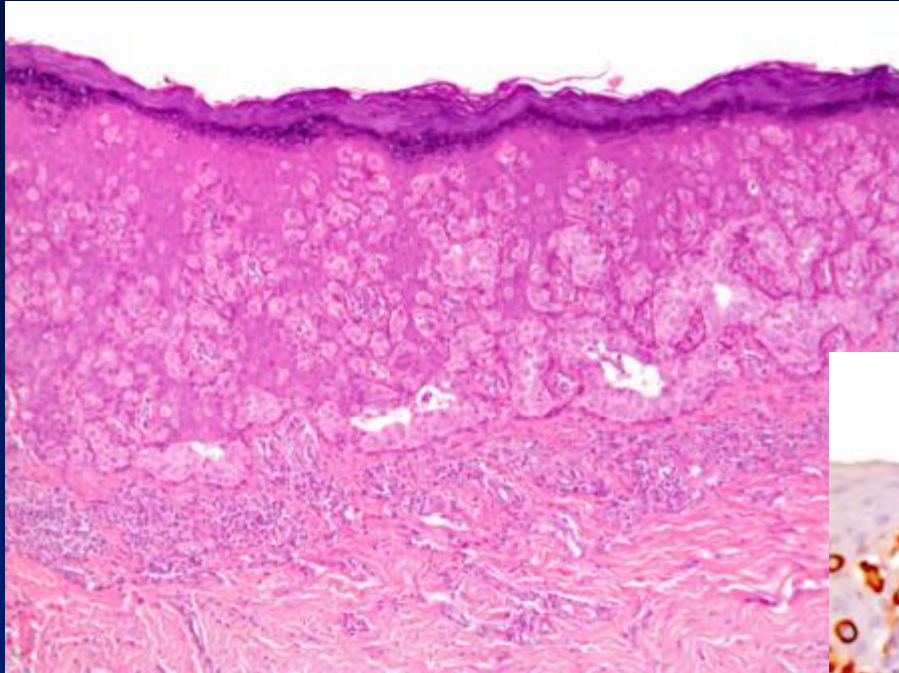
LH



CD1a



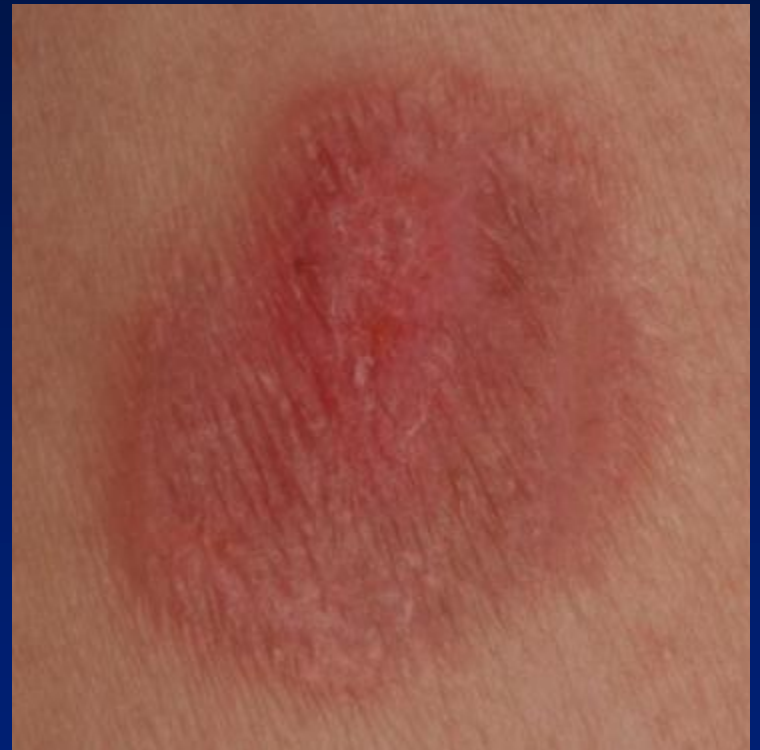Extramammary Paget's Disease



Case 7

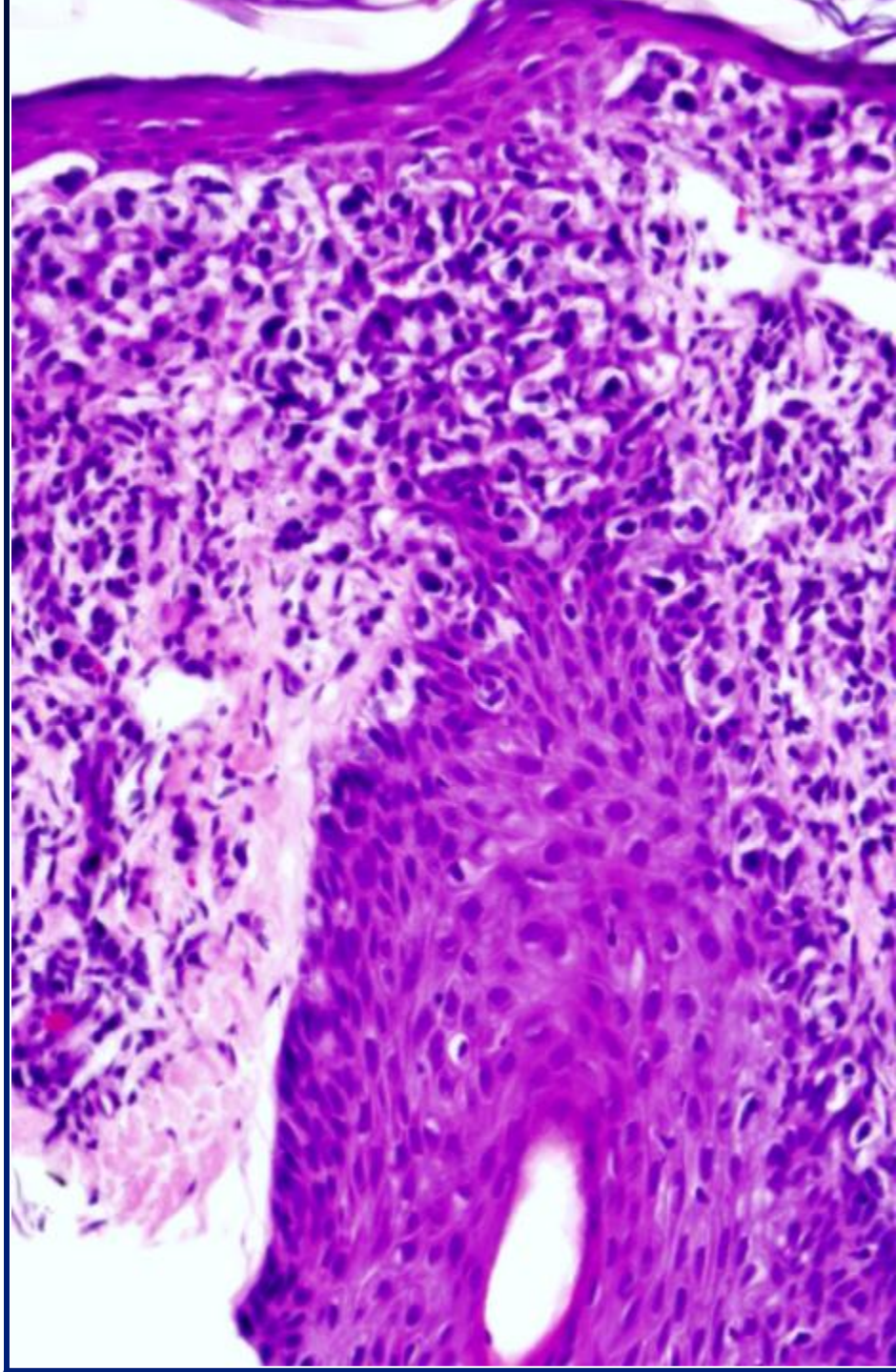
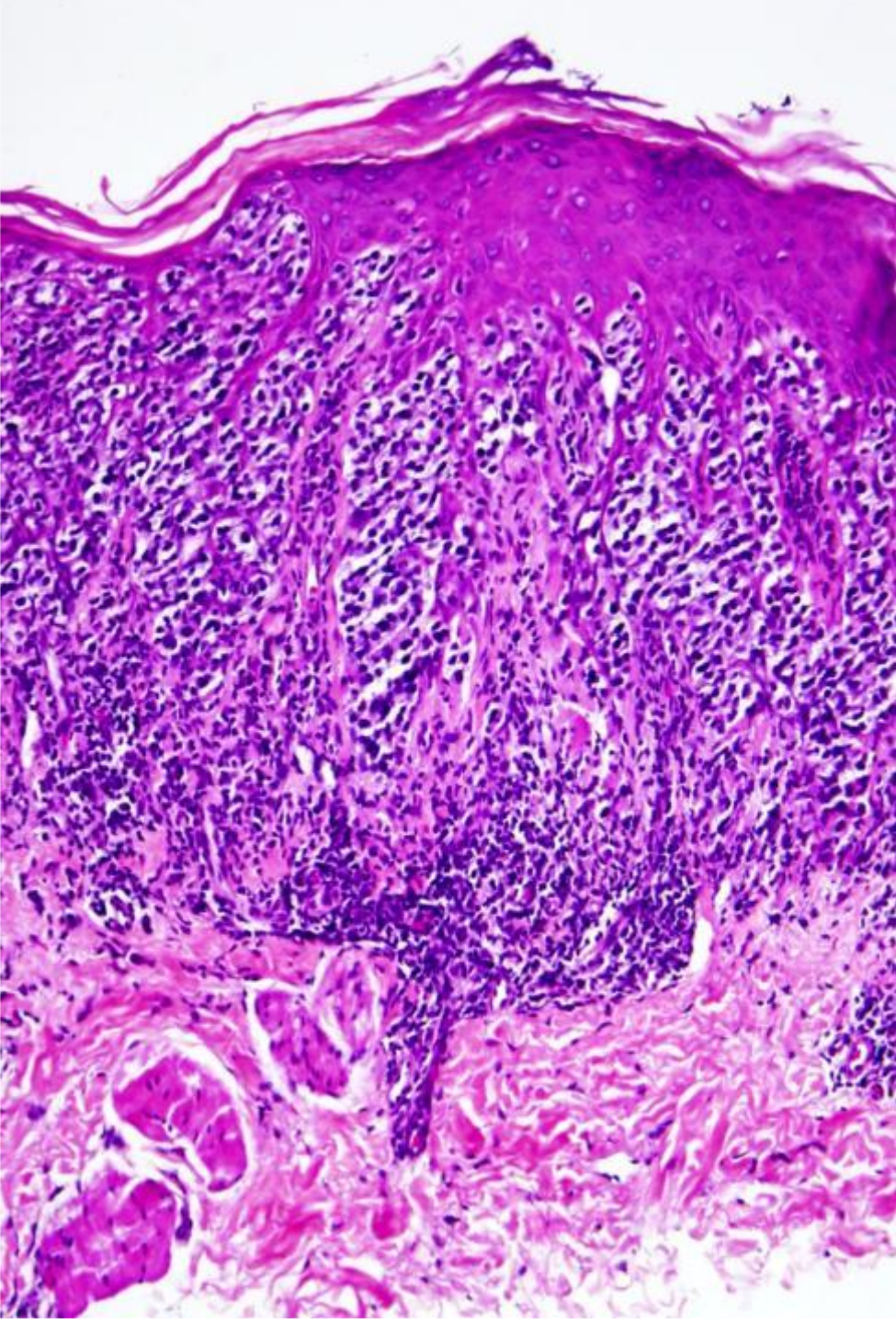
Clinical Data

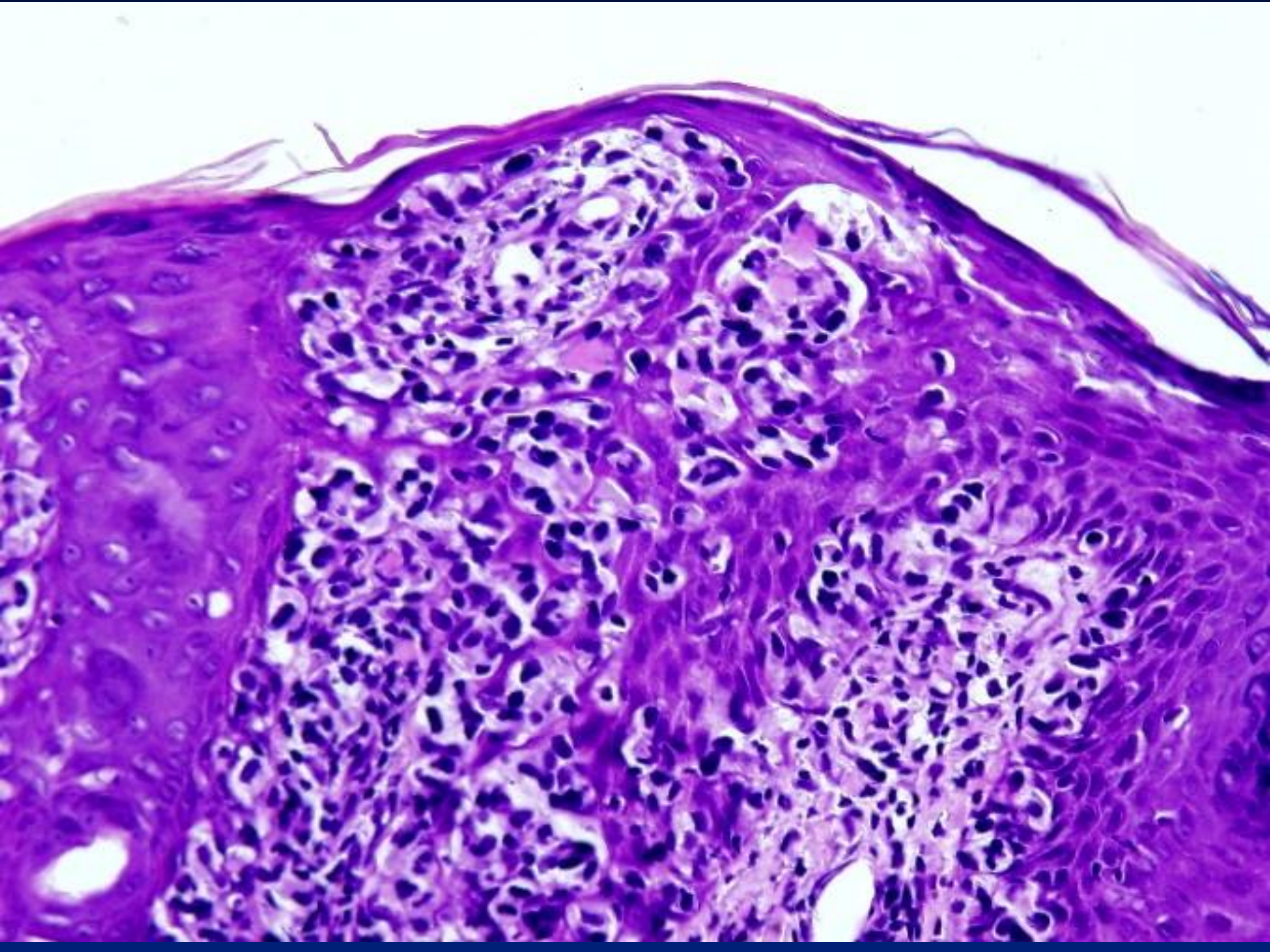
- **11-year-old male
with lesion of right
anterior thigh**

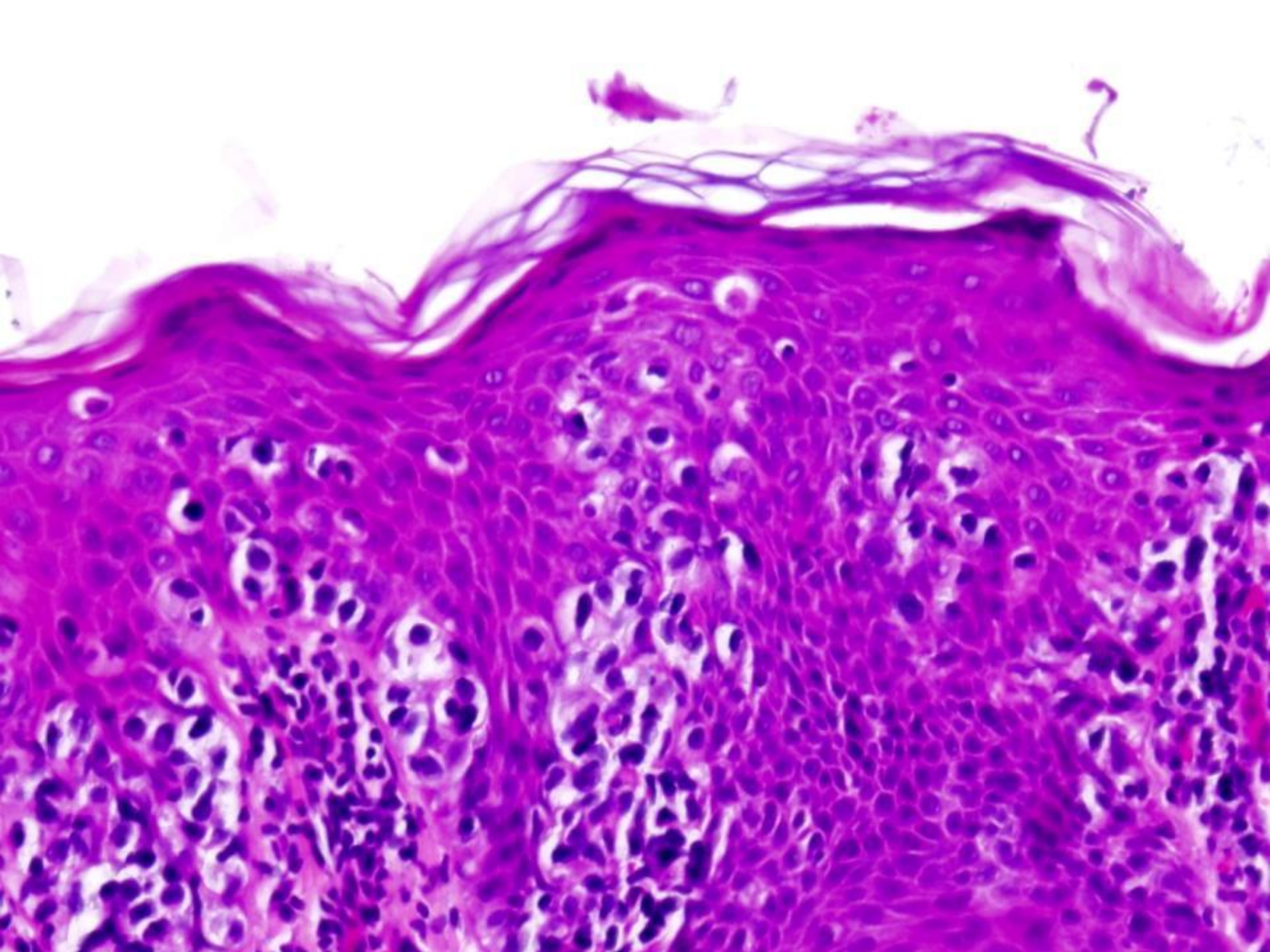


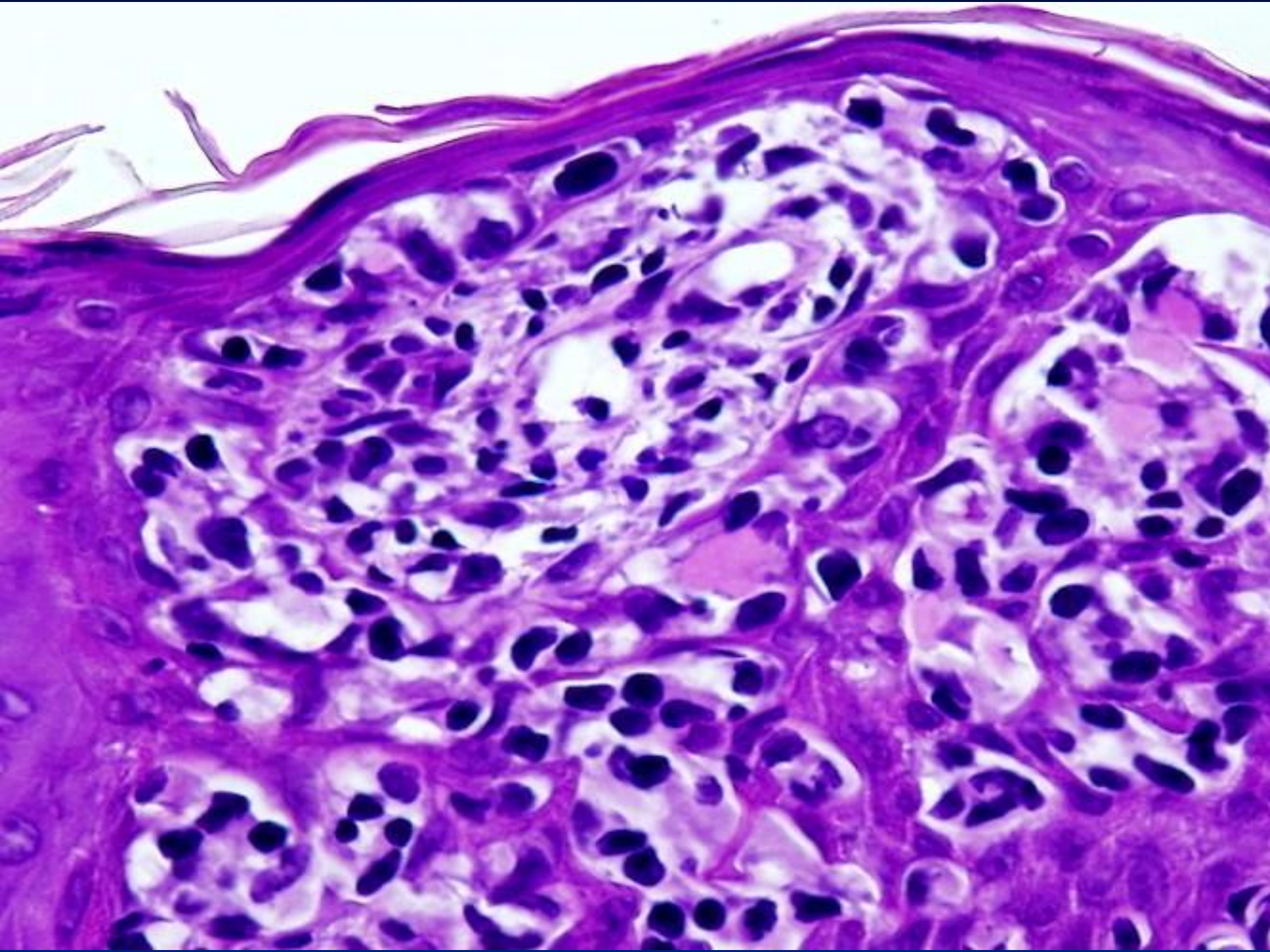
Gross Description

- Shave biopsy measuring 0.9 x 0.7 x 0.2 cm









Your Diagnosis?

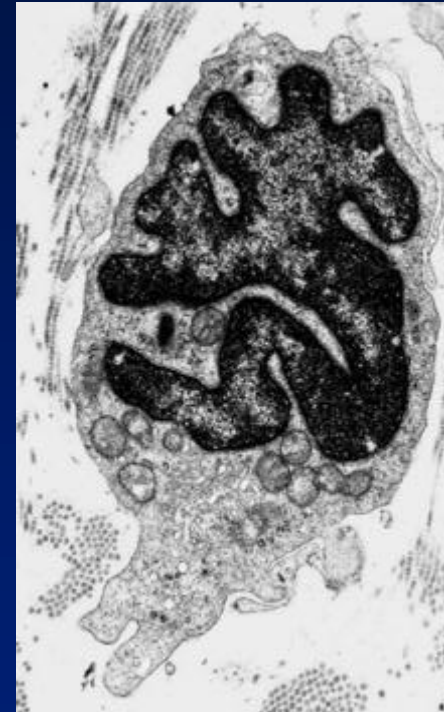
- A. Pagetoid squamous cell carcinoma in situ**
- B. Langerhans cell histiocytosis**
- C. Pagetoid reticulosis**
- D. Merkel cell carcinoma**
- E. MIS**

Your Diagnosis?

- A. Pagetoid squamous cell carcinoma in situ
- B. Langerhans cell histiocytosis
- C. *Pagetoid reticulosis***
- D. Merkel cell carcinoma
- E. MIS

Pagetoid Reticulosis

- Variant of Mycosis Fungoides



Pagetoid Reticulosis

- **Localized variant of MF**
- **Red, scaly or verrucous patch on distal extremity**
- **Males more affected**
- **Prognosis generally good**

Pagetoid Reticulosis

- Generalized variant of PR is known as Ketrone-Goodman
- Prognosis same as MF
- T-cell gene rearrangement, usually $\alpha\beta$

Differential Diagnosis

- MIS
- Pagetoid squamous cell carcinoma in situ
- Extra-mammary Paget's disease

Key Points

- **Focus on the nuclei:**
(hyperchromatic, “small-cell”
type of nuclei)
- **Immunohistochemistry: CD4 +,
S-100-, melanocytic markers-**

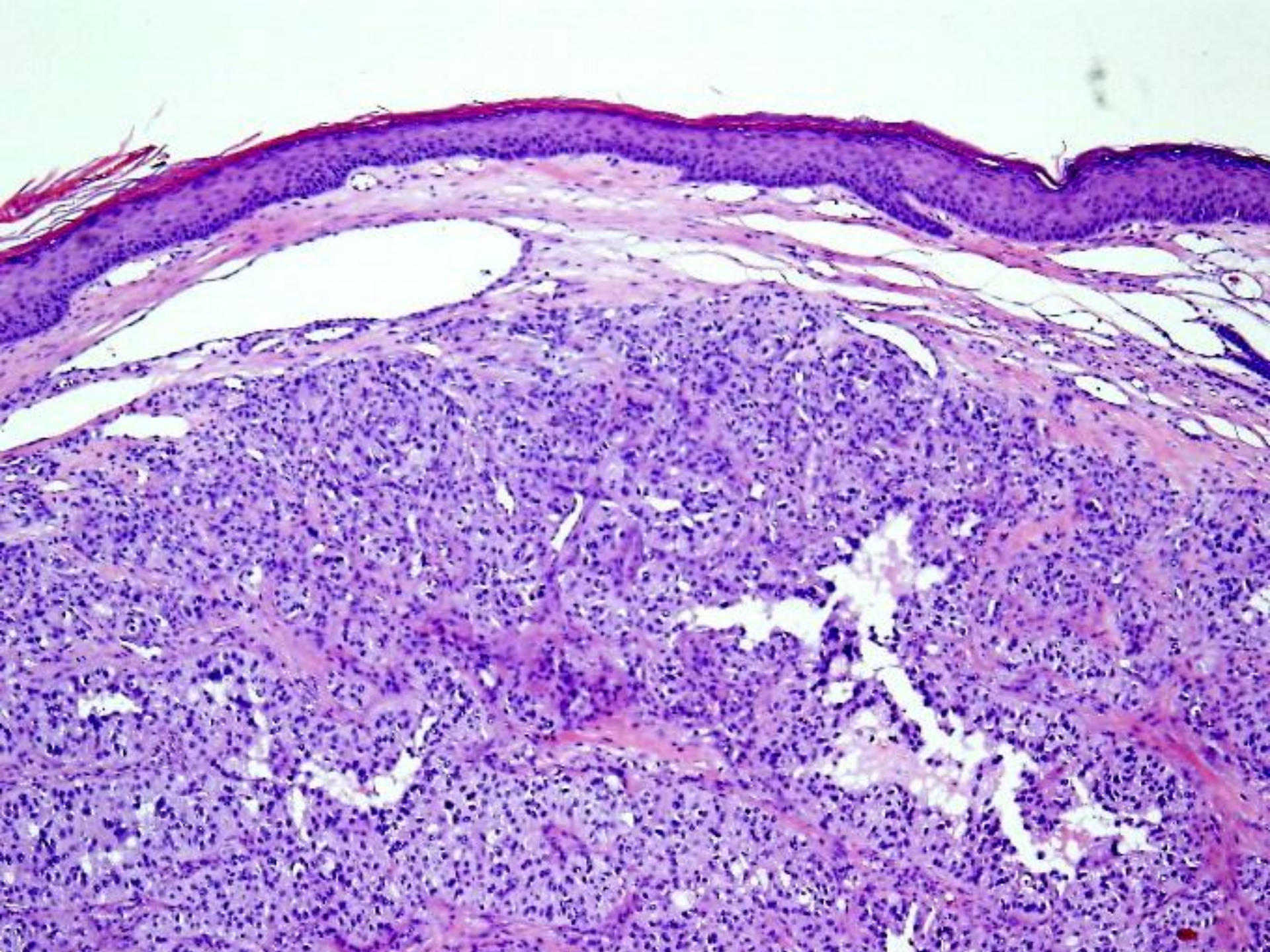
Case 8

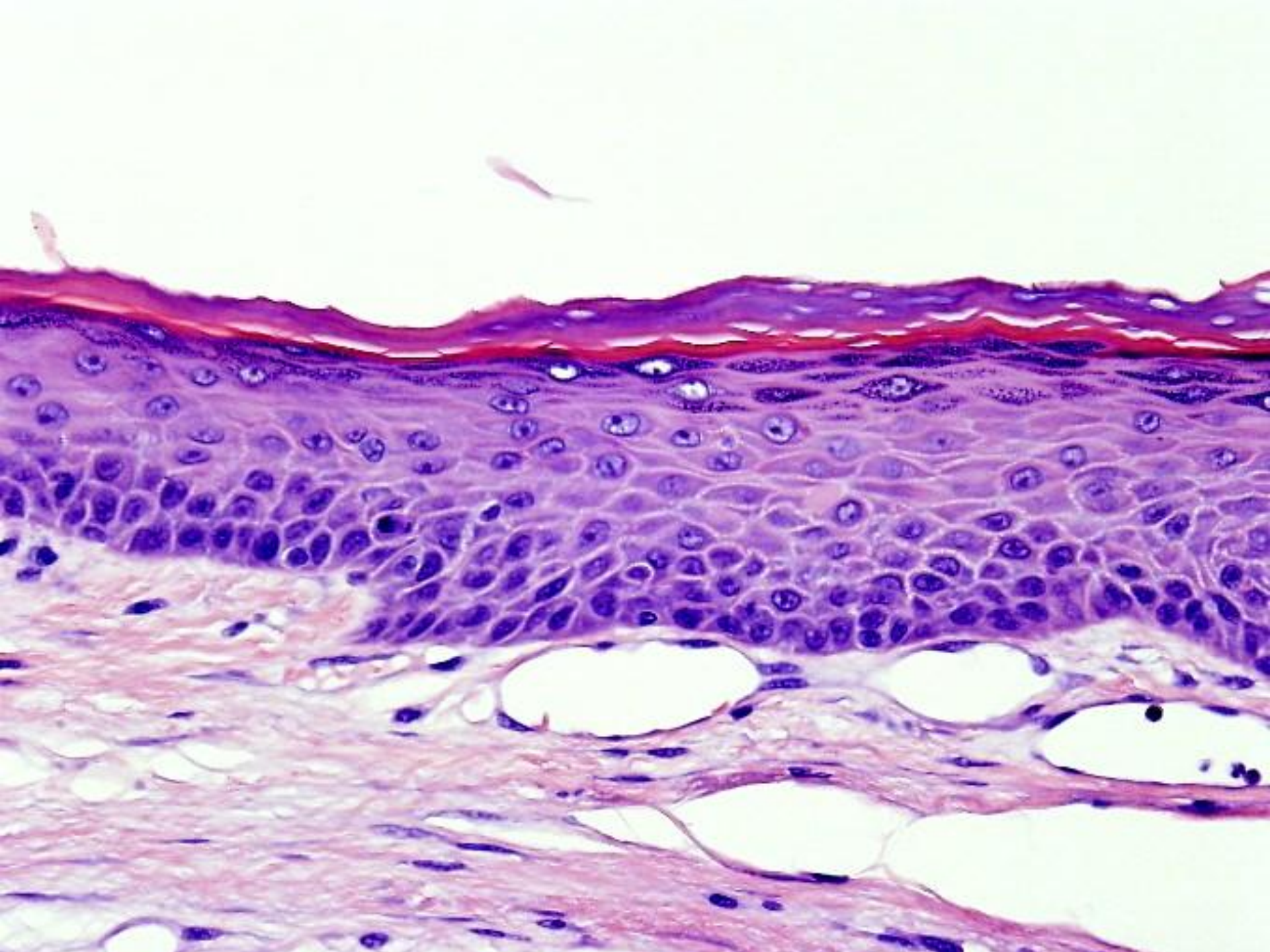
Clinical Data

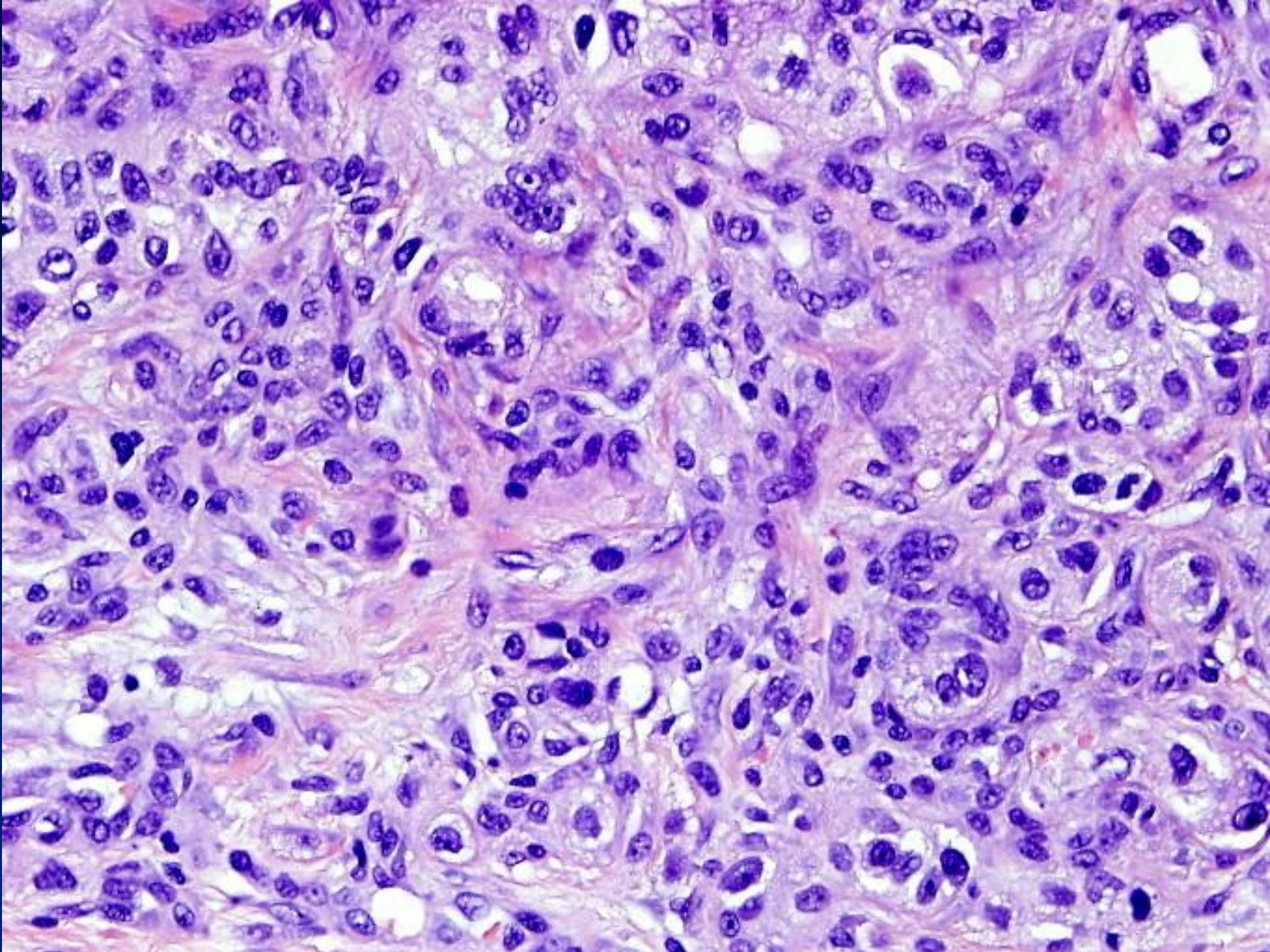
- **63-year-old male with nodule on left nasal sidewall**

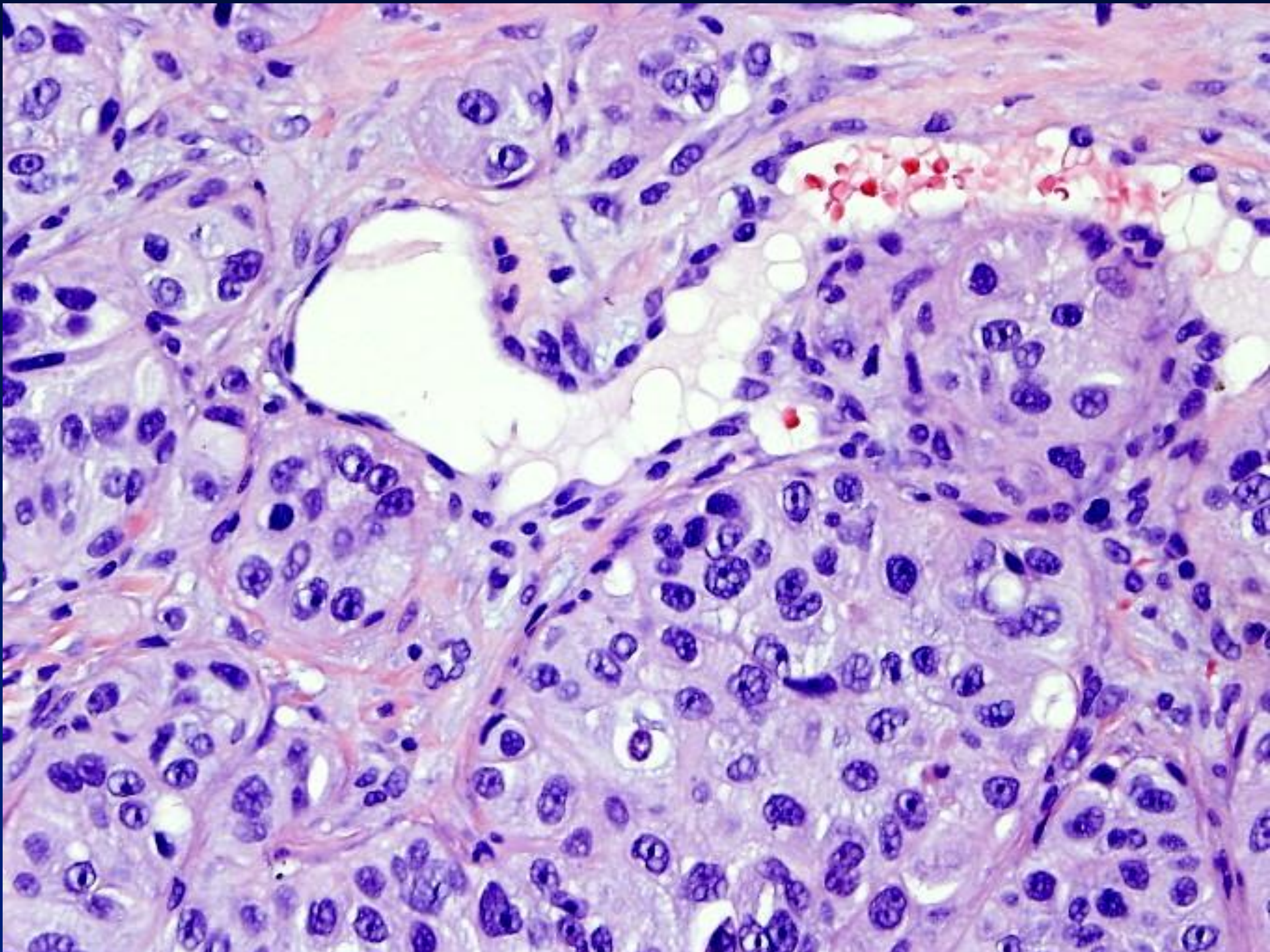
Gross Description

- **Ellipse of skin measuring 2.0 x 1.5 x 1.0 cm**









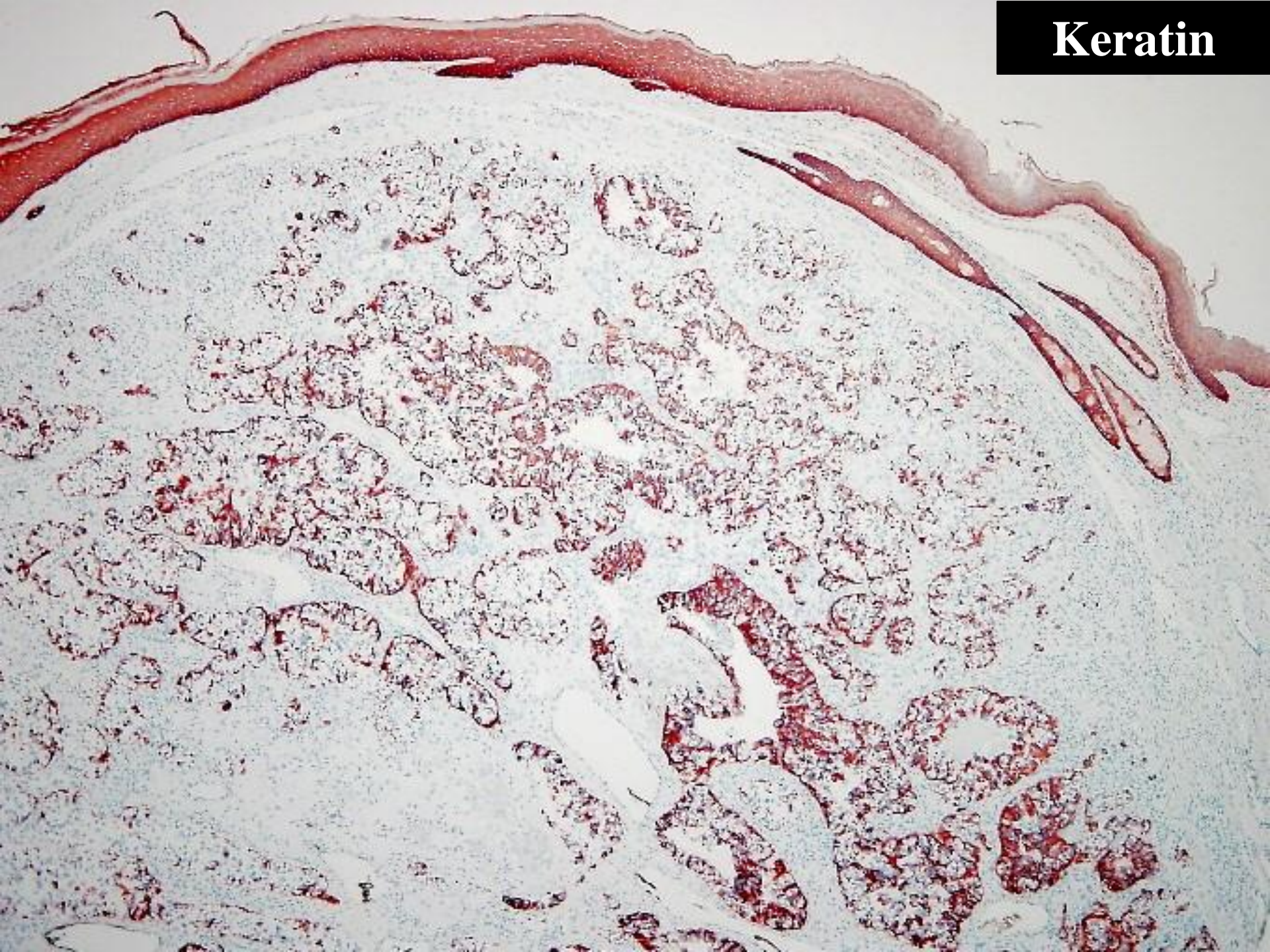
Your Diagnosis?

- A. Metastatic carcinoma**
- B. Paraganglioma**
- C. Adnexal neoplasm**
- D. Squamous cell carcinoma**
- E. Epithelioid hemangioendothelioma**
- F. Melanoma**

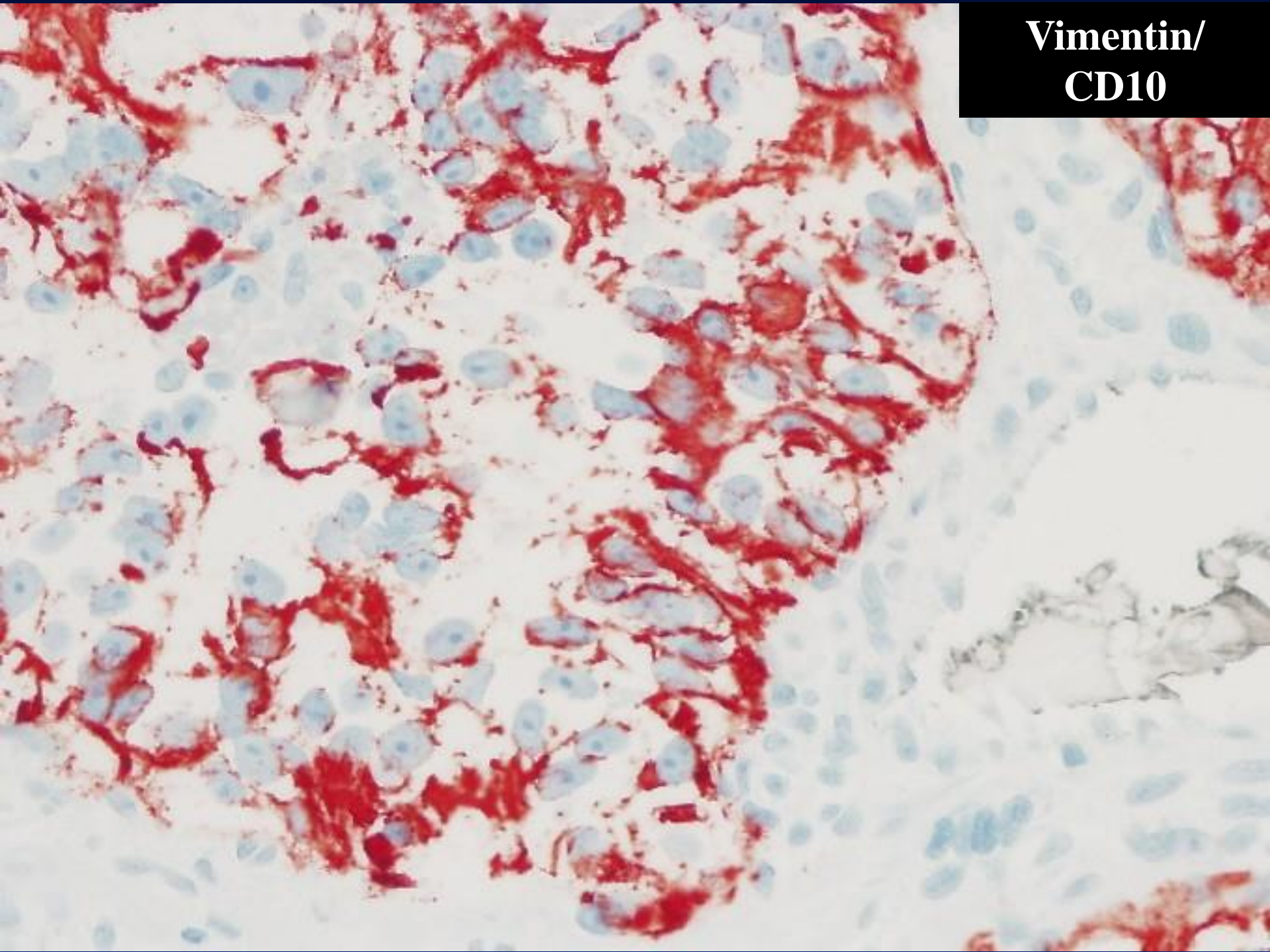
Your Diagnosis?

- A. *Metastatic carcinoma*
- B. Paraganglioma
- C. Adnexal neoplasm
- D. Squamous cell carcinoma
- E. Epithelioid hemangioendothelioma
- F. Melanoma

Keratin



**Vimentin/
CD10**



Metastasis to Skin

- Cutaneous metastasis from visceral tumors: 0.2% and 10.4%.
- Breast>Lung>GI> Melanoma> Kidney

Report

Cutaneous metastasis: clinicopathological study of 72 patients from a tertiary care center in Lebanon

Jinane El Khoury¹, MD, Ibrahim Khalifeh², MD, Abdul-Ghani Kibbi¹, MD, and Ossama Abbas¹, MD

Departments of ¹Dermatology and
²Pathology and Laboratory Medicine,
American University of Beirut Medical
Center, Beirut, Lebanon

Correspondence

Ossama Abbas, MD
Department of Dermatology
American University of Beirut Medical
Center
PO Box 11-0236
Riad El-Solh
Beirut 1107 2020
Lebanon
E-mail: oa09@aub.edu.lb

Conflicts of interest: None.

doi: 10.1111/j.1365-4632.2012.05650.x

Abstract

Background Cutaneous metastasis is the result of malignant cell spread from primary malignancy to the skin. This is not uncommon, and rates reported in the literature are as high as 10.4%. To the best of our knowledge, there are no studies assessing the epidemiologic, clinical, and histopathological features of cutaneous metastasis in our region.

Objective To assess the clinical and histopathological findings of all patients diagnosed with cutaneous metastasis at the American University of Beirut – Medical Center (AUB-MC) and to compare our findings with those published in the literature.

Methods Retrospective clinical and histopathologic evaluation of all cases diagnosed as cutaneous metastasis at AUB-MC between 1992 and 2010.

Results A total of 72 patients (50 females and 22 males) were identified. The mean age at diagnosis was 55.2 years. The most common primary cancer was breast cancer in women and laryngeal cancer in men. The most common clinical presentation was a single nodule in 27% of cases followed by multiple nodules in 23%. Cutaneous metastasis lesions were asymptomatic in the majority. The chest was the most commonly affected site. On microscopy, the majority of metastatic cases were adenocarcinomas (74%).

Conclusion This is, to our knowledge, the first study characterizing the epidemiological, clinical, and histopathological features of cutaneous metastasis in the Lebanese population. The clinical and histopathological features observed were in concordance with the published literature, with minor differences.

Table 2 Cutaneous metastasis distribution

Primary cancer	Number of cases	Total, %
Cutaneous metastasis in female patients		
Breast carcinoma	41	82
Colorectal cancer	2	4
Ovarian carcinoma	1	2
Vulvar carcinoma	1	2
Endometrial carcinoma	1	2
Lung carcinoma	1	2
Renal cell carcinoma	1	2
Other	2	4
Cutaneous metastasis in male patients		
Laryngeal carcinoma	4	18
Lung carcinoma	2	9
Melanoma	3	14
Renal cell carcinoma	1	5
Follicular thyroid carcinoma	2	9
Colorectal carcinoma	2	9
Oropharyngeal carcinoma	1	5
Gastric carcinoma	2	9
Unknown primary	3	14
Other	2	9

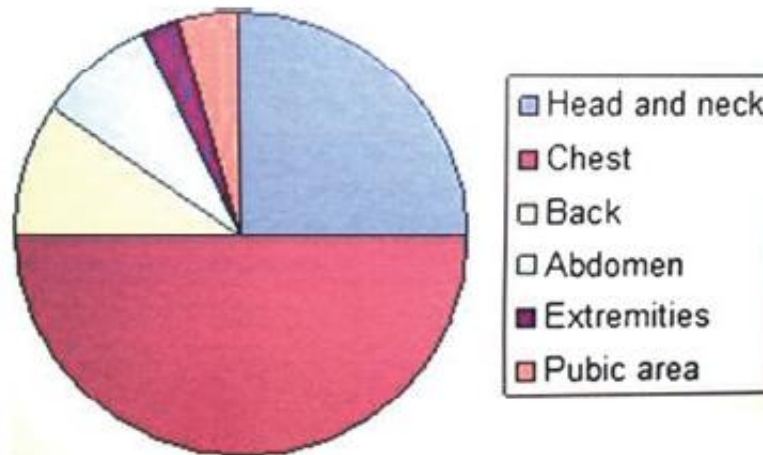


Figure 2 Anatomical distribution of cutaneous metastasis

Table 3 Mean time to metastasis in years

Primary cancer	Mean time to metastasis (years)
Breast carcinoma	2.93
Colorectal cancer	1.73
Ovarian carcinoma	3.58
Vulvar carcinoma	4.42
Endometrial carcinoma	0.08
Lung carcinoma	0.67
Renal cell carcinoma	0.08
Laryngeal carcinoma	1.50
Melanoma	1.00
Follicular thyroid carcinoma	16.09
Oropharyngeal carcinoma	0.75
Gastric carcinoma	0.00

Metastatic RCC

- **More in males**
- **Scalp**
- **Generally poor prognosis**
- **Survival following metastatic RCC was 7 months**
- **Metachronous metastatic RCC can occur**

Differential Diagnosis

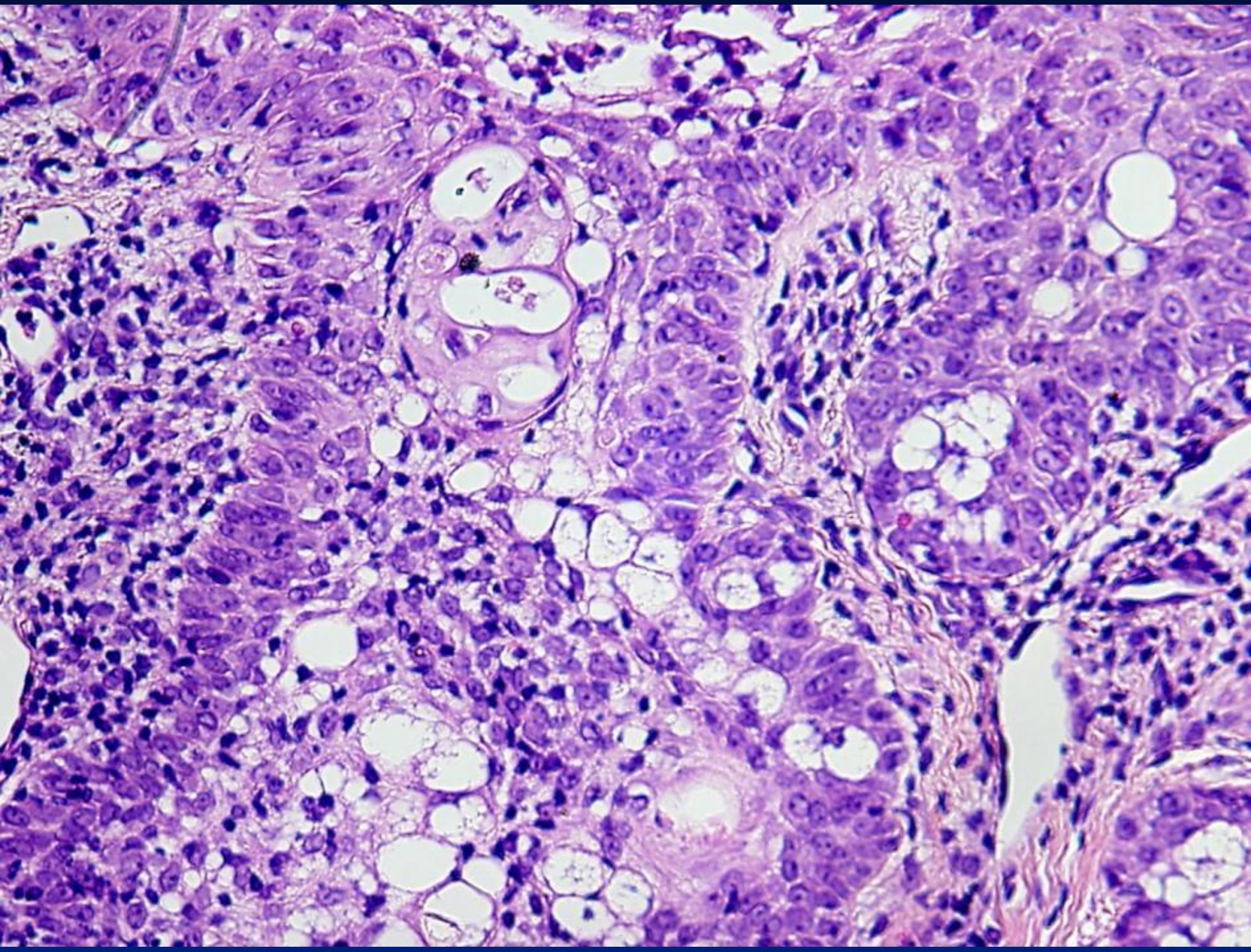
- **Metastatic melanoma**
 - **Vascularity/hemorrhage in RCC**
 - **Some may show epidermotropism**
 - **Pigment**

Differential Diagnosis

- Squamous cell carcinoma
 - Keratohyaline granules
 - Intercellular bridges
 - Keratin pearls

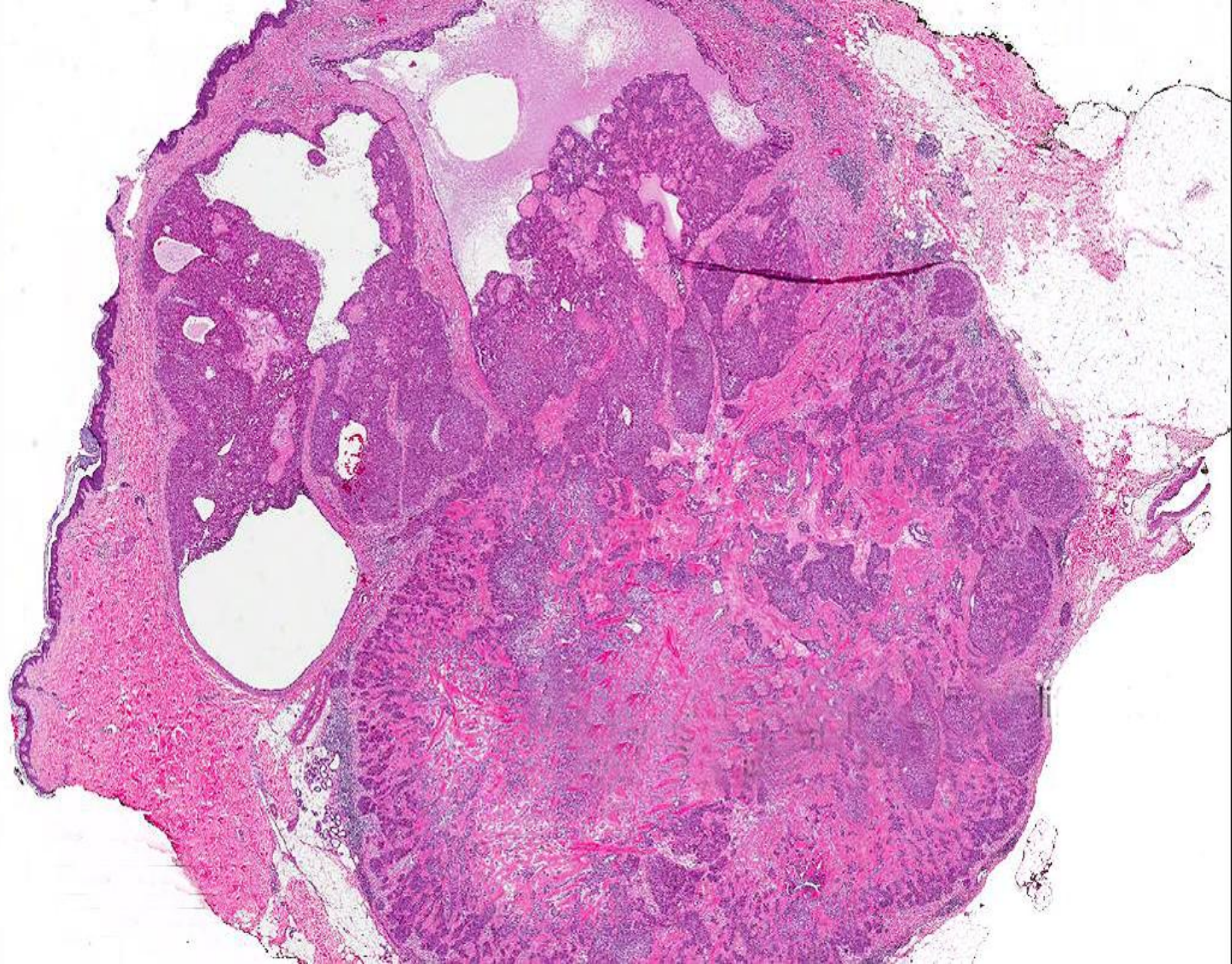
Differential Diagnosis

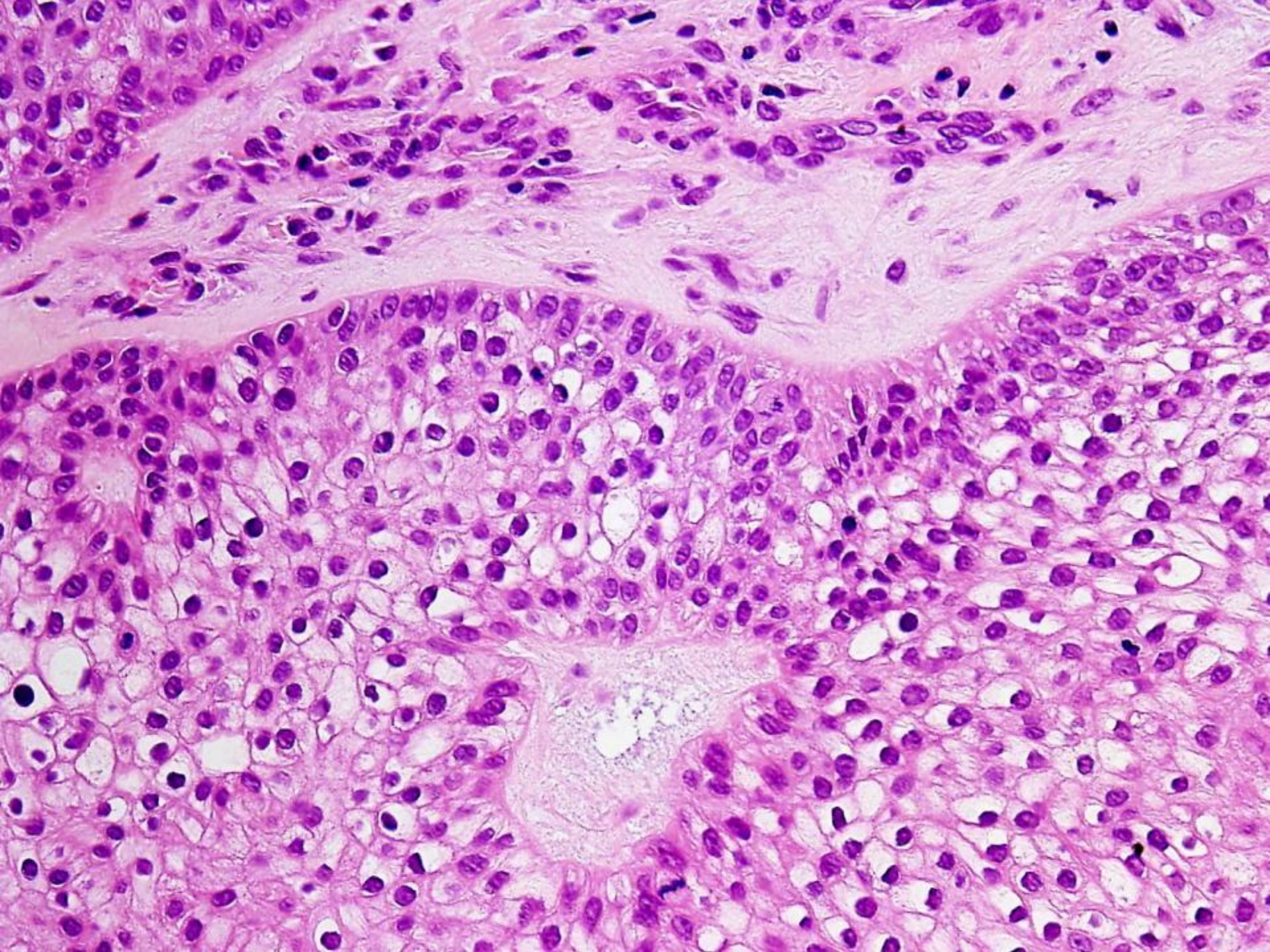
- **Sebaceous neoplasms**
 - **Scalloped nuclei in sebaceous neoplasms**



Differential Diagnosis

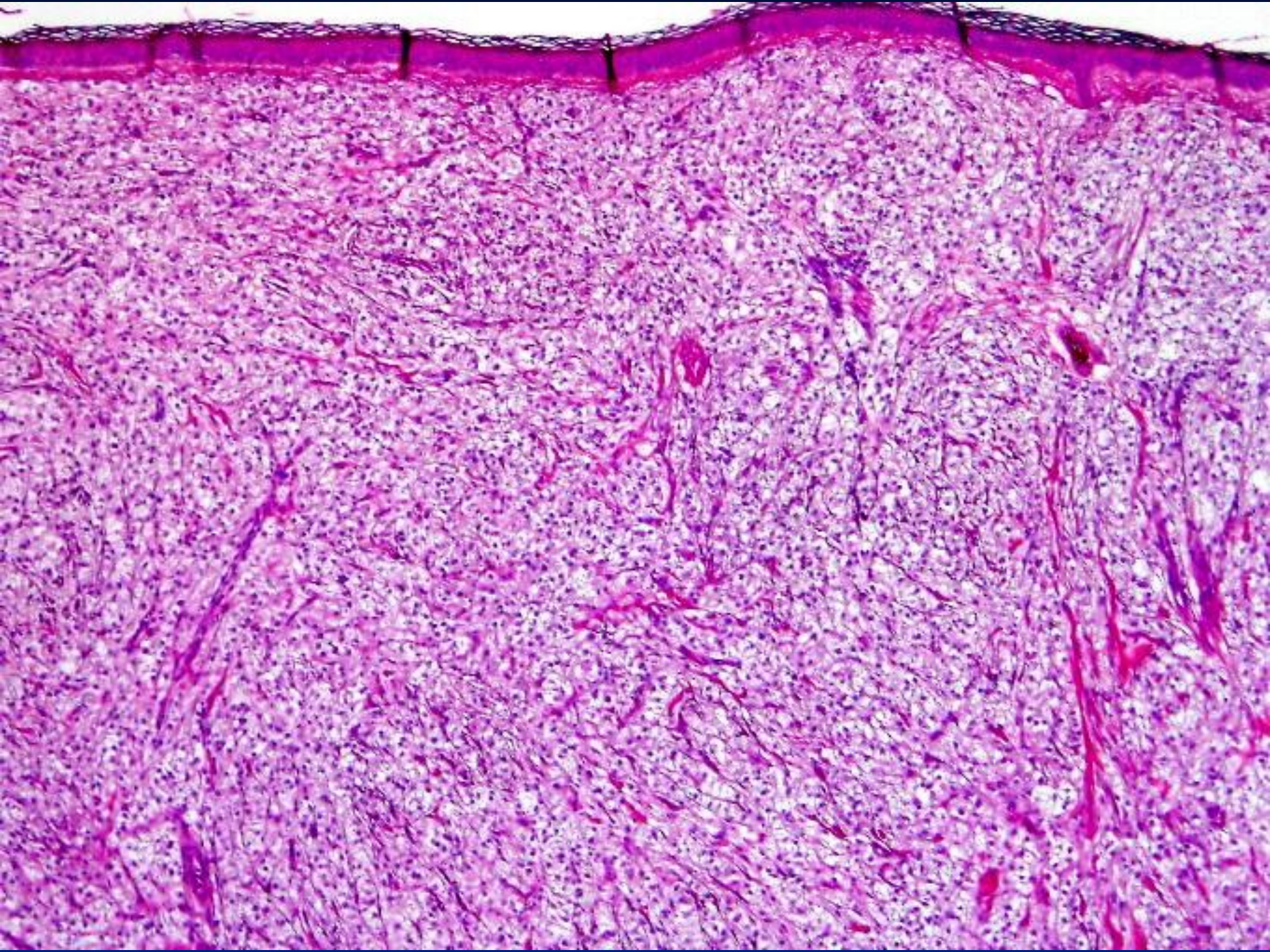
- **Adnexal neoplasms (such as nodular hidradenoma)**
 - **Duct formation, squamoid areas, hyaline areas in hidradenoma**
 - **Peripheral palisading in trichilemmoma**

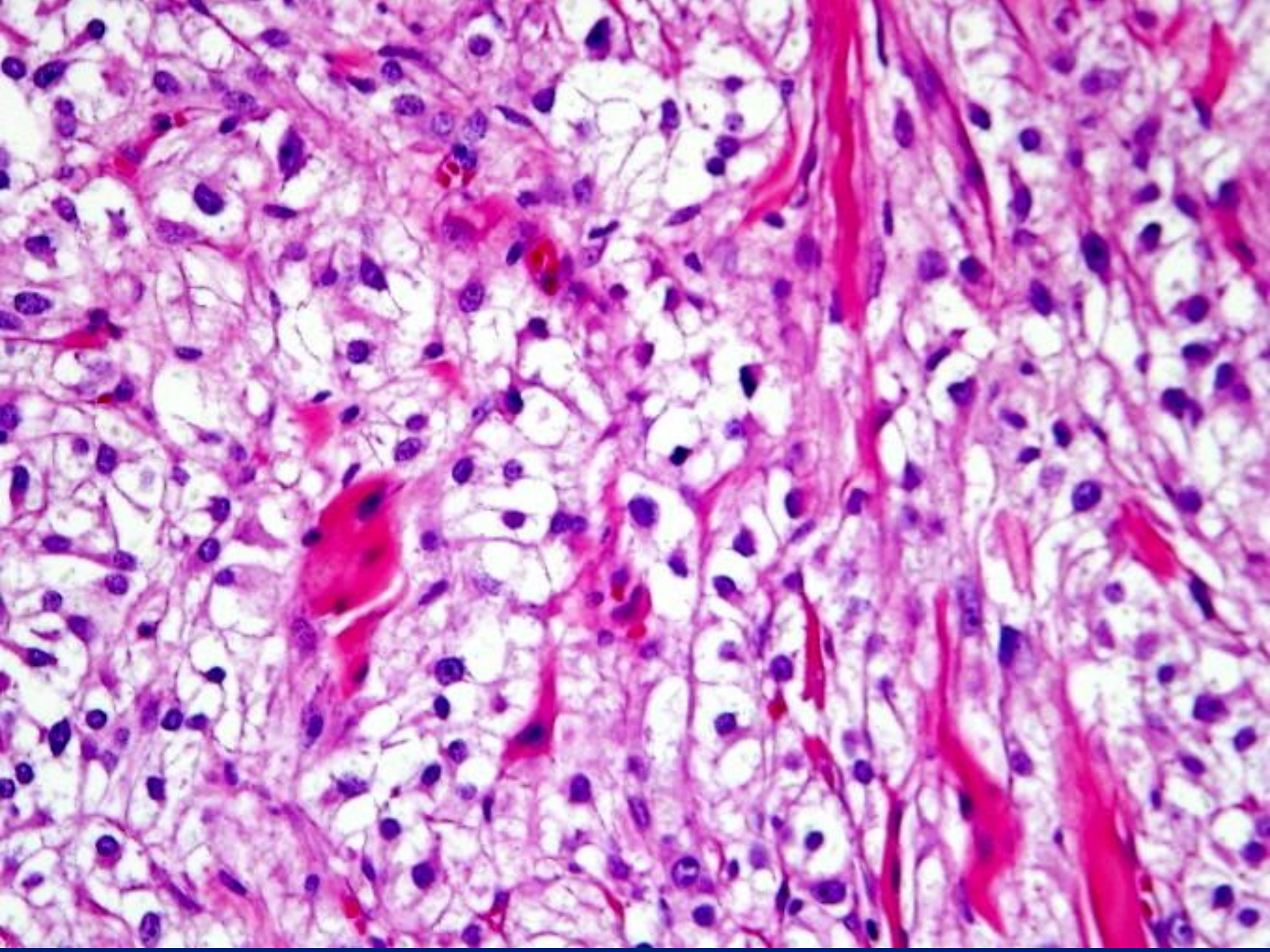




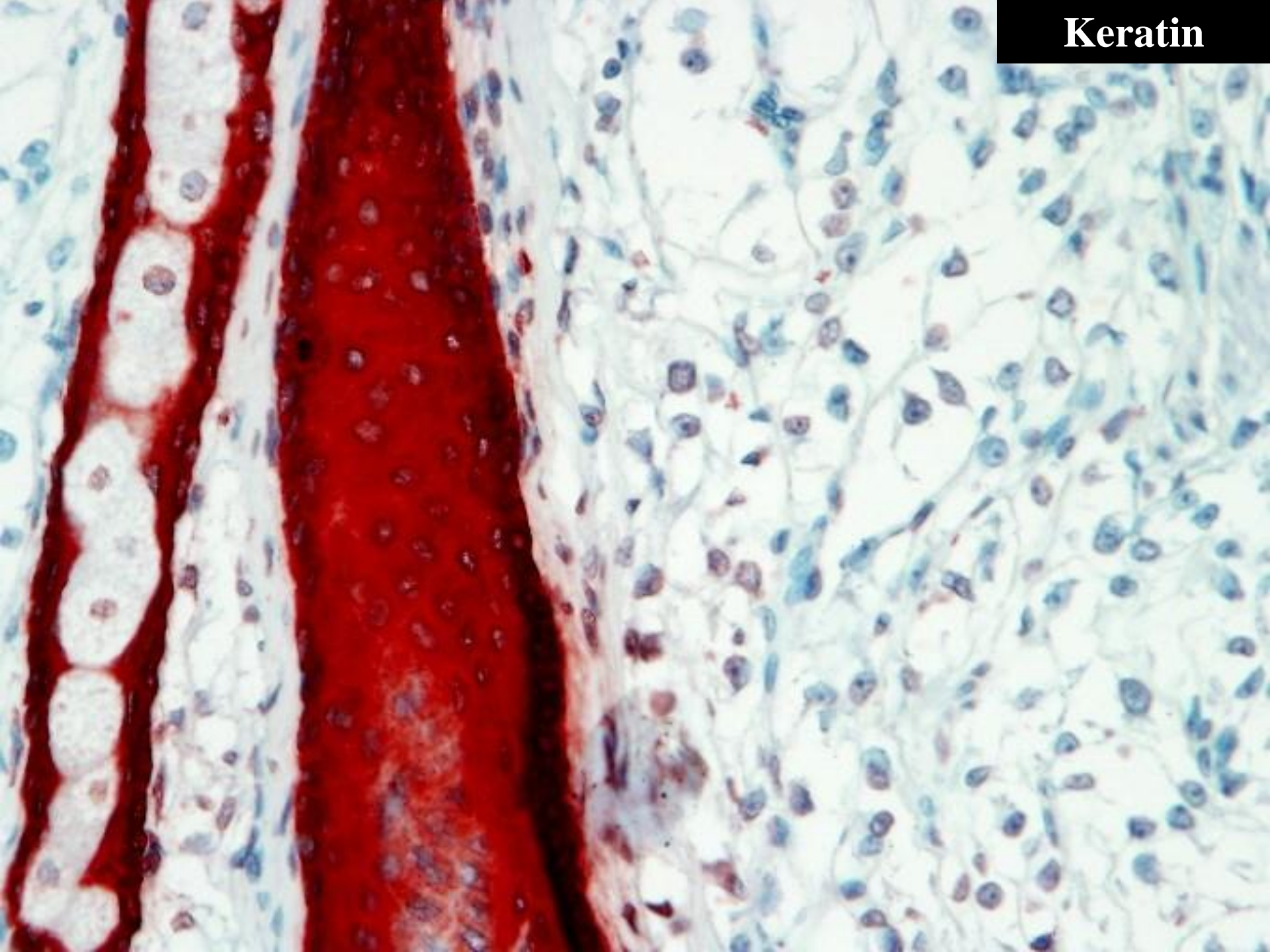
Differential Diagnosis

- **Xanthoma**
 - **Foamy cells**
 - **Lack of prominent vascularity/
hemorrhage**
 - **Pattern of CD10 positivity**





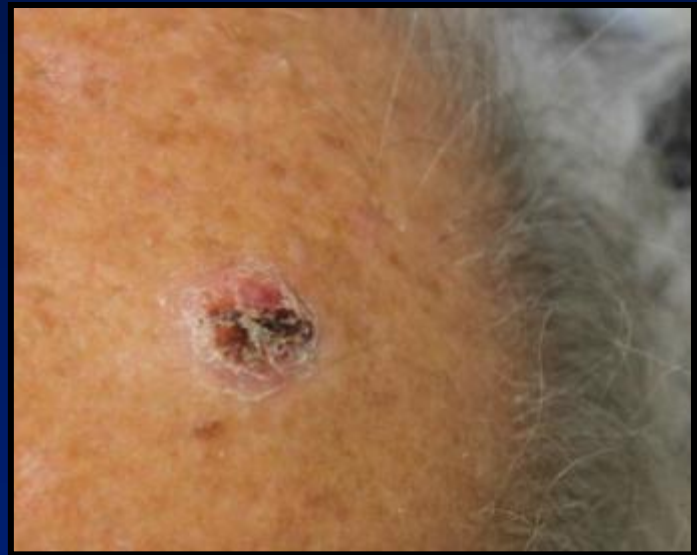
Keratin



Case 9

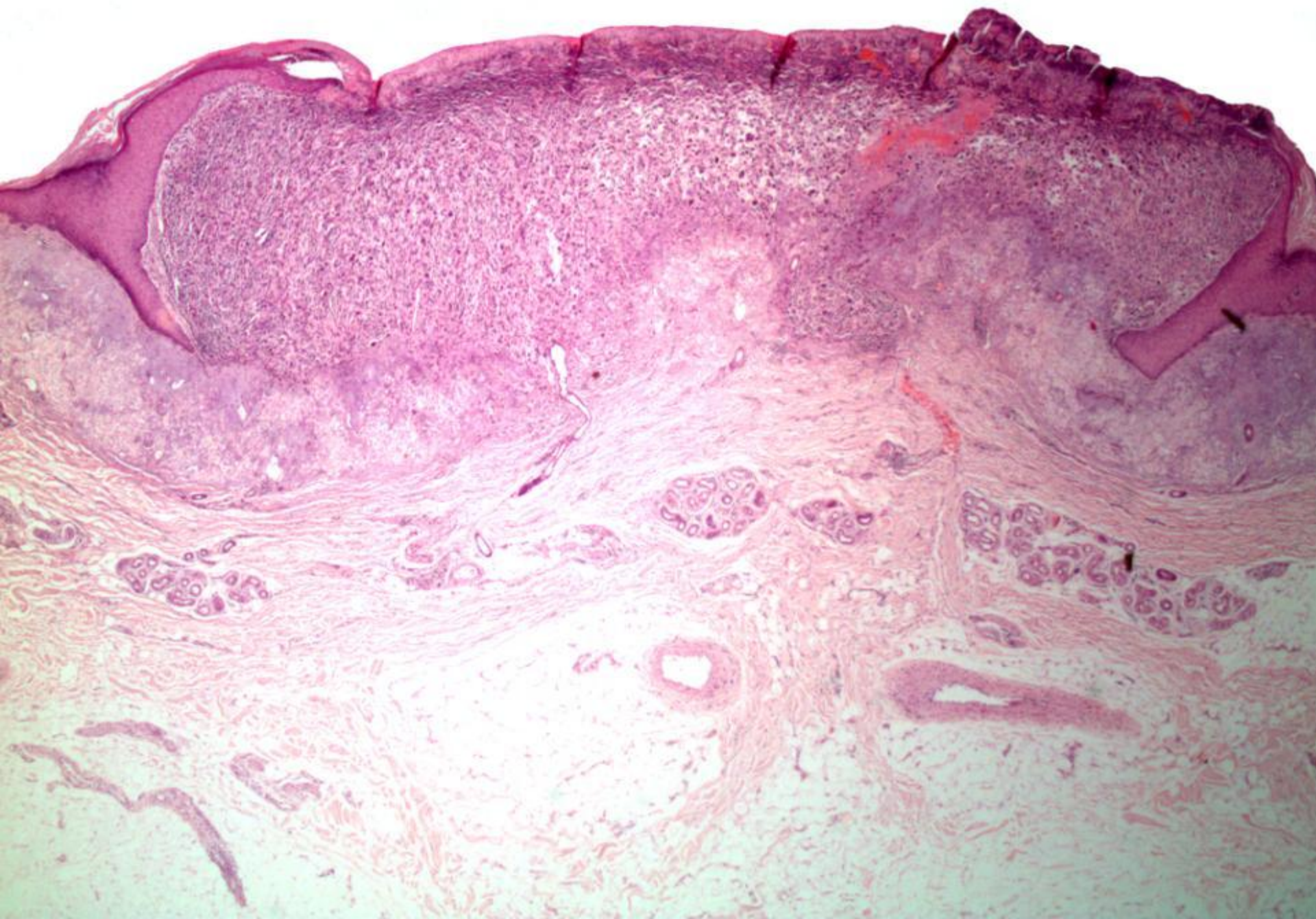
Clinical Data

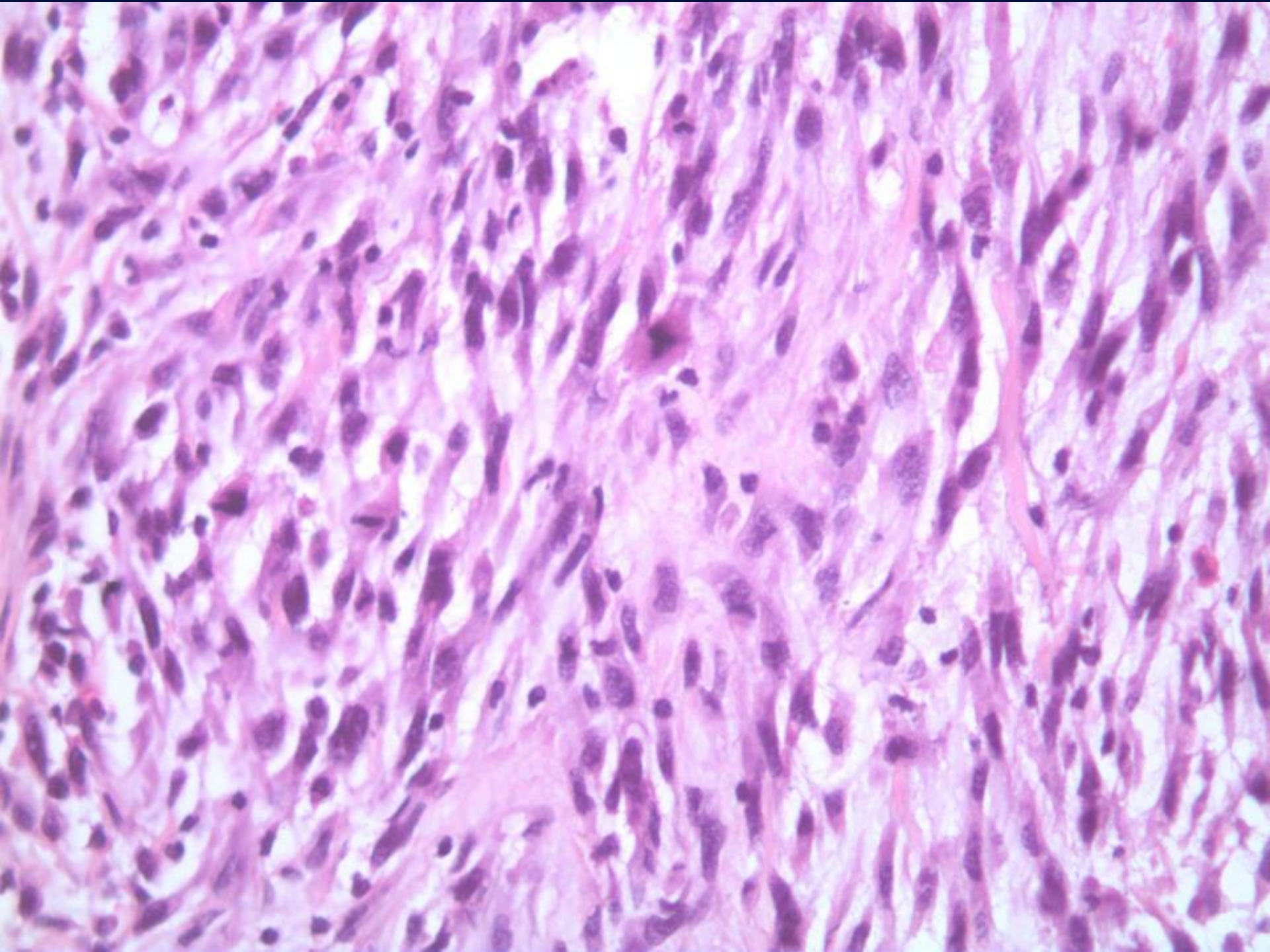
- 64-year-old man with growing lesion on the scalp

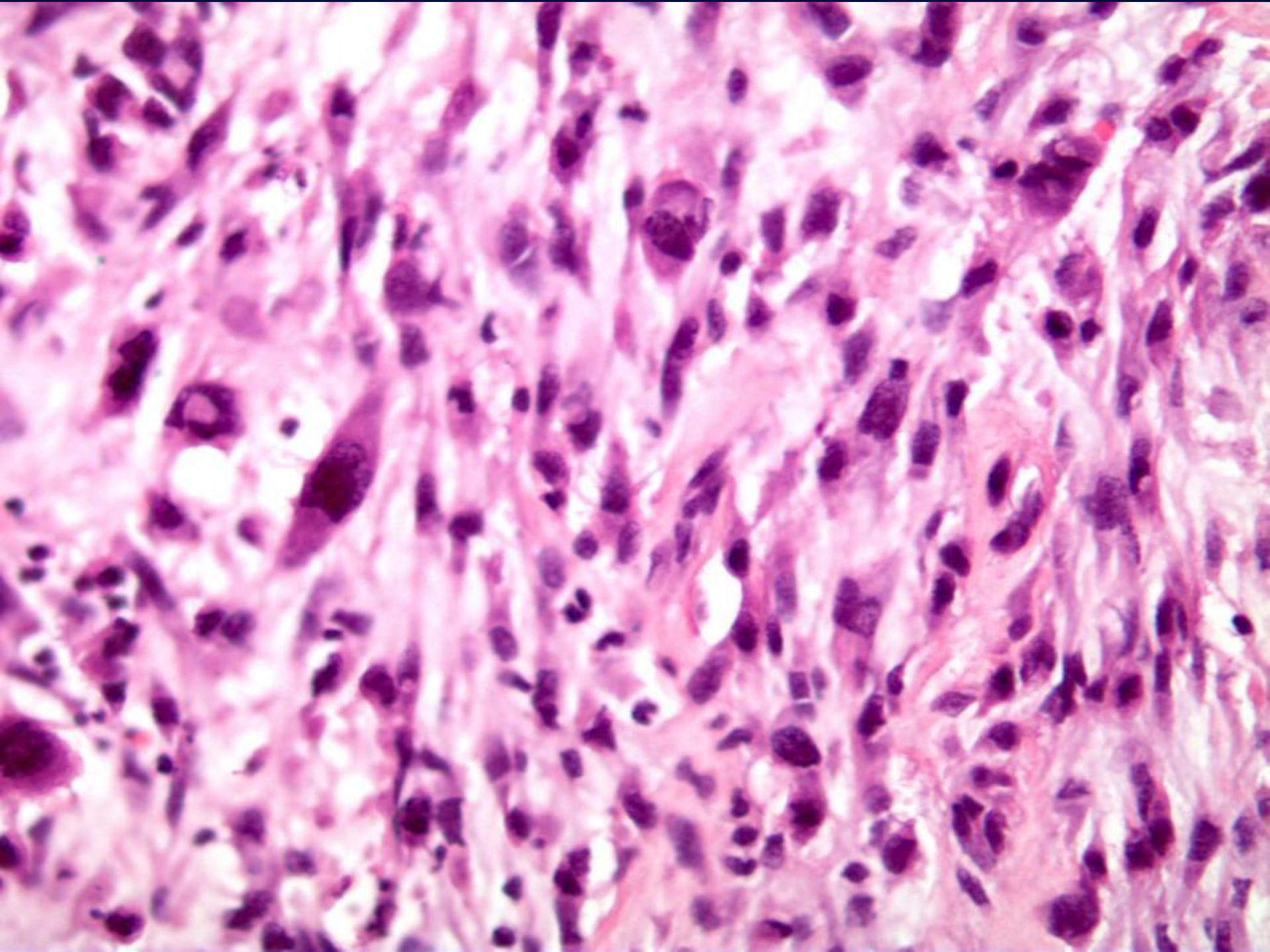


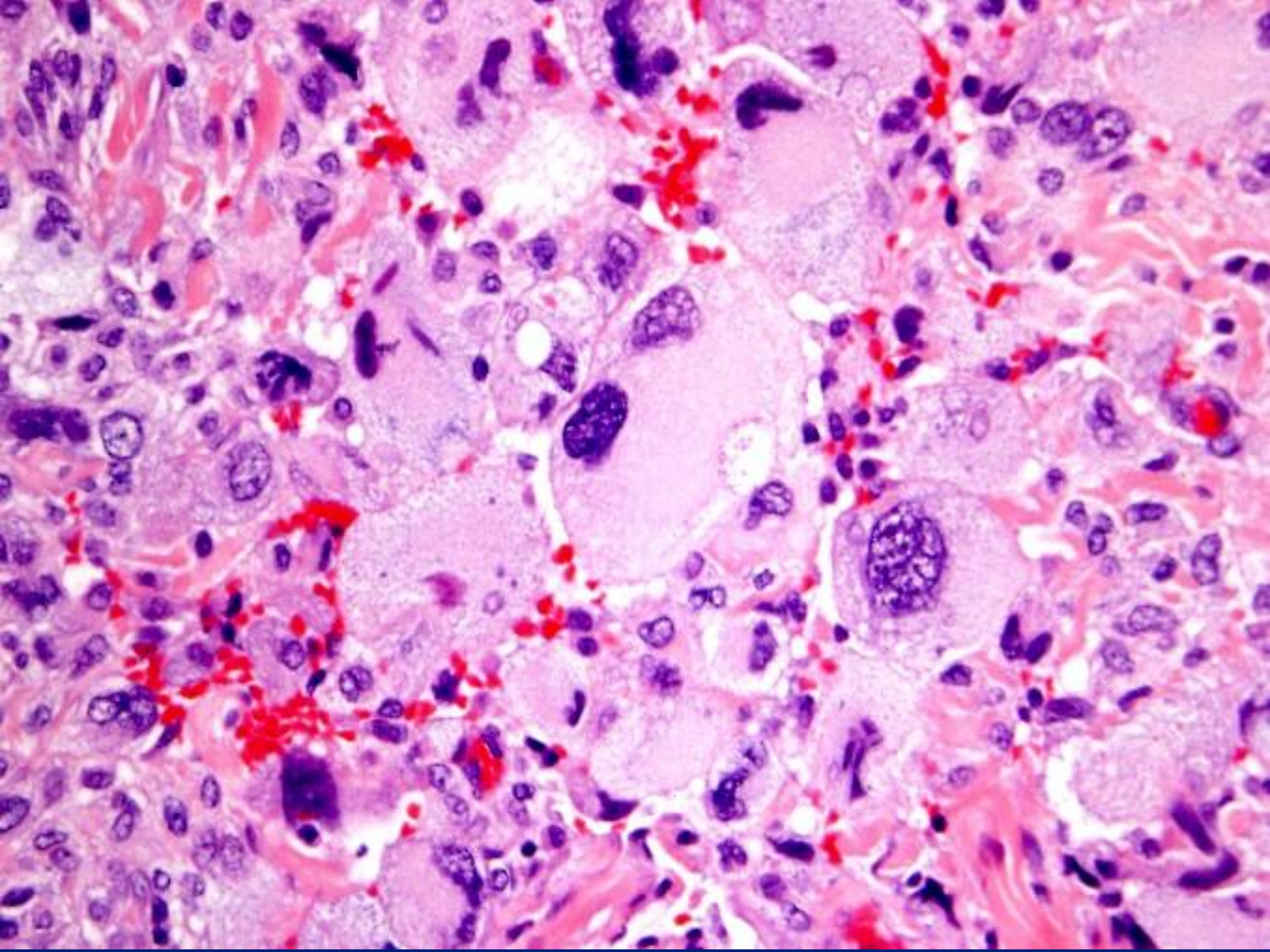
Gross description

- **Ellipse of skin measuring
(2 x 1.5 x 0.9 cm)**









Your Diagnosis?

A. Malignant melanoma

B. Sarcomatoid SCC

C. Atypical fibroxanthoma

D. Leiomyosarcoma

E. Pleomorphic sarcoma

Your Diagnosis?

A. Malignant melanoma

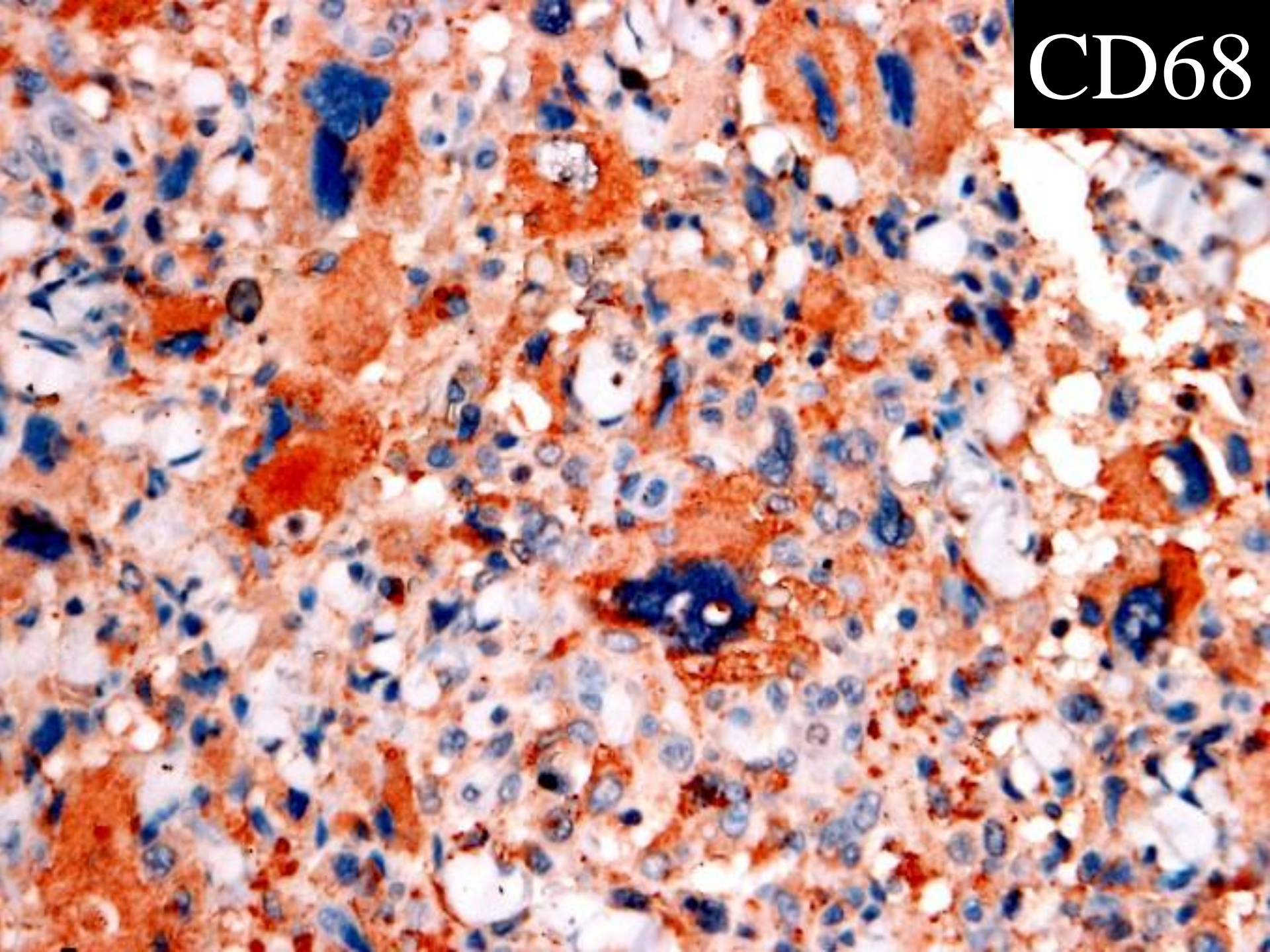
B. Sarcomatoid SCC

C. Atypical fibroxanthoma

D. Leiomyosarcoma

E. Pleomorphic sarcoma

CD68



Atypical Fibroxanthoma

- Sun-damaged skin of elderly (face, neck, hands)
- Rapidly growing, solitary nodule, often ulcerated (<3 cm)
- Benign course (absence of Ras mutations, pseudomalignant)
- Recurs in 5%

Histology

- **Marked cytologic atypia**
- **“Histiocytic” features:
epithelioid, foamy cytoplasm**
- **Fibrous and elastotic stroma**
- **No atypical cells in epidermis**
- **Centered in the dermis.**
- **SCT: Spared.**

AFX: IPOX

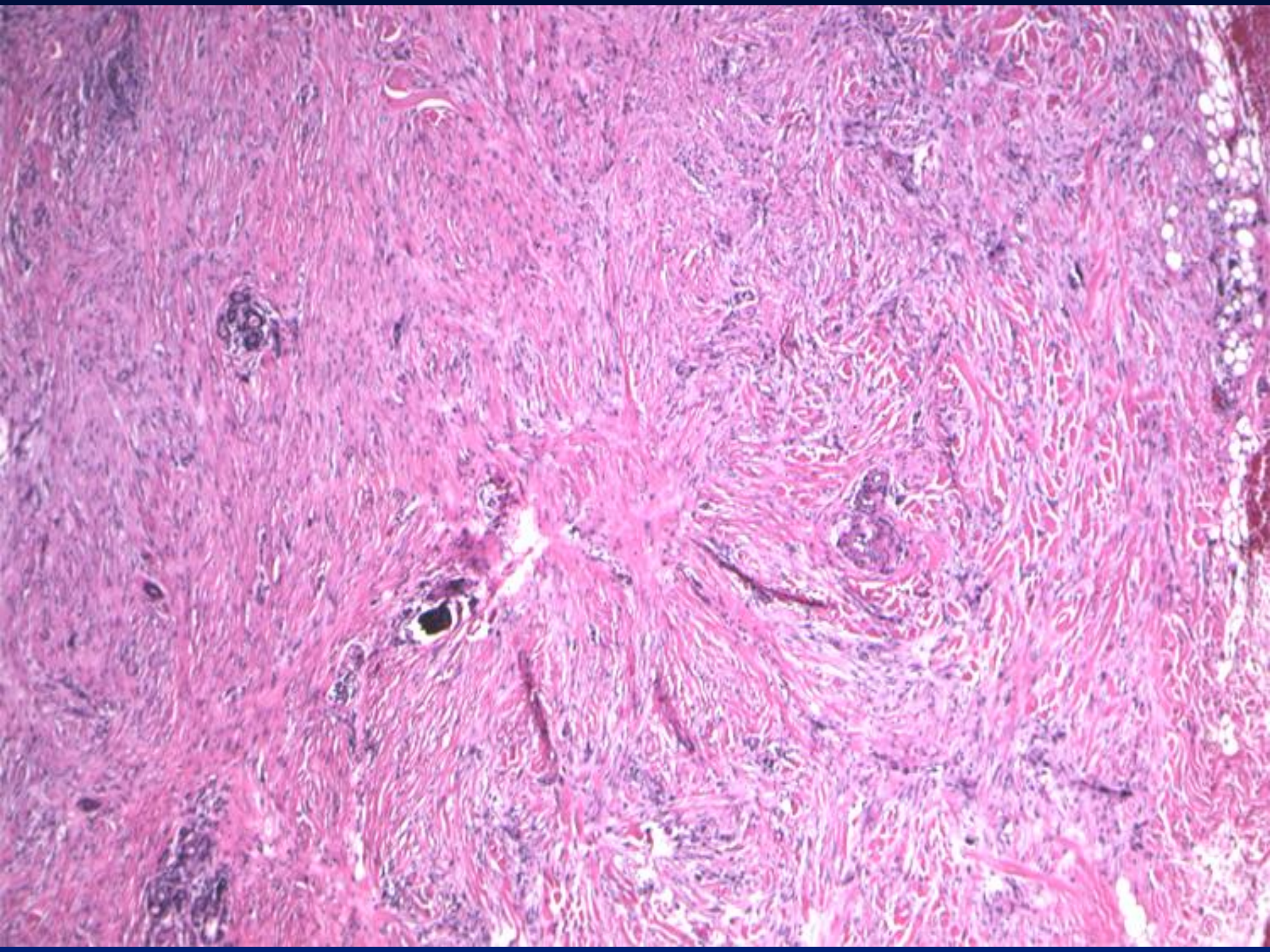
- **Macrophage markers: CD68, HAM-56, α_1 -antichymotrypsin, α_1 -antitrypsin**
- **Factor XIIIa: Positive.**
- **S100 & CK: Negative.**
- **gp100 (HMB45) & MART1: Negative (?).**

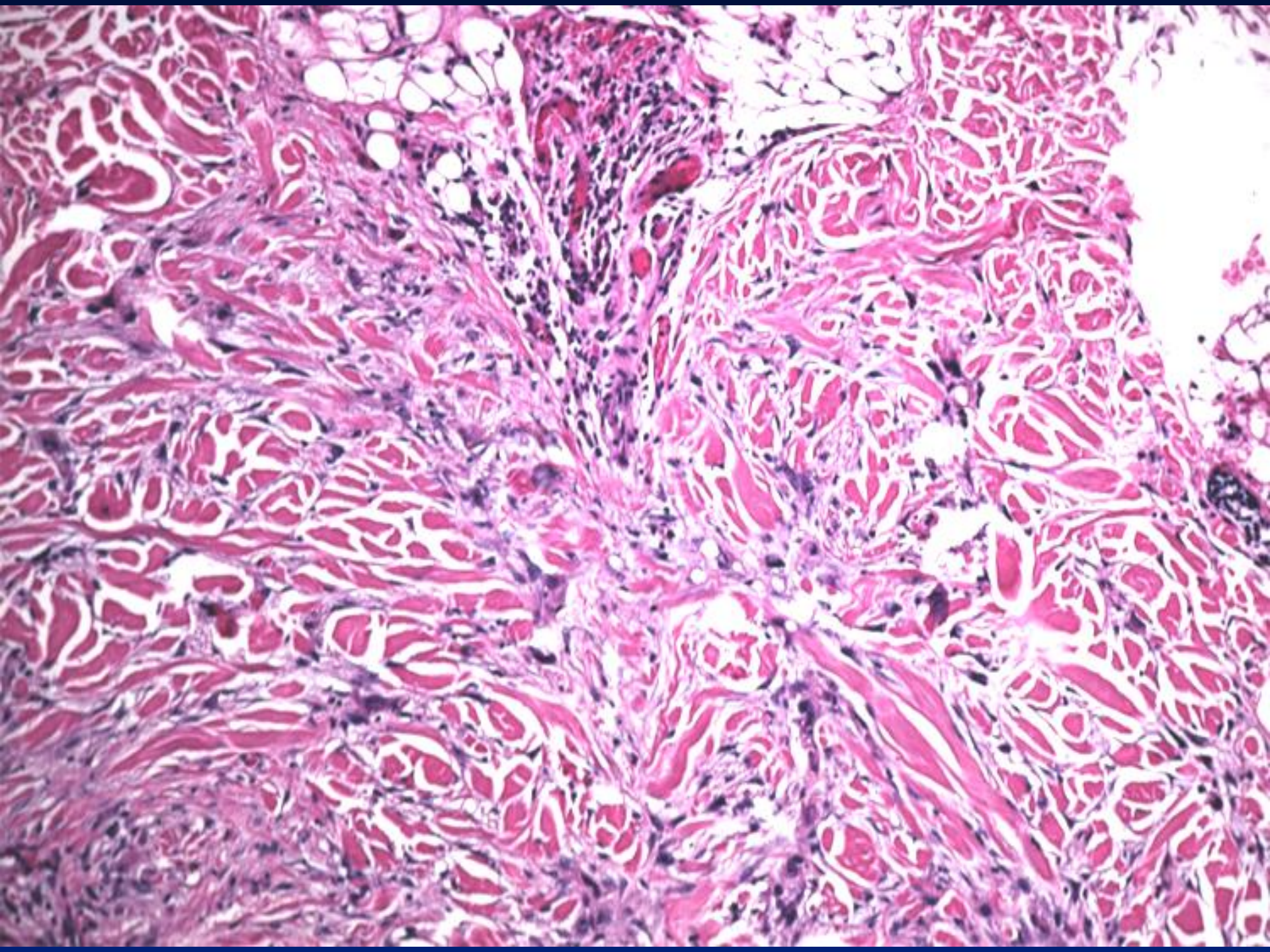
Differential Diagnosis of Atypical Fibroxanthoma

- Squamous cell carcinoma
- Malignant melanoma
- Leiomyosarcoma
- Malignant fibrous histiocytoma

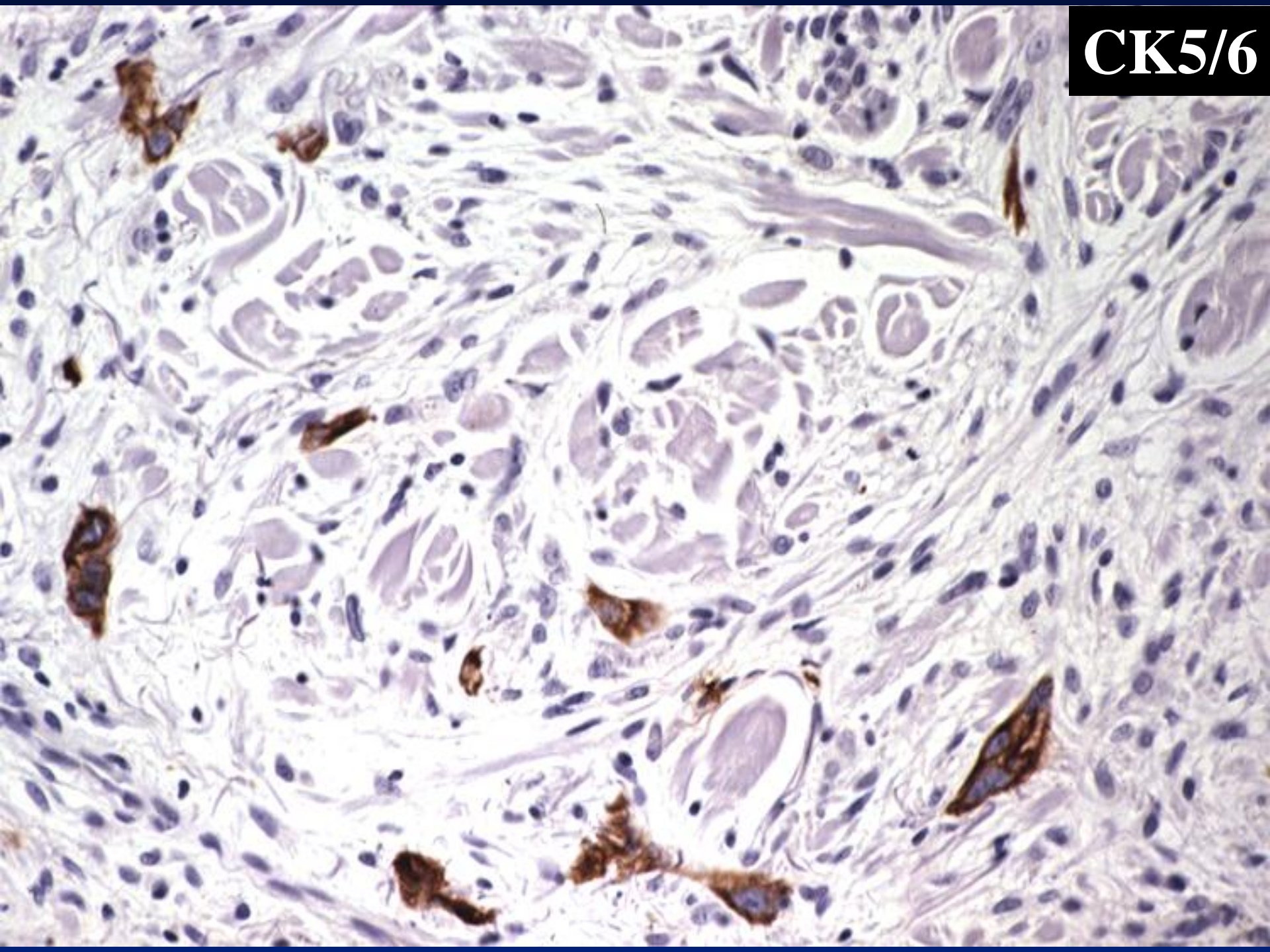
Differential Diagnosis: SCC

- SCC in-situ in overlying or adjacent epidermis
- IP: CK +



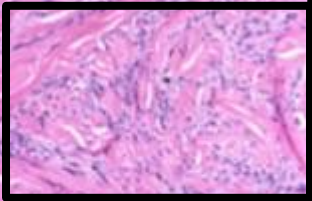
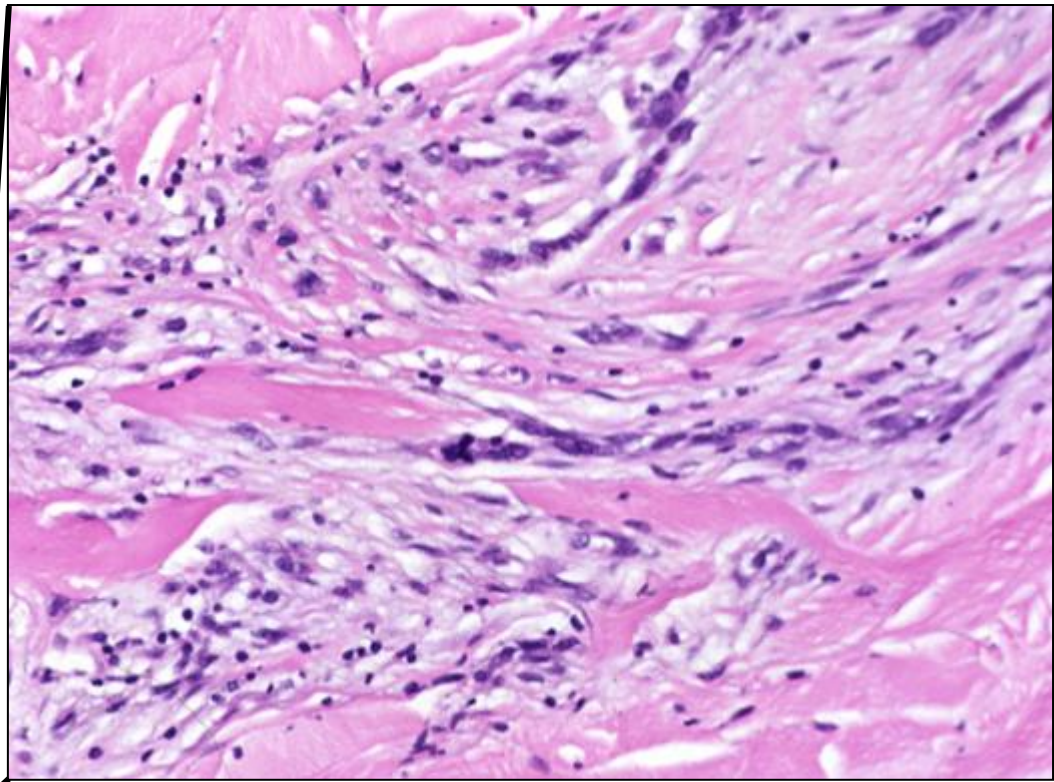
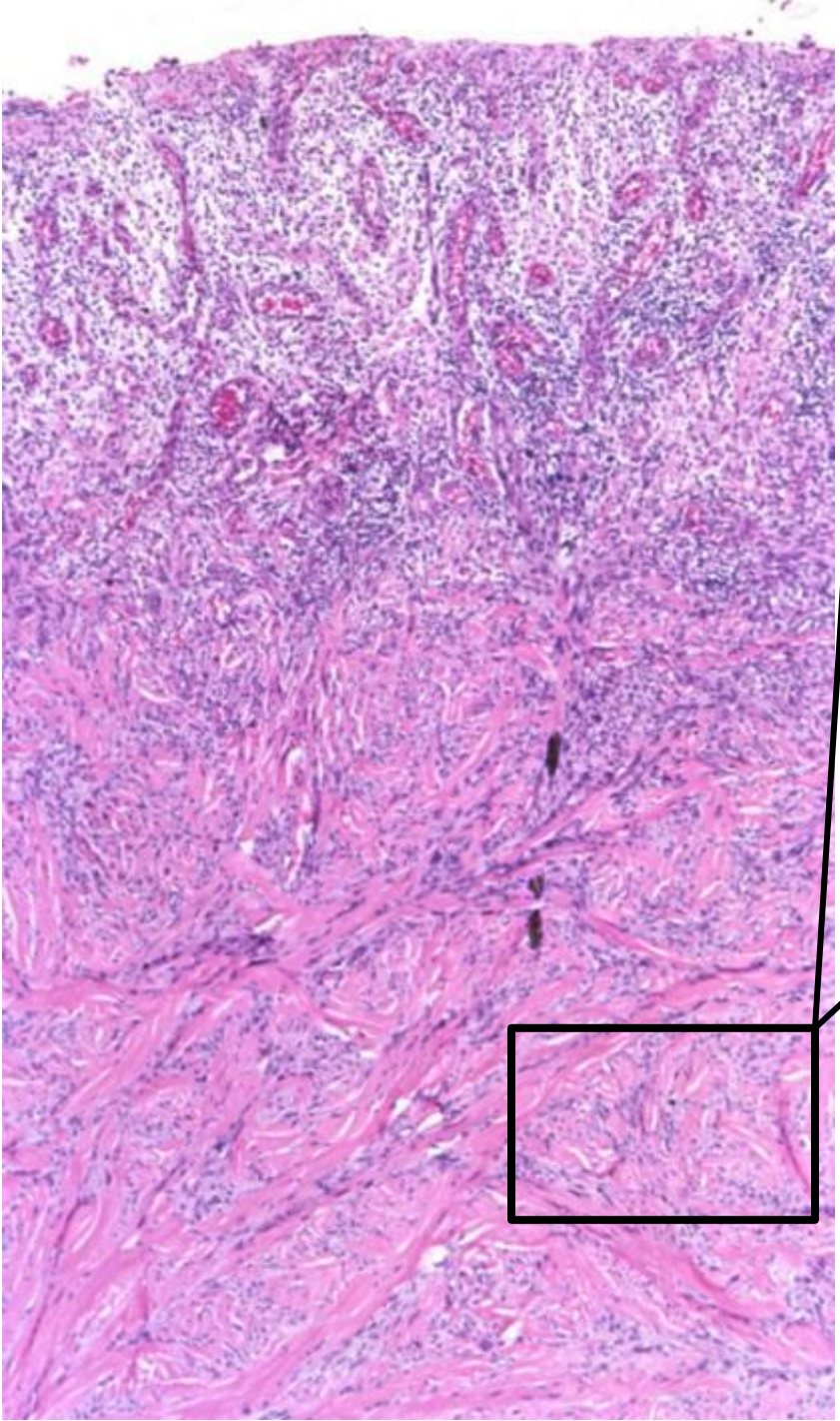


CK5/6

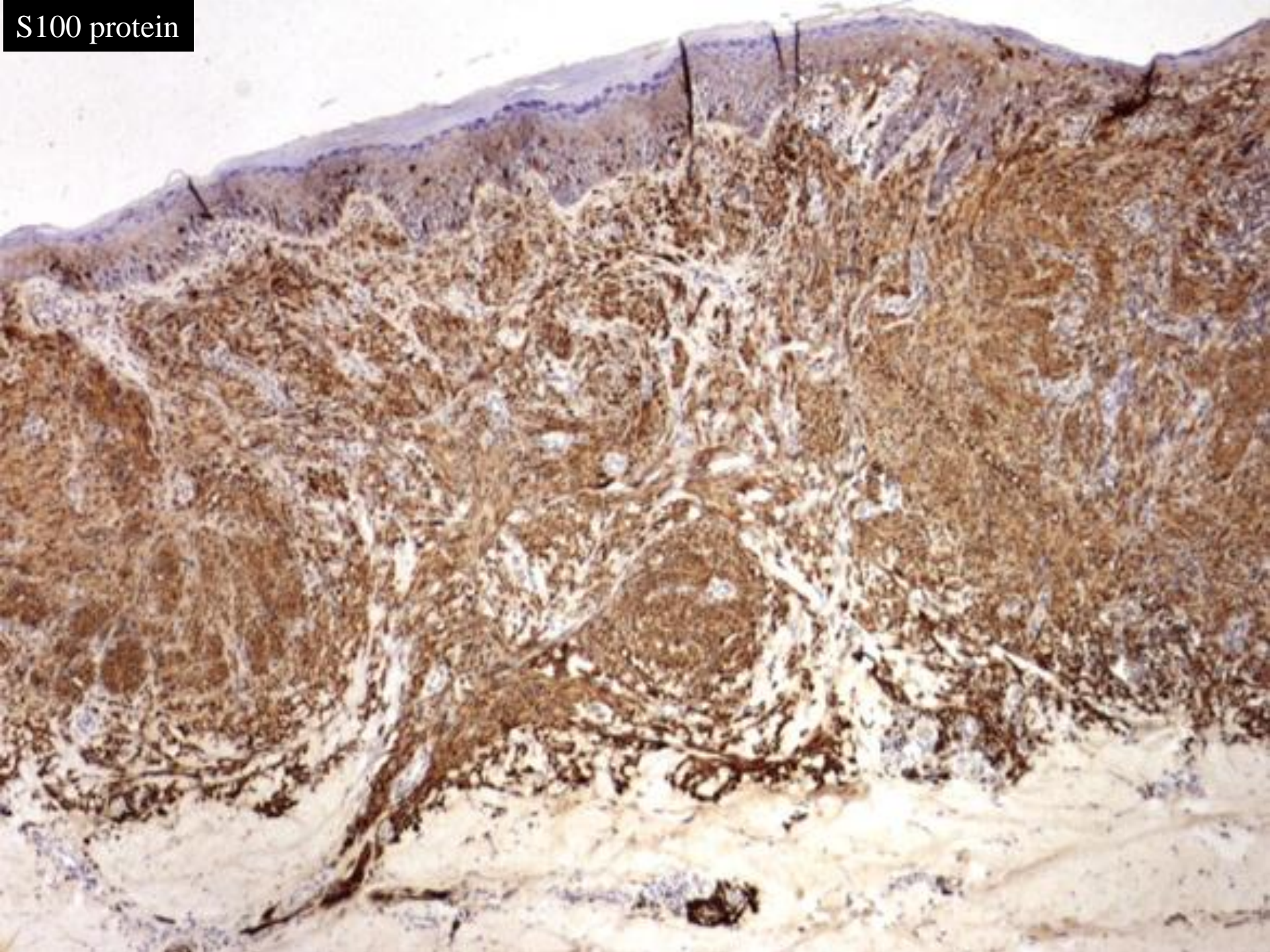

Differential Diagnosis: Malignant Melanoma

- Epidermal in-situ component usually nested or single-cell
- IP: S100 +
HMB45 and MART1 +/-



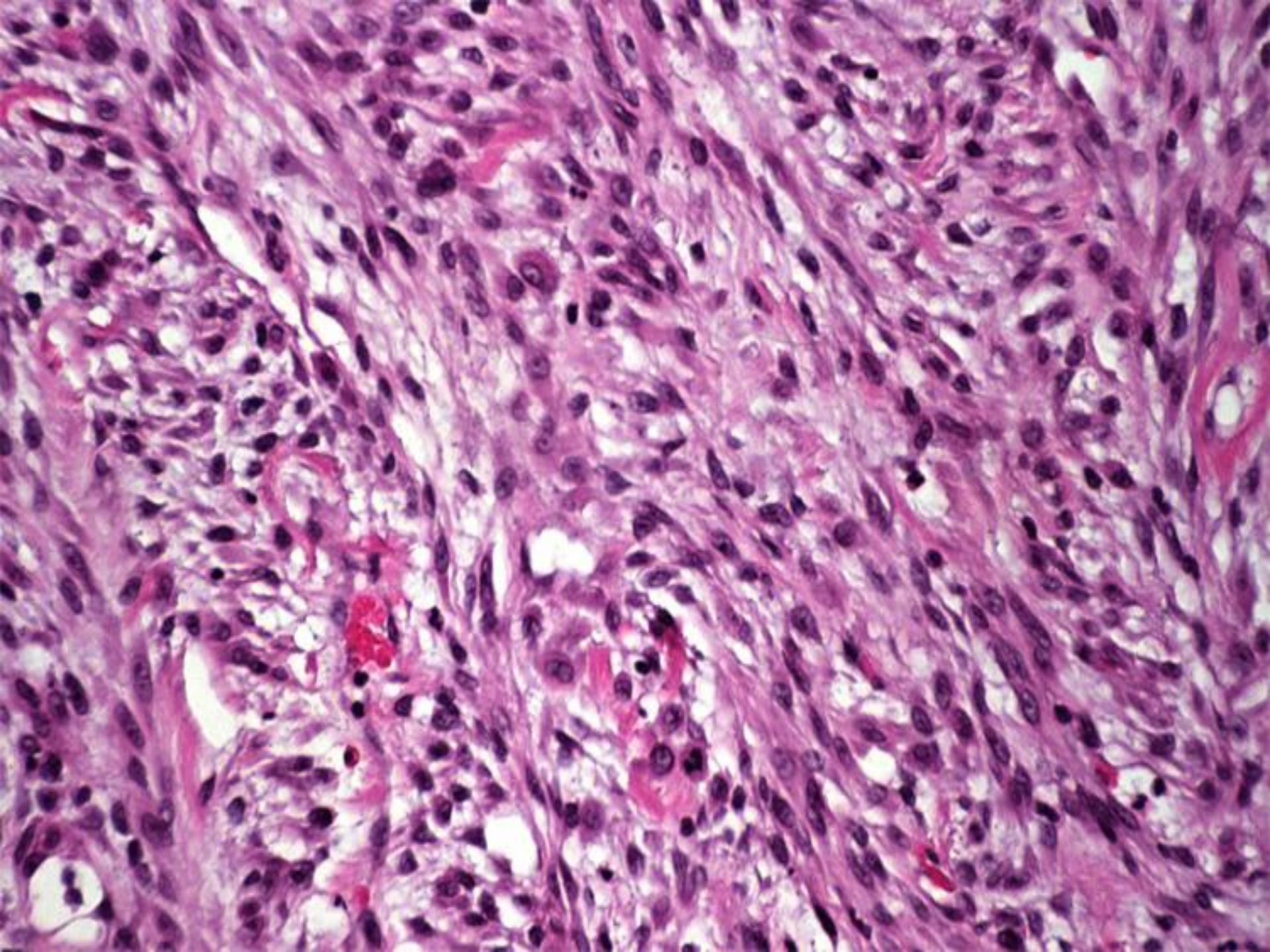
S100 protein



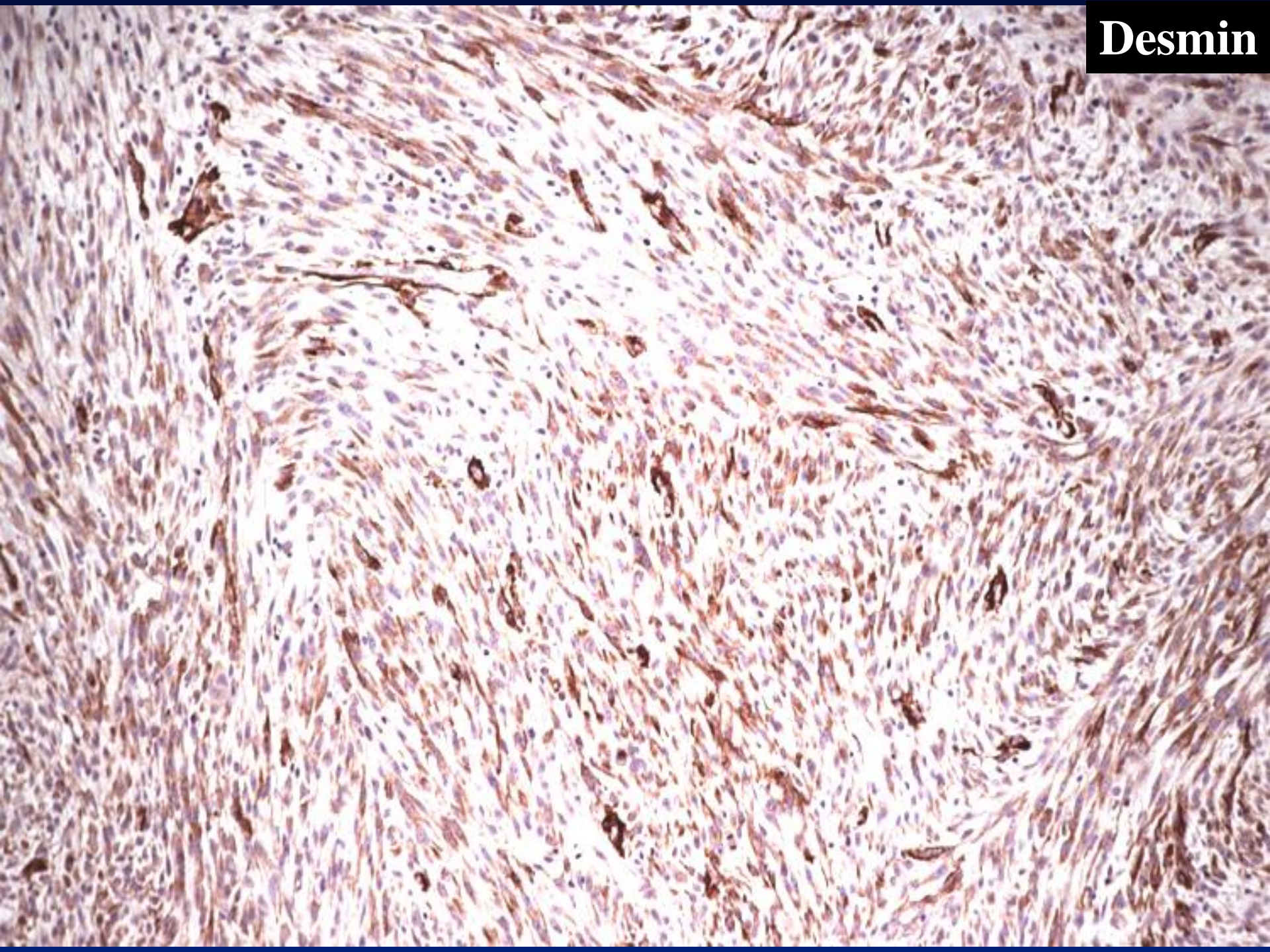
Differential Diagnosis

Leiomyosarcoma

- Short fascicles crossing at 90-degree angles
- Relative uniformity of cells
- IP: Actin, desmin +; rarely S100 +

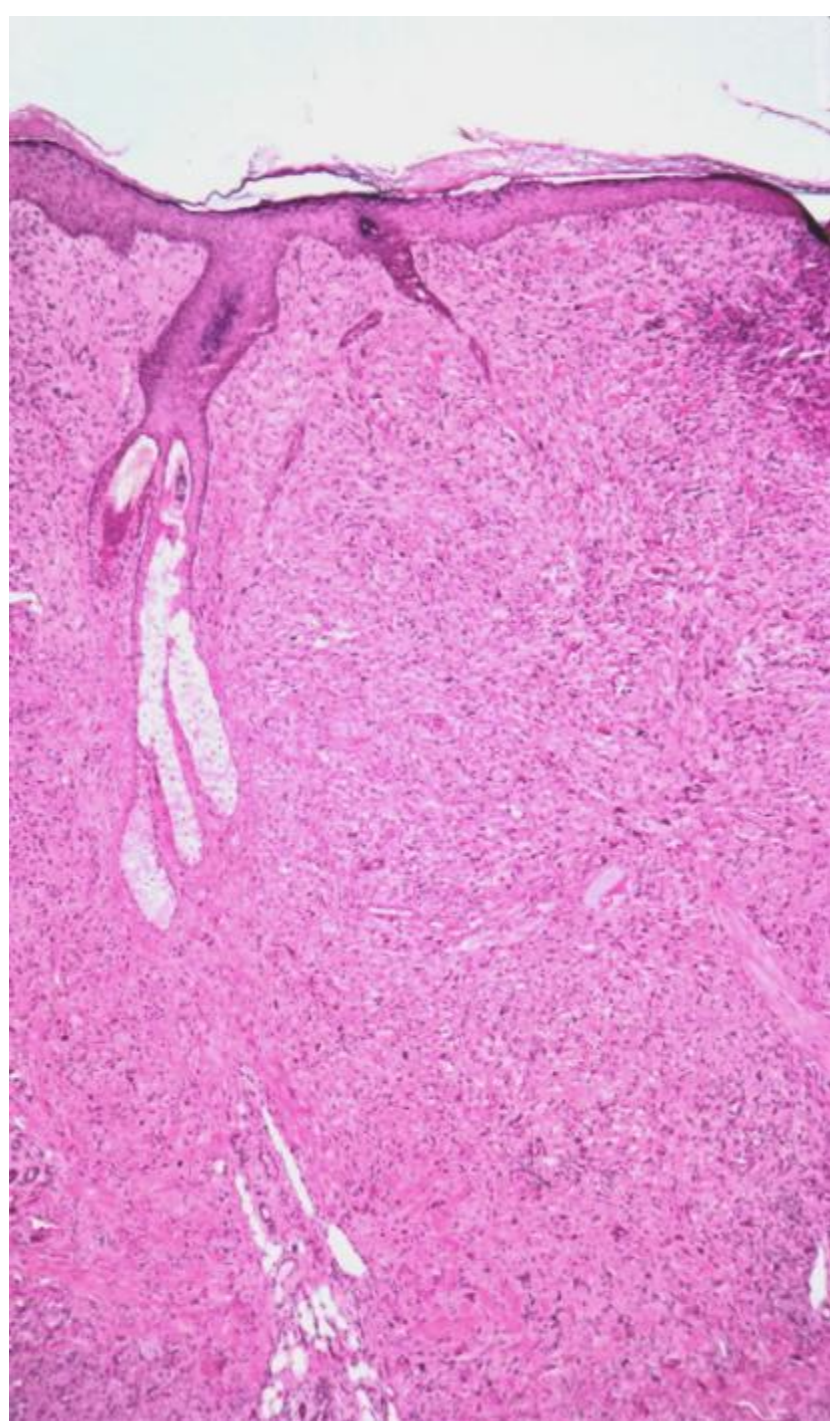


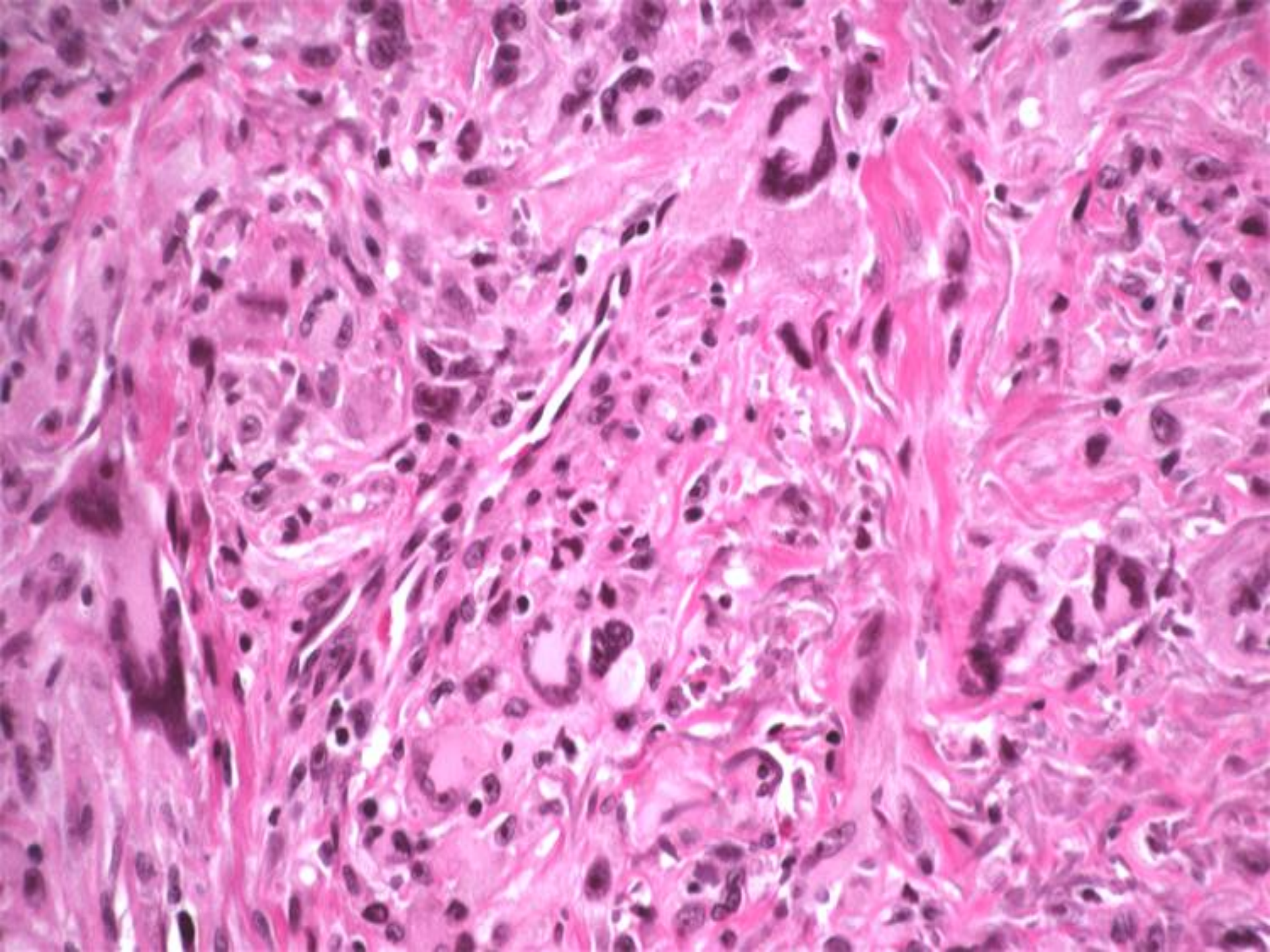
Desmin



Differential Diagnosis: MFH

- **Essentially a deeper form of AFX**
- **Controversial concept**
- **Infiltrates subcutis**
- **Vascular invasion**
- **Tumor necrosis**
- **History of immunosuppression**
- **More aggressive clinically**





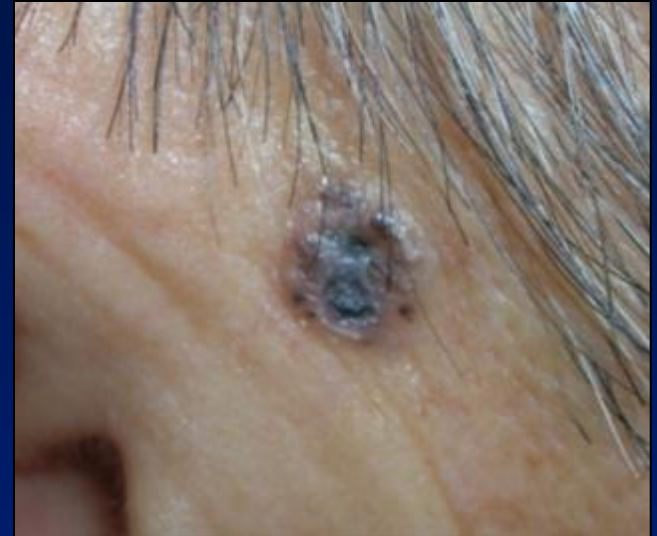
Key Points

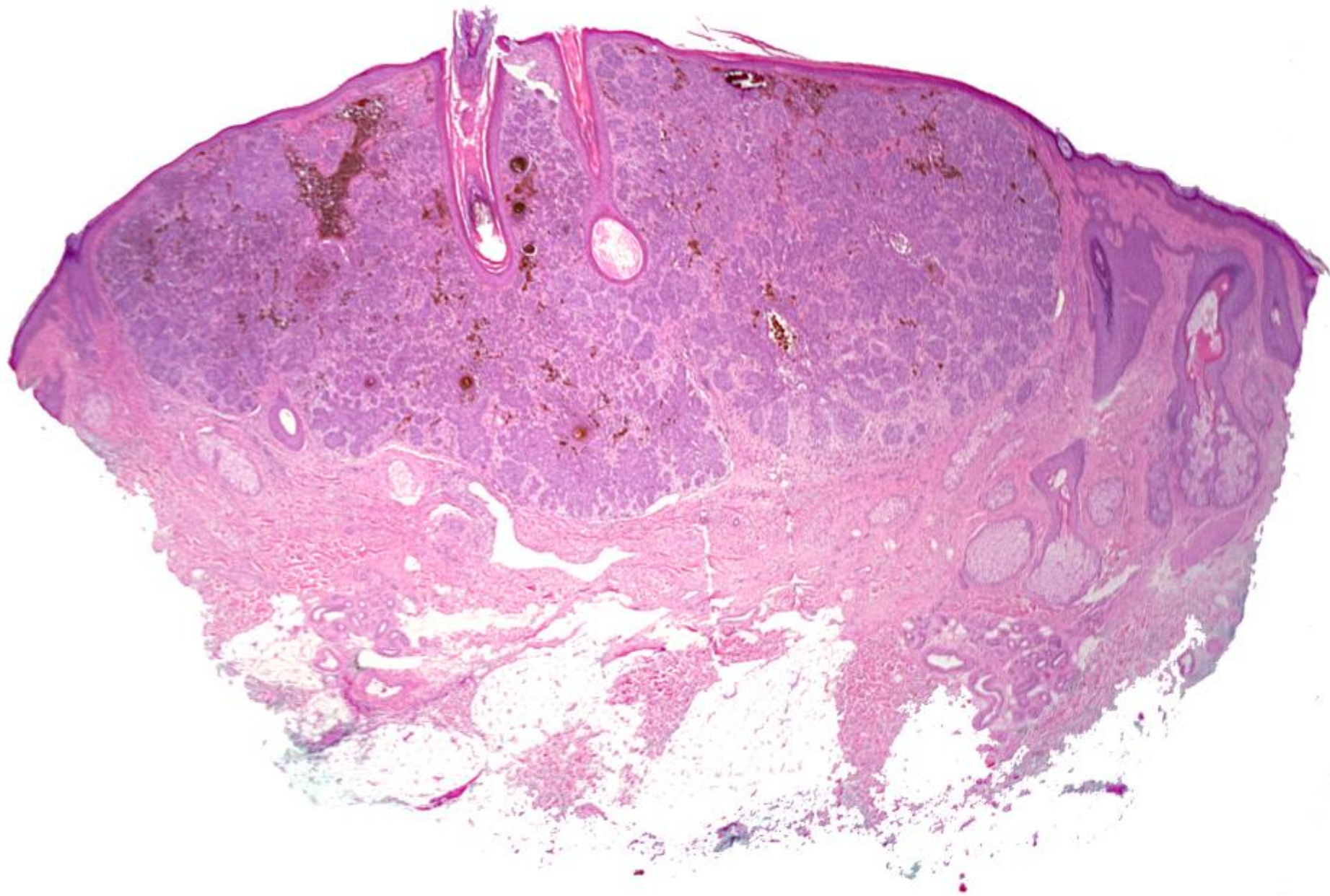
- **High-grade atypia, low-grade behavior**
- **Sun-related**
- **Mandatory to rule out SCC, MM, other sarcomas**
- **Centered in the dermis.**

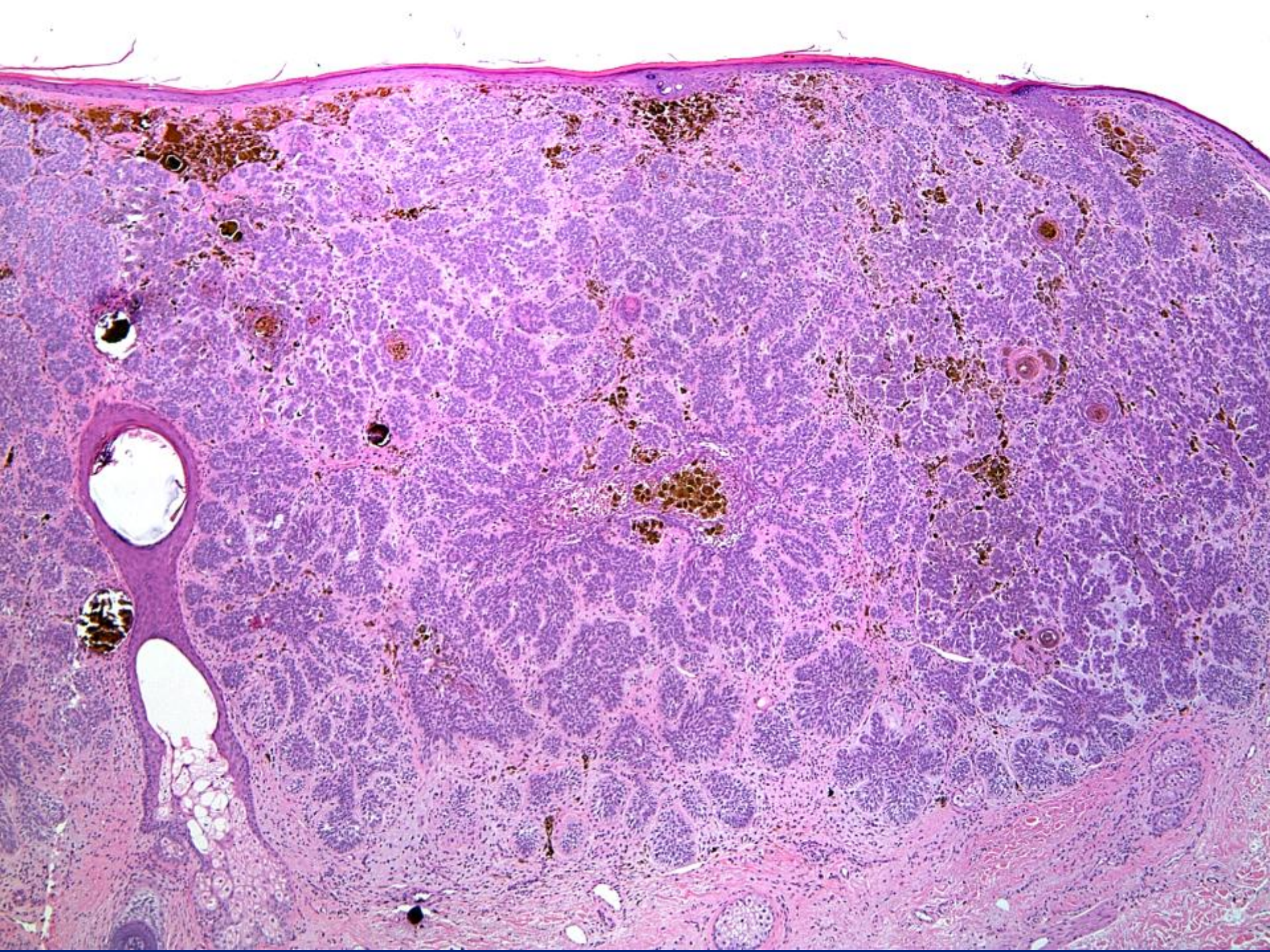
Case 10

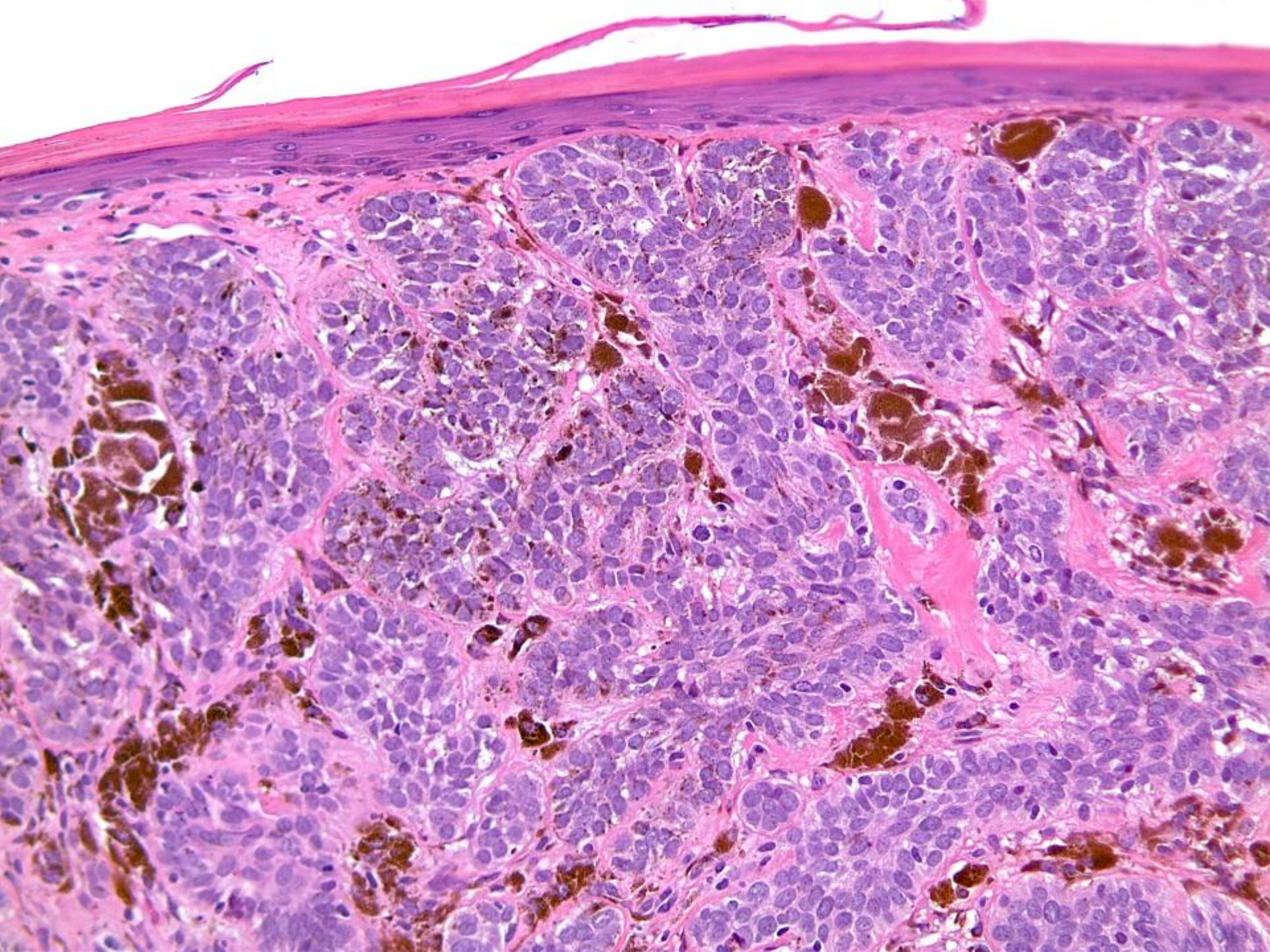
History

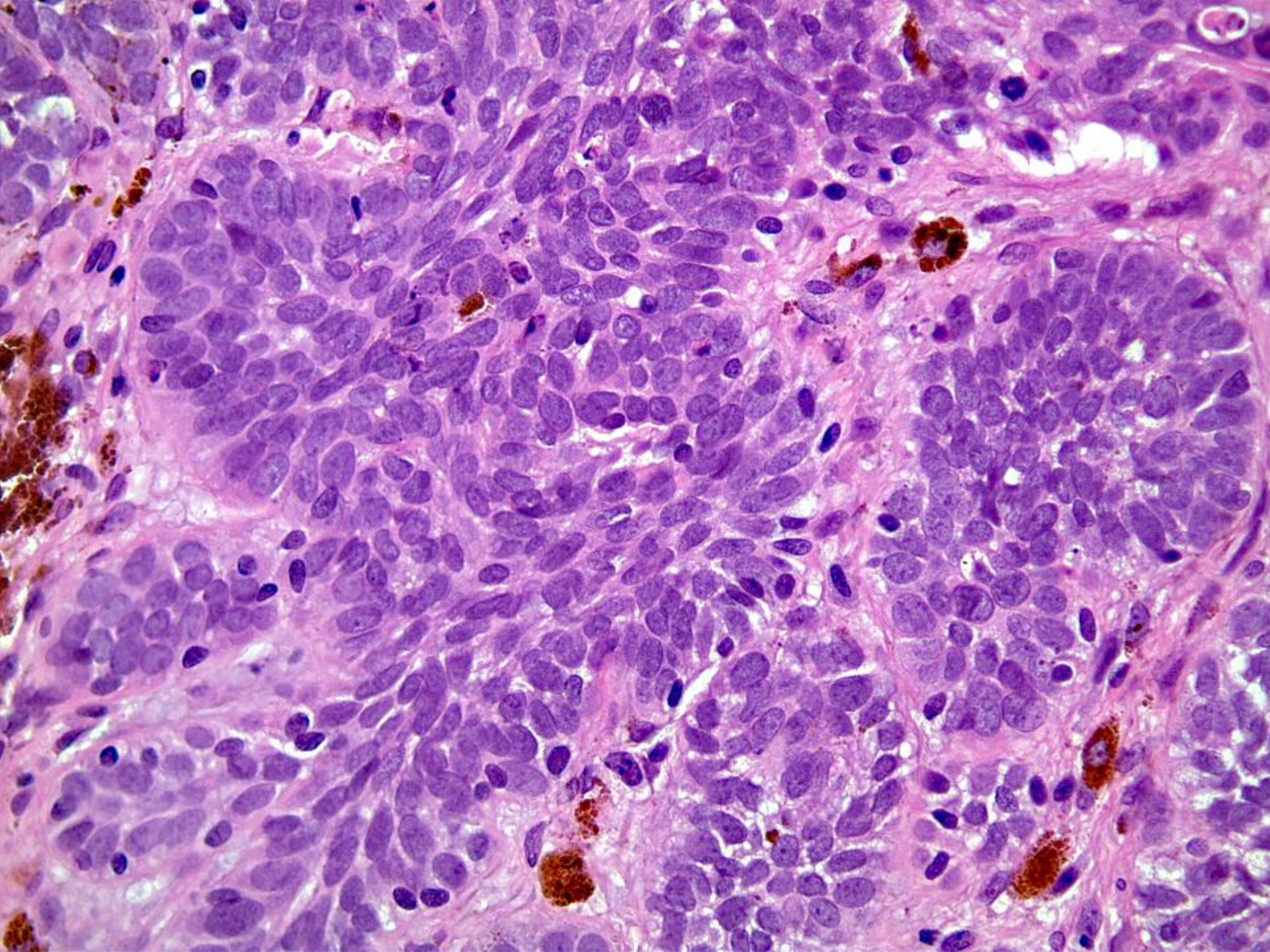
- **76 year old gentleman with periauricular pigmented lesion growing for the last few months.**
- **Clinical impression:
Melanoma?**

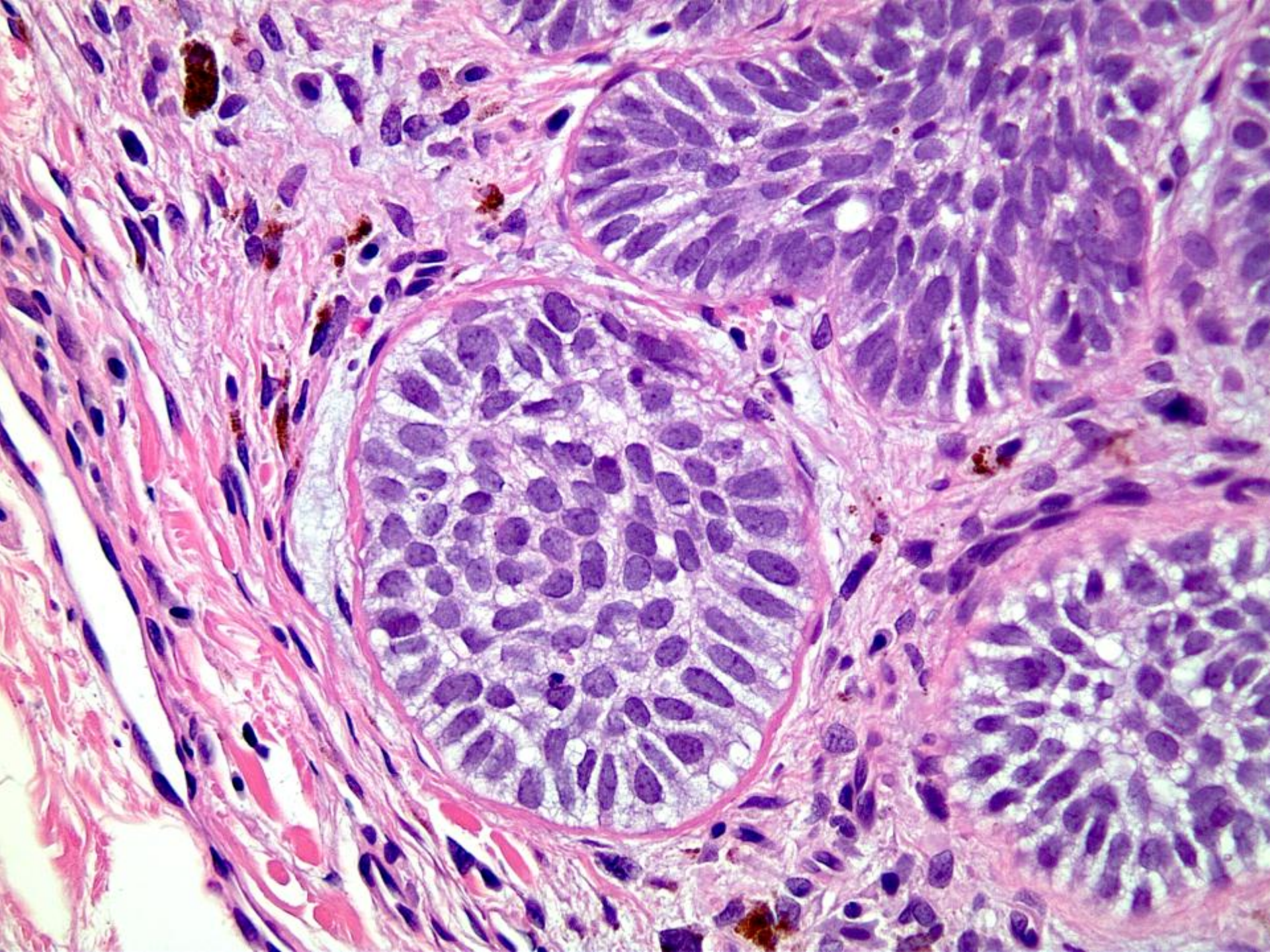












Your Diagnosis?

- A. Pigmented Basal Cell Carcinoma.**
- B. Invasive melanoma.**
- C. Pigmented trichoblastoma.**
- D. Pigmented Squamous Cell Carcinoma.**
- E. Pigmented cellular Neurothekeoma.**

Your Diagnosis?

- A. Pigmented Basal Cell Carcinoma.**
- B. Invasive melanoma.**
- C. Pigmented trichoblastoma.**
- D. Pigmented Squamous Cell Carcinoma.**
- E. Pigmented cellular Neurothekeoma.**

Pigmented BCC

- Same demographics as usual BCC.
- Frequency different between races (1-10%).
- Microscopic pigmentation >clinically PBCC.
- Most common type effected: Nodular BCC.
- Resected with adequate margins.
- Melanocytes present in all PBCC.
- Melanization: Stromal and tumor cells.

Non-melanocytic Pigmented Skin Neoplasms

- **Pigmented SCC: 0.01%.**
- **Pigmented reticulated SK: 40%.**
- **Pigmented DFSP 5%-10%.**
- **Pigmented trichoblastoma.**
- **5-20% of cutaneous Melanomas are amelanotic.**

